

Functional and Cosmetic Outcome of Bipolar Release in Congenital Muscular Torticollis among Children: An Observational Study from the Tertiary Care Center of KPK

WASEEM KHAN¹, ASGHAR ALI KHAN¹, NOOR-U-RAHMAN¹, MUHAMMAD SALAR KHAN¹, MUHAMMAD JAWAD SALEEM², MUHAMMAD ILYAS³

¹MBBS, (PGR-FCPS Orthopaedic), Orthopedic B Ward, Hayatabad Medical Complex, Peshawar

²MBBS, FCPS (Orthopaedic), Medical Officer, Type D Hospital Paroa, District DI Khan

³MBBS PGR-MS Orthopaedic, Jinnah Postgraduate Medical Center, Karachi

Correspondence to: Waseem Khan, Email: drwaseemkhan@gmail.com

ABSTRACT

Background and Aim: Congenital muscular torticollis (CMT) is a common musculoskeletal condition in children which may cause functional and cosmetic problems if not treated at an early stage. This study was undertaken to assess the functional and cosmetic results of bipolar release of the sternocleidomastoid muscle in children presenting with CMT at tertiary care center of KPK.

Methodology: This prospective observational study was done at Hayatabad Medical Complex Peshawar from Jan 2022 to July 2023 on 30 children of age between 4-16 years who presented with CMT. All patients underwent bipolar release after conservative management failure. Functional outcomes were evaluated with cervical rotation and lateral flexion and cosmetic outcomes were head tilt correction, facial asymmetry, and scar formation. Preoperative and postoperative values were compared with paired t-test and stratification analysis was done according to age, gender, and side of involvement.

Results: Study was male dominant with 53.3% of male children and the mean age of overall population was 10.23 ± 3.53 years. We noted an excellent and good response in 46.7% and 33.3% of patients respectively. Only 6.7% patient showed poor outcome. A significant improvement was seen in cervical rotation $44.88^\circ \pm 6.37$ to $75.14^\circ \pm 8.13$, and lateral flexion from $24.49^\circ \pm 4.26$ to $50.66^\circ \pm 7.02$ (p-value < 0.001). Complete correction of head tilt was observed in 63.3%, and facial asymmetry improved in 70% of cases. Upon stratification analysis, no significant association (p-value > 0.05) was found among confounders for any outcome.

Conclusion: Bipolar release is safe and effective treatment for congenital muscular torticollis in children that offers great functional improvement and good cosmetically acceptable results regardless of patient demographics.

Keywords: Congenital muscular torticollis, children, sternocleidomastoid muscle, facial asymmetry, head tilt, flexion, rotation

INTRODUCTION

Congenital muscular torticollis (CMT) is an uncommon congenital musculoskeletal condition marked by unilateral contraction of the sternocleidomastoid muscle (SCM). It manifests in neonates and constitutes 0.3% to 16% of congenital anomalies referred to the orthopaedic department^{1,2}. Among the possible underlying mechanisms that could be responsible for CMT include intrauterine malpositioning of the neck, venous occlusion, compartmental syndrome and traumatic delivery that occurs after childbirth. This misalignment of the cervical spine can result in ischaemia, which can then lead to fibrosis in the sternocleidomastoid muscle^{3,4}. Irrespective of the cause, the resulting contracture leads to progressive deformity if untreated. Occasionally, the disease may cure spontaneously; nevertheless, stretching exercises and physiotherapy treatments might be essential in restoring functionality and enhancing motor development in children⁵. However, delayed diagnosis or poor treatment can result in persistent deformity such as craniofacial asymmetry, cervical spine imbalance and functional limitation⁶. Around 10-15% of patients don't respond to conservative therapy or present at a later age especially in the developing world where access to healthcare and awareness are limited⁷. Surgical intervention becomes an imperative for correction of this deformity and normal restoration of function in such cases.

Several surgical procedures have been reported to be used in management of CMT such as unipolar release⁸, bipolar release⁸, Z-lengthening⁹, and endoscopic surgery procedures⁹. Out of this, the most widely acknowledged method of long standing and neglected cases release is the bipolar release in that it offers the release both proximal and distal of the SCM attachments thereby providing the best opportunity to correct deformity^{9,10}. Though some studies have exhibited good performances following the release of bipolar, the majority of information is through the developed world. The developing world such as Pakistan suffers a

relative lack of literature since there are general problems in presentation and disparity between outcome because of socioeconomic and healthcare related factors. Hence, the current research was conducted to determine functional and cosmetic outcomes of bipolar release in children aged 4-16 years with congenital muscular torticollis in a tertiary care center at Khyber Pakhtunkhwa, Pakistan.

MATERIALS AND METHODS

This was a prospective, observational study, which was conducted in the Orthopedic Department of Hayatabad Medical Complex, Peshawar, from January 2022 to July 2023. Study was conducted after getting permission from ethical review committee of the hospital. Patients were enrolled using non-probability consecutive sampling technique and after signing a written informed consent by the parents or caregivers of the children. We enrolled 30 children of both gender, having age between 4 and 16 years who diagnosed with congenital muscular torticollis and failed to respond conservative physiotherapy for minimum of six months. Patients with secondary causes of torticollis such as neurological, ocular, or cervical spine abnormalities, previous surgery to the neck, and syndromic conditions were excluded.

A detailed clinical evaluation, including assessment of head tilt, neck rotation, lateral flexion and facial asymmetry was performed for all the patients following taking a detailed clinical history. Radiographs of the cervical spine were taken before the intervention, to rule out underlying structural abnormalities. All procedures were done under general anaesthesia. Bipolar release of sternocleidomastoid muscle was performed in two incisions: distal incision over the clavicular and sternal heads and proximal over the insertion of mastoid. Both heads of the SCM were released as well as any fibrotic bands. Care was taken to identify and protect the spinal accessory nerve. Adequate correction was confirmed intra-operatively by full passive range of motion. Postoperatively, all patients were placed in a cervical collar for 4 weeks. Physiotherapy was begun soon and consisted of active and passive stretching exercises, strengthening and range of motion

Received on 15-08-2023

Accepted on 27-10-2023

exercises. Patients were followed up at 2 weeks, 6 weeks, 3 months, 6 months, and 9 months after surgery. Functional and cosmetic evaluation was carried out after 9-12 months post-operatively. Outcome measures included functional improvement in neck movement and cosmetic improvement in head tilt, facial asymmetry and scar formation and lateral banding. Final results were graded according to Lee scoring system. Statistical analysis was conducted by using the statistical program (SPSS version 25) and preoperative and postoperative values were compared using paired t-tests ($p < 0.05$ considered statistically significant).

RESULTS

Analysis of gathered data of 30 patients reflected that the mean age of the participants was 10.23 ± 3.53 years, ranging from 4 to 16 years. Study was slightly male dominant with 16 males (53.3%) and left-sided involvement was more common that was observed in 19 patients (63.3%). Patients were further categorized in different age groups which are graphically illustrated along with other categorical variables in figure 1, figure 2 and figure 3.

We found a decent proportion of patients with excellent (46.7%) and good (33.3%) outcome on the basis of Lee scoring system. Only 6.7% patient showed poor outcome (table 1). Similarly, more than half of the patients (63.3%) showed complete head tilt correction, 70% showed improved in facial asymmetry and only one patient had hypertrophic scar (table 3). Paired test analysis reflected a statistically significant improvement in both cervical rotation and lateral flexion which is tabulated in table 3.

Functional outcome was compared between gender, side involved and age group. Although a higher percentage of females got an excellent outcome compared with males (57.1% vs 37.5%), the difference was not statistically significant ($p = 0.367$). Likewise, no significant association was found regarding functional outcome and side involved ($p = 0.292$) or age group ($p = 0.495$). These findings suggested that postoperative functional results were similar in demographic and clinical subgroups (table 4).

Stratified analysis of cosmetic outcome did not show significant association of gender and side involved and age group with head tilt correction, facial asymmetry improvement, or scar outcome. Complete correction of head tilt was accomplished in 64.3% of the females and 62.5% of the males ($p = 0.919$). Improvement in facial asymmetry was also found in 78.6% of females and 62.5% of males, but again this difference was not significant ($p = 0.338$). Scar related complications were rare with only one hypertrophic scar registered, and no group difference observed to reach statistical significance (table 5).

When stratified by age group and gender, there were significant improvements in both cervical rotation and lateral flexion in all age groups and for both genders. Among children < 10 years, lateral flexion was increased from 25.71 ± 5.31 to 51.91 ± 8.19 and cervical rotation from 45.52 ± 4.26 to 75.63 ± 5.57 ($p < 0.001$). Similarly, in the children age group in the age group ≥ 10 years, both parameters improved significantly ($p < 0.001$). Comparable statistically significant improvements were also found for both males and females, indicating that bipolar release was effective regardless of age category or gender (table 6).

Table 1: Functional Outcome (Lee Scoring System)

Outcome	Frequency (n)	Percentage (%)
Excellent	14	46.7
Good	10	33.3
Fair	4	13.3
Poor	2	6.7
Total	30	100

Table 2: Cosmetic Outcomes

Parameter	Category	Frequency (n)	Percentage (%)
Head Tilt Correction	Complete	19	63.3
	Mild residual	11	36.7
Facial Asymmetry	Improved	21	70.0
	Residual	9	30.0
Scar	None	29	96.7
	Hypertrophic	1	3.3

Table 3: Angle Improvement (Pre vs Post Operative)

Parameter	Preoperative Mean \pm SD	Postoperative Mean \pm SD	Mean Difference	p-value
Cervical Rotation	44.88 ± 6.37	75.14 ± 8.13	30.26	< 0.001
Lateral Flexion	24.49 ± 4.26	50.66 ± 7.02	26.17	< 0.001

Table 4. Stratification of functional outcome according to gender, side involved, and age group

Variable	Category	Excellent n (%)	Good n (%)	Fair n (%)	Poor n (%)	Total (n)	p-value
Gender	Female	8 (57.1)	5 (35.7)	1 (7.1)	0 (0.0)	14	0.367
	Male	6 (37.5)	5 (31.3)	3 (18.8)	2 (12.5)	16	
Age group	< 10 years	8 (61.5)	3 (23.1)	1 (7.7)	1 (7.7)	13	0.495
	≥ 10 years	6 (35.3)	7 (41.2)	3 (17.6)	1 (5.9)	17	

Table 5. Stratification of cosmetic outcome according to gender, side involved, and age group

Head tilt correction						
Variable	Category	Complete correction n (%)	Mild residual n (%)	Total (n)	Chi-square / Fisher's exact	p-value
Gender	Female	9 (64.3)	5 (35.7)	14	0.010	0.919
	Male	10 (62.5)	6 (37.5)	16		
Age group	< 10 years	9 (69.2)	4 (30.8)	13	0.344	0.558
	≥ 10 years	10 (58.8)	7 (41.2)	17		
Facial asymmetry						
Variable	Category	Improved n (%)	Residual n (%)	Total (n)	Chi-square / Fisher's exact	p-value
Gender	Female	11 (78.6)	3 (21.4)	14	0.918	0.338
	Male	10 (62.5)	6 (37.5)	16		
Age group	< 10 years	8 (61.5)	5 (38.5)	13	0.782	0.376
	≥ 10 years	13 (76.5)	4 (23.5)	17		
Scar outcome						
Variable	Category	None n (%)	Hypertrophic n (%)	Total (n)	Chi-square / Fisher's exact	p-value
Gender	Female	14 (100.0)	0 (0.0)	14	0.905	0.341
	Male	15 (93.8)	1 (6.3)	16		
Age group	< 10 years	13 (100.0)	0 (0.0)	13	0.791	0.374
	≥ 10 years	16 (94.1)	1 (5.9)	17		

Table 6. Stratified comparison of preoperative and postoperative angle measurements according to age group and gender

Stratification variable	Subgroup	Preoperative lateral flexion Mean ± SD	Postoperative lateral flexion Mean ± SD	p-value
Age group	< 10 years (n = 13)	25.71 ± 5.31	51.91 ± 8.19	<0.001
	≥ 10 years (n = 17)	23.56 ± 3.11	49.71 ± 6.07	<0.001
Gender	Male (n = 16)	26.04 ± 4.25	52.93 ± 7.78	<0.001
	Female (n = 14)	22.73 ± 3.66	48.07 ± 5.14	<0.001
Stratification variable	Subgroup	Preoperative cervical rotation Mean ± SD	Postoperative cervical rotation Mean ± SD	p-value
Age group	< 10 years (n = 13)	45.52 ± 4.26	75.63 ± 5.57	<0.001
	≥ 10 years (n = 17)	44.39 ± 7.71	74.77 ± 9.81	<0.001
Gender	Male (n = 16)	45.73 ± 4.22	75.78 ± 7.36	<0.001
	Female (n = 14)	43.91 ± 8.26	74.42 ± 9.17	<0.001

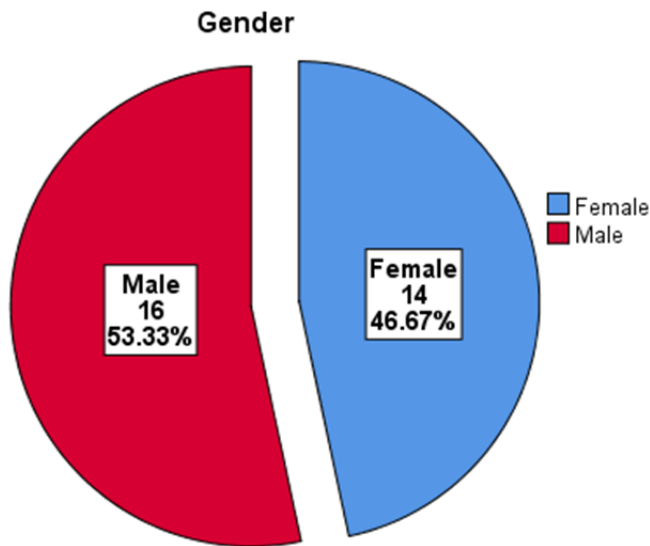


Figure 1: Distribution of study population on the basis of gender

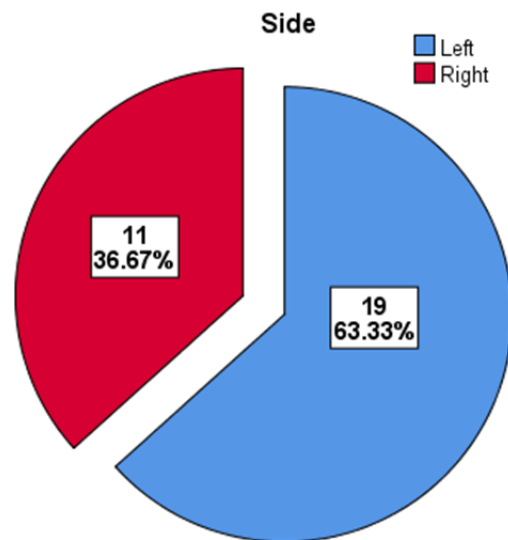


Figure 3: Categorization of patients on the basis of side of neck involvement

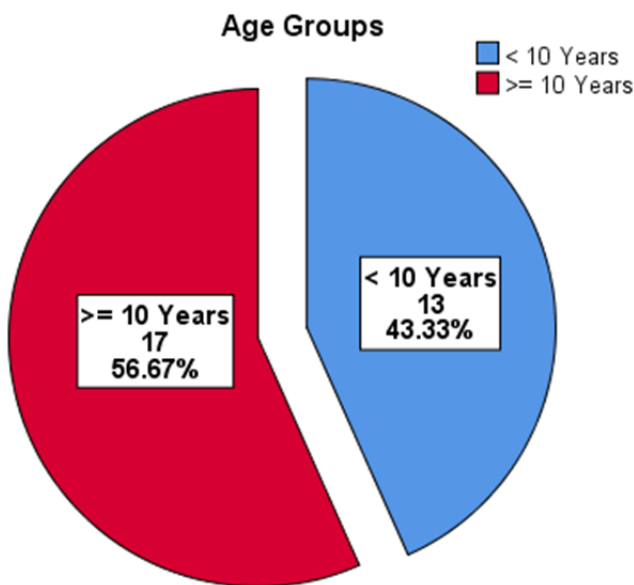


Figure 2: Classification of patients in different age groups

DISCUSSION

Functional and cosmetic results of bipolar release of the sternocleidomastoid muscle in children with congenital muscular torticollis were evaluated in the present study. The results showed significant improvement in both cervical rotation and lateral flexion after surgical intervention with acceptable cosmetic results and low rate of complications. A significant result of this study was that there was a statistically significant improvement in functional parameters post-operatively. There was an improvement in mean cervical rotation of about 30° and lateral flexion of more than 26°, both were highly significant (p < 0.001). These results are similar to those from other studies showing significant increases in the mobility of the neck after bipolar release^{11,12}. Kim et al. reported some similar improvements in the range of motion about the cervical spine, the importance of which he emphasized was that complete release of both proximal and distal attachments will allow for effective correction of muscular contracture¹³. Likewise, Aydemir et al. have noted significant functional improvements in neglected cases to support the effectiveness of bipolar release, even with delayed presentations¹⁴. In present study, excellent to good results have been achieved in (80 percent) of patients and these results are comparable to success rate ranging between 75 to 95 percent reported in earlier studies¹⁴⁻¹⁶. Ahmad et al. reported good results in 85% of their cohort and Bhuyan showed good success rates after bipolar release^{15,16}. The minor differences in the results can be explained by the age of presentation and severity of the deformity. In developing parts of the world like Pakistan, a delay in presentation is common which may affect the extent of correction which is feasible. Cosmetic results in this study

were also satisfactory with complete correction of head tilt in 63.3% of patients and improvement in facial asymmetry was noted in 70%. However, residual asymmetry was consistently observed in a subgroup of older children. This finding is in line with previous literature that suggests that while muscular imbalance is corrected by surgical intervention, craniofacial remodeling potential diminishes with increasing age^{17,18}. Hung et al. highlighted that optimum cosmetic results are obtained if intervention is carried out early, although meaningful improvement can be obtained in an older child¹⁹. An important aspect of this study is the stratification analysis which has shown no statistically significant association between functional or cosmetic outcome and demographic variables such as age, gender or side of involvement. These results indicate that bipolar release gives consistent results in different subgroups of patients. Similar findings have been reported in prior studies, in which surgical outcomes of both genders and sides of involvement were independent^{15,20}. The comparison between age groups (<10 years and ≥10 years) showed that both groups had significant improvement in functional parameters without statistically significant difference between them. This finding is of clinical significance as it supports the efficacy of surgical intervention even at older age. Undoubtedly there is an edge for early surgery over delayed but several recent studies have shown that even delayed intervention can provide satisfactory outcomes^{14,21}. This is especially relevant in resource-limited settings where late presentation is quite often encountered. The low level of complications noted in this study adds to the safety of bipolar release. Only one case of hypertrophic scarring was noted and no major complications like neurovascular injury and recurrence were noted. These results are in accord with previous studies that have reported low rates of complications with this procedure if performed with meticulous surgical technique^{14,16,22}. Postoperative physiotherapy is extremely important for maintenance of correction from the surgical procedure and preventing recurrence. In the present study, early physiotherapy initiation was related to good results. Various past studies advocacy the need for structured post-operative rehabilitation protocols for optimization of surgical results^{22,23}. Despite the strengths, there are certain limitations in this study. The relatively small sample size and single center design may be a limitation of the generalizability of the findings. Furthermore, long-term follow-up for more than one year was not available which is important for assessing recurrence and long-term cosmetic outcomes. Few more multicenter studies with different ethnic groups with larger sample size and longer follow-up period is recommended to validate these findings. Overall, this study represents valuable regional data, and helps to strengthen the use of bipolar release as a good and reliable surgical option in congenital muscular torticollis, especially in places where the delay in presentation is common.

CONCLUSION

Our study reported a decent proportion of excellent and good functional outcomes among patients belonging to our local population suffering with CMT. Bipolar release of sternocleidomastoid muscle is associated with significant improvement in cervical range of motion and satisfactory cosmetic correction in children with congenital muscular torticollis. The procedure is safe and has minimal complications and no recurrence has been observed. Functional and cosmetic results were similar for the several age and gender groups, and sides of involvement. These findings support the equality of the surgical intervention even in delayed presentations; however, the early postoperative rehabilitation should be encouraged for the better outcome.

Acknowledgements: The authors are grateful to the senior colleagues for their tireless support and kind guidance. They are also thankful to the supporting staff of Orthopedic Department of HMC, Peshawar and appreciate their dedication and restless efforts.

Conflicts of Interest: The authors declare no conflicts of interest.

REFERENCES

- Nilesh K, Mukherji S. Congenital muscular torticollis. *Ann Maxillofac Surg*. 2013 Jul;3(2):198-200. doi: 10.4103/2231-0746.119222.
- Minghelli B, Vitorino NGD. Incidence of Congenital Muscular Torticollis in Babies from Southern Portugal: Types, Age of Diagnosis and Risk Factors. *Int J Environ Res Public Health*. 2022 Jul 26;19(15):9133. doi: 10.3390/ijerph19159133.
- Phillips L, Walsh K, Burton J. Congenital muscular torticollis: Diagnosis, management, and prognosis in the pediatric population. *Curr Probl Pediatr Adolesc Health Care*. 2025 Nov;55(11):101877. doi: 10.1016/j.cppeds.2025.101877.
- Kim SM, Cha B, Jeong KS, Ha NH, Park MC. Clinical factors in patients with congenital muscular torticollis treated with surgical resection. *Arch Plast Surg*. 2019 Sep;46(5):414-420. doi: 10.5999/aps.2019.0206.
- Desai S, Sharath HV. Effect of Pediatric Physical Therapy Interventions on Congenital Muscular Torticollis: A Systematic Review. *Cureus*. 2024 Sep 17;16(9):e69572. doi: 10.7759/cureus.69572.
- Chen C, Ko JY. Surgical treatment of muscular torticollis for patients above 6 years of age. *Arch orthopaed Trauma Surg*. 2000;120:149-51. doi: 10.1007/s0040200050032.
- Cheng JCY, Tang SP, Chen TMK, Wong MWN, Wong E. The clinical presentation and outcome of treatment of congenital muscular torticollis in infants - A study of 1,086 cases. *J Pediatr Surg*. 2000;35:1091-6. doi: 10.1053/jpsu.2000.7833.
- Shim JS, Jang HP. Operative treatment of congenital torticollis. *J Bone Joint Surg Br*. 2008 Jul;90(7):934-9. doi: 10.1302/0301-620X.90B7.20339.
- Sudesh P, Bali K, Mootha AK, Dhillon MS. Results of bipolar release in the treatment of congenital muscular torticollis in patients older than 10 years of age. *J Child Orthop*. 2010 Jun;4(3):227-32. doi: 10.1007/s11832-010-0254-x.
- Seyhan N, Jasharilari L, Keskin M, Savacı N. Efficacy of bipolar release in neglected congenital muscular torticollis patients. *Musculoskelet Surg*. 2012 Jun;96(1):55-7. doi: 10.1007/s12306-011-0170-3.
- Petricic I, Brdar R, Cirovic D, Nikolic D, Lukac M, Janic D, et al. Congenital muscular torticollis in children: distribution, treatment duration and outcome. *Eur J Phys Rehabil Med*. 2010 Jun;46(2):153-7.
- Kaplan SL, Coulter C, Fetters L. Physical therapy management of congenital muscular torticollis: an evidence-based clinical practice guideline: from the Section on Pediatrics of the American Physical Therapy Association. *Pediatr Phys Ther*. 2013 Winter;25(4):348-94. doi: 10.1097/PEP.0b013e3182a778d2.
- Kim HJ, Ahn HS, Park E, Yim SY. Effectiveness of Surgical Release in Patients With Neglected Congenital Muscular Torticollis According to Age at the Time of Surgery. *Ann Rehabil Med*. 2016;40:34-42. <http://dx.doi.org/10.5535/arm.2016.40.1.34>
- Aydemir AN, Ergün S, Şirazi S, Okay E, Bezer M. Bipolar release technique in neglected congenital muscular torticollis. *Acta Orthop Belg*. 2020;86(Suppl 2):1-5. Available from: https://www.actaorthopaedica.be/assets/2958/01-Aydemir_et_al.pdf
- Ahmad I, Kamran K, Iqbal MJ, Khan MA, Hakim A, Ullah S. Outcome of bipolar release for congenital muscular torticollis. *J Med Sci*. 2015;23(3):146-9. Available from: <https://jmedsci.com/Jmedsci/article/view/192>
- Bhuyan BK. Outcome of bipolar release of sternocleidomastoid muscle in neglected congenital muscular torticollis. *Med J DY Patil Univ*. 2014;7(5):584-8. doi: 10.4103/0975-2870.140407
- Seo SJ, Yim SY, Lee IJ, Han DH, Kim CS, Lim H, et al. Is craniofacial asymmetry progressive in untreated congenital muscular torticollis? *Plast Reconstr Surg*. 2013 Aug;132(2):407-413. doi: 10.1097/PRS.0b013e3182959e30.
- Lee DY, Song BW, Cho TJ, Choi IH, Chung CY, Yoo WJ. Craniofacial asymmetry in congenital muscular torticollis patients: a study using cephalometry. *J Korean Orthop Assoc*. 2007;42(1):24-31. doi:10.4055/jkoa.2007.42.1.24
- Hung N, Anh L. A Comparison of Outcome of Age at Time Surgery between Younger and Older than 8 Years Old in Children with Congenital Muscular Torticollis. *Open Acc Lib J*. 2017;4:1-12. doi: 10.4236/oalib.1104105.
- Lim KS, Shim JS, Lee YS. Is sternocleidomastoid muscle release effective in adults with neglected congenital muscular torticollis? *Clin Orthop Relat Res*. 2014 Apr;472(4):1271-8. doi: 10.1007/s11999-013-3388-6.
- Madegowda A, Agarwal A, Jandial G. Bipolar release in congenital muscular torticollis: does attachment matter? *J Jpn Pediatr Orthop Assoc*. 2020;29(1):116-22. Available from: https://www.researchgate.net/publication/357269752_Bipolar_release_in_congenital_muscular_torticollis_does_attachments_of_sternocleidomastoid_matter
- Funao H, Isogai N, Otomo N, Yamanoouchi K, Mizukoshi R, Fujita N, et al. Clinical Results after Release of Sternocleidomastoid Muscle Surgery for Neglected Congenital Muscular Torticollis-Unipolar vs. Bipolar Release Surgery. *J Clin Med*. 2023;13(1):131.
- Kaplan SL, Coulter C, Sargent B. Physical Therapy Management of Congenital Muscular Torticollis: A 2018 Evidence-Based Clinical Practice Guideline From the APTA Academy of Pediatric Physical Therapy. *Pediatr Phys Ther*. 2018 Oct;30(4):240-290. doi: 10.1097/PEP.0000000000000544.

This article may be cited as: Khan W., Khan A. A., Rahman N.U, Khan M. S., Saleem M. J., Ilyas M., Functional and Cosmetic Outcome of Bipolar Release in Congenital Muscular Torticollis among Children: An Observational Study from the Tertiary Care Center of KPK. *Pak J Med Health Sci*, 2023; 17(10): 427-431.