

## Variations in Anatomical Position of Vermiform Appendix in Pakistani Population

HINA JABEEN<sup>1</sup>, ROMAIZA<sup>2</sup>, MARIA MALIK<sup>3</sup>, MUHAMMAD KAMRAN<sup>4</sup>, HIRA AHMED<sup>5</sup>, SHAZIA FAHMI<sup>6</sup>

<sup>1,4</sup>Lecturer Anatomy Department Dow University of Health Sciences, Karachi

<sup>2,3</sup>Medical Officer, Allama Iqbal Memorial Teaching Hospital Sialkot

<sup>5,6</sup>Assistant Professor Anatomy, Karachi Medical and Dental College, Karachi

Correspondence to Dr. Hina Jabeen, Email: [Hinajabeen2009@yahoo.com](mailto:Hinajabeen2009@yahoo.com)

### ABSTRACT

**Aim:** To study diversity in position and length of vermiform appendix in human body to manage the patients properly presenting with acute appendicitis.

**Methods:** This is a cross sectional study conducted on 240 bodies. Study was conducted in anatomy department of Dow University of health sciences. Study was completed in one year duration from January 2021 to December 2021. Site and length of vermiform appendix was observed in dead bodies undergoing autopsy. Sample size was calculated using WHO sample size calculator. Consecutive sampling technique was used for sample selection. Data was analyzed using SPSS software (version-20) and chi-square test was applied on the collected data.

**Result:** Total 240 bodies were studied for the anatomical position of appendix, including 156(65%) males and 84(35%) females. Mean age was  $34.6 \pm 5.2$  years with the range of ages as 8-65 years. Mean length of the appendix was  $92.6 \pm 2.5$  mm in men and  $85.3 \pm 4.7$  mm in women. Pelvic position was the most common position of appendix found in 122(50.8%) bodies.

**Conclusion:** High incidence of anterior position of appendix in Pakistani population describe that diagnosis of acute appendicitis can be made sooner and easier in our population with less complications like missed diagnosis, gangrene and perforation as compared to other populations.

**Key words:** Vermiform appendix, Pakistani population, Appendicitis, Anatomical position

### INTRODUCTION

Vermiform appendix is a part of our gastrointestinal tract that is present in right iliac fossa. It is a vestigial organ which arises from the posterior wall of cecum 2-3cm below the ileocecal valve during embryological life. Previous studies have reported that in majority of people appendix is present anteriorly and hanging freely in pelvic brim. Although it is a constant structure in human body but occasionally it shows some variations like suppression and duplication. Its average length is 9cm ranging from 2-20cm.

Appendix base is connected to cecum but its its head can be found in various positions. There are six positions of appendix given as pelvic, retrocecal, subcecal, retroileal, preileal and ectopic. Acute appendicitis is a very common disease in young patients. It can also occur in any age. Previous studies have shown that age, race, gender, geographical area and diet can affect the position of appendix. Mortality rate of non-perforated acute appendicitis is 0.1% and that of perforated appendicitis is 3% in young and can be as high as 15% in older patients. A study in the past have reported that pelvic position of appendix is very common found in 57.7% while paracecal was the least common position seen in just 3.07% people. Diagnosis of acute appendicitis is mainly made by clinical examination and there is no definite investigation to diagnose this condition. Knowledge of common position of appendix helps us a lot to diagnose the acute appendicitis.

Different positions of appendix may mislead the clinician towards wrong diagnosis or delayed diagnosis leading to complications and increased morbidity and mortality of the patients. Complications of acute appendicitis include perforation and abscess formation causing peritonitis. However knowledge of accurate position of the appendix can help us to diagnose the disease easily and improve its prognosis.

This study was conducted to determine various anatomical locations of the appendix and its length and their relationship with gender and age.

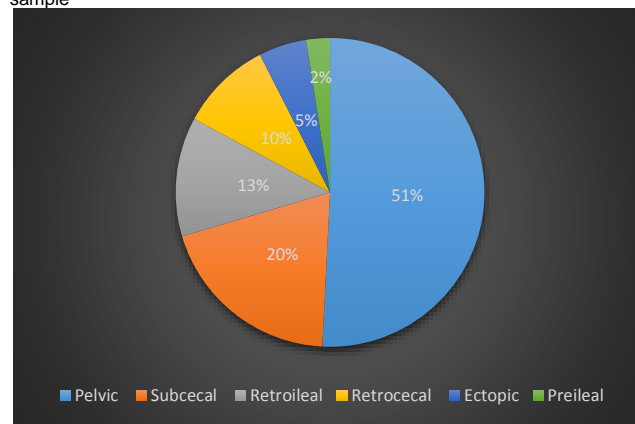
### MATERIALS AND METHODS

This is a cross sectional study. After approval from Ethical Review Board, the study was conducted on 240 cadavers referred to forensic department undergoing autopsy to determine the cause of

death. Study was conducted in anatomy department of Dow University of health sciences. Study was started on January 2021 and completed after 12 months on December 2021. Site and length of vermiform appendix was observed in dead bodies undergoing autopsy. Sample size was calculated using WHO sample size calculator. Consecutive sampling technique was used for sample selection. Study sample included male and female bodies irrespective of age. Our inclusion criteria was Pakistani population and necessary to perform autopsy. Cadavers of unknown nationality, severe burns, decomposed or disintegrated cadavers, those with congenital anomalies, peritonitis, old or new abdominal surgery, intestinal distension or having any condition which may change anatomical position of the appendix were not included in this study. No additional incisions were made in the skin of cadavers for study purpose. Gender and age were determined using identity documents. Data was analyzed using SPSS version-20 and chi-square test was applied on the collected data. Ethical approval was taken from the institutional review board.

### RESULTS

Fig. 1: Frequency of various anatomical positions of appendix in study sample



This study included 240 cadavers including 156(65%) male and 84(35%) female bodies. Mean age was  $34.6 \pm 5.2$  years with the range of ages as 8-65 years. Range of appendix length was 20-

Received on 05-01-2022

Accepted on 05-05-2022

165mm with average length of  $92.6 \pm 2.5$ mm in male and  $85.3 \pm 4.7$  mm in female cadavers (Table-I). Mean age was  $34.6 \pm 5.2$  years with the range of ages as 8-65 years. Mostly cadavers were between 20-40 years of age with the frequency of 48.3%. Commonly found length of appendix was between 80-119mm in 131(54.5%) cadavers. Most commonly observed appendix position

was pelvic position in 122(50.8%) cadavers followed by subcecal in 47(19.6%), retroileal 30(12.5%), retrocecal in 23(9.6%) and ectopic in 12(5%) while preileal position was the least common found in 06(2.5%) cadavers (Figure-I).

Table-I: Association between age and length of appendix in study group

Age (years)	Length of appendix (mm)				Total	p-value
	<40	40-79	80-119	>119		
<10	0	3(1.2%)	02 (0.8%)	2(0.80%)	07(2.9%)	<0.001
11-19	2(0.8%)	8(3.3%)	03 (1.2%)	1(0.42%)	14 (5.8%)	<0.001
20-39	1(0.4%)	32(13.3%)	70 (29.2%)	13(5.4%)	116(48.3%)	<0.001
40-54	02 (0.8%)	14 (5.8%)	26 (10.8%)	6 (2.5%)	48 (20%)	<0.001
>55	03 (1.2%)	17 (7.1%)	30 (12.5%)	05 (2.1%)	55 (22.9%)	<0.001
Total	08 (3.3%)	74 (30.8%)	131(54.5%)	27 (11.2%)	240 (100%)	<0.001

## DISCUSSION

This study reported that pelvic position is the most common position of appendix found in 50.8% bodies while preileal position is least common found in 2.5% bodies. These findings are comparable to a previous studies by Salim et al, Chauhan et al and Kerroum et al<sup>11-13</sup>.

While few other studies by Rait et al and Yu D et al reported that retrocecal and pelvic positions are most common positions.<sup>14,15</sup> different results by different studies suggest that there is influence of genetic variation, geographical distribution and race ethnicity on the position of appendix in various populations of the world. A study conducted in Canada by Hirpara et al and another study in Europe by Kachlik et al on the variations of anatomy of appendix reported similar findings as our study reported<sup>16,17</sup>.

Fenwick et al examined appendix position using ultrasonography and found it in pelvic position in most of their study cases<sup>18</sup>. Pelvic position of appendix is most common according to all above mentioned studies. Its variable positions can affect diagnosis of acute appendicitis that is a common cause of acute abdomen. Appendix position can also be stated with the reference of cecum like anterior (pelvic, preileal and retroileal) or posterior position (retrocecal and paracecal). In our study anterior position of appendix was seen in 158(65.8%) while posterior position was found in 82(34.2%) bodies. Hence due to common anterior position of appendix early diagnosis of acute appendicitis is easy leading to short duration of surgery and short hospital stay. It reduces complications rate and hence morbidity and mortality rate as well. Pelvic position was found common in both male and female genders accounting 72(44.9%) in male and 50(59.5%) in female bodies. These results show that pelvic position is more common in female population as compared to males. Studies have also stated that vermiform appendix is a mobile organ and its position changes in various situations<sup>19</sup>.

Most of the bodies shown appendix length between 80-119mm. These findings are comparable to a previous study conducted by Lahfaoui et al which also found longer appendix length among male population.<sup>20</sup> An African study conducted by Zhou C et al stated that during early growth period in infancy up to 3 years of age appendix achieves its length of adult proportion and does not continue to increase in length.<sup>21</sup> Similarly in our study there was no significant change in length with advancing age. Zhou C et al reported that appendix length doesn't change with age and remains almost constant after early childhood<sup>22</sup>.

## CONCLUSION

In this study we found high incidence of anterior position of appendix in our Pakistani population. Due to common anterior position diagnosis of acute appendicitis can be made sooner and easier in our population with less complications. We found no significant change in appendix length in older patients as compared to youngsters.

Conflict of interest: Nil

## REFERENCES

- Vieira ED, Bonato LM, Silva GG, Gurgel JL. Congenital abnormalities and anatomical variations of the vermiform appendix and mesoappendix. *J Coloproctology (Rio de Janeiro)*. 2019 Sep 30;39:279-87. <https://doi.org/10.1016/j.jcol.2019.04.003>
- Sumi SA, Sultana SZ, Mannan S, Paul UK, Khan MS, Faruque MO et al. Variations in the Position of Vermiform Appendix in Bangladeshi People. *Mymensingh Medical Journal: MMJ*. 2019 Jan 1;28(1):54-9.
- Rousan LA, Jibril MI. Retro-psoas muscle vermiform appendix: an unusual location. *J Surg Radiol Anat*. 2020 Oct;42(10):1259-61. <https://doi.org/10.1007/s00276-020-02477-9>
- Zacharzewska-Gondek A, Szczurowska A, Guziński M, Sasiadek M, Bładowska J. A pictorial essay of the most atypical variants of the vermiform appendix position in computed tomography with their possible clinical implications. *Pol J radiol*. 2019;84:e1. <https://dx.doi.org/10.5114/2Fpjr.2018.81158>
- Jagdish P, Ashoka RK. Morphometry of Vermiform Appendix: A Human Cadaveric study. *J Dent Med Sci*. 2018;17(8):72-6.
- Rahman MA, Azim MA, Karim F. Anatomical Positions of Vermiform Appendix in Bangladeshi People: A Postmortem Study. *Am J Med Sci*. 2019;7(3):64-6.
- Kacprzyk A, Droś J, Stefura T, Krzysztofik M, Jasińska K, Pędziwiatr M et al. Variations and morphometric features of the vermiform appendix: A systematic review and meta-analysis of 114,080 subjects with clinical implications. *Clin Anat*. 2020 Jan;33(1):85-98. <https://doi.org/10.1002/ca.23474>
- Gandhi JA, Shinde P, Shetty T, Churiwala J. Retrorenal appendix: An atypical position of the vermiform appendix. *Int J Anat Var Vol*. 2018 Sep;11(3):99.
- Tames AC, Yamauchi FI, Amodeo CD, Cardoso EF, Baroni RH, Tachibana A. Morphologic criteria of vermiform appendix on computed tomography and a possible risk of developing acute appendicitis. *Radiol Brasileira*. 2019 Jun 27;52:217-21. <https://doi.org/10.1590/0100-3984.2018.0118>
- Shaikh M, Gurukkal CM. Anatomical Variations in Position of Vermiform Appendix an Anatomical Study of Aborted Fetuses. *Int J Scient Study*. 2018 Apr 24;6(1):147-50.
- Salim A, Moazzam Z, Ashraf A, Dogar SA, Qazi SH. Congenital absence of the appendix in a child with malrotation. *J Ped Surg Case Reports*. 2020 Sep 1;60:101530. <https://doi.org/10.1016/j.epsc.2020.101530>
- Chauhan S, Anand S. Intracecal appendix: an extremely rare anatomical variation. A case report and review of literature. *Surgical and Radiologic Anatomy*. 2018 Jan;40(1):111-4. <https://doi.org/10.1007/s00276-017-1890-3>
- Kerroum Y, Ahallat M, Ahallat A. Report Case of Appendicitis with Appendicular Duplication: A Rare Anomaly, not to be Overlooked!. *J Medical Surg Res*. 2020 Feb;6:711-3.
- Rait JS, Singh S, Davis H, Fernandes R. Surgical Snapshot: Management of Right Iliac Fossa Pain in Adults and Children.
- Yu D, Gu C, Zhang S, Yang H, Yao T. Ultrasound features and the diagnostic strategy of subhepatic appendicitis. *Ann Translat Med*. 2020 Sep;8(17). <https://dx.doi.org/10.21037/atm-20-5265>
- Hirpara DH, Azzie G. Acute torsion and ischemia of the appendix in a young child. *J Ped Surg case reports*. 2018 Apr 1;31:77-9. <https://doi.org/10.1016/j.epsc.2018.02.006>
- Kachlik D, Varga I, Bácsa V, Musil V. Variant anatomy and its terminology. *Medicina*. 2020 Dec;56(12):713. <https://www.mdpi.com/1648-9144/56/12/713#>
- Fenwick AK, Hartery A. Appendicitis and beyond: a pictorial review of various appendiceal abnormalities. *Emerg Radiol*. 2021 Jun;28(3):651-64. <https://doi.org/10.1007/s10140-021-01908-3>
- Standing S. The anatomy of the large intestine. In *Lower Gastrointestinal Tract Surgery: Vol. 1, Laparoscopic procedures* 2019 (pp. 27-89). Springer, Cham.
- Lahfaoui M, Koulouris E, Alfaour A, Gouizi L. Strangle hernia in the children! not always, amyand hernia with appendicitis. *Open J Pediatr Child Health*. 2020 May 16;5(1):008-10.
- Zhou C, Mawera G, Siwela R. On the anatomy of the appendix among adult black Zimbabweans. *Centr Afr J Med*. 2018;64(1-3):20-5.
- Lamture YR, Salunke B. Anatomical variations related to position of appendix. *J Evol Med Dent Sci*. 2018 Nov 12;7(46):5830-4.