

Reconstruction of Intra-Oral Defects with Submental Artery Flap: A Comparison of pN+ and pN0 Oral Squamous Cell Carcinoma Patients

ABDULLAH KHAN¹, RIAZ AHMED WARRAICH², SADIQ ALI³, ASHFAQ-UR-RAHIM⁴, MUHAMMAD NAUMAN⁵, UROOJ KIRMANI⁶

¹Postgraduate Resident, ²Professor & Director, ³Associate Professor, ⁴Professor, Department of Oral and Maxillofacial Surgery, University College of Dentistry, The University of Lahore

⁵Assistant Professor, Department of Oral and Maxillofacial Surgery, Faryal Dental College, Sheikhpura, Lahore

⁶Department of Orthodontics, Akhtar Saeed Medical & Dental College, Lahore

Correspondence to Dr. Abdullah Khan, e-mail: akmaxfac@gmail.com

ABSTRACT

Aim: To compare the reconstruction of intra-oral defects with submental artery flap among pN+ and pN0 oral squamous cell carcinoma patients.

Methodology: A comparative analytical prospective study was conducted in the Department of Oral and Maxillofacial Surgery, University of Lahore, from January 1, 2022, to November 1, 2022. Fifty-five confirmed cases of oral squamous cell carcinoma were included. The inclusion criteria were based on oral cavity carcinoma patients presenting for tumour resection and reconstruction of the resultant defects with the submental artery flap. A pinch test was applied to estimate the flap width, wherein the flap length and skin paddle were designed in accordance with the defect size.

Results: The mean age of the patients was 58.81±1.2 years, with a significant variance in the pN+ and pN0 patients below 60 years of age. There were 27 males and 18 females with primary treatment of T1–4 OSCC. The primary site of the tumour was observed to be highest in the tongue region in pN+ (52.17%) and pN0 (43.75%) cases, followed by the buccal mucosa, which presented with 30.43% of pN+ cases and 37.5% in pN0 patients. The majority of the patients had moderately differentiated tumours in pN+ (82.6%) and pN0 (56.25%) patients. Within the 55 cases for reconstruction with SAFs, there were 58.1% who had pN0, while 41.8% had pN+ presentation. In the pN0 patients, 96.8% did not have any recurrence, while only 1 patient had local or regional recurrence in the neck region.

Conclusion: Vigilant neck dissection, in addition to suitable adjuvant treatments, does not increase the loco-regional recurrence risk in patients suffering from pN+ oral squamous cell carcinoma.

Keywords: Lymph nodes, submental artery flap (SAF), reconstruction, oral squamous cell carcinoma (OSCC)

INTRODUCTION

Oral squamous cell carcinoma (OSCC) is generally an invasive malignant tumour that can occur anywhere in the oral cavity. OSCC has a high risk for head and neck cancer, which accounts for more than 30% of the patients^{1,2}. It can metastasize even to regional lymph nodes and spread to distant regions as well. Research also shows that it has a high probability of lymph node metastases. Surgery is the only standard solution for such a tumour, involving defect reconstruction, lymph node dissection, and tumour resection. Various methods have been employed for reconstruction of oral squamous cell carcinoma defects of the oral cavity, such as loco-regional flaps and free skin grafting and free flaps^{1,2}.

The applications of skin grafts are mainly limited to superficial defects. Various locoregional flaps are restricted to intraoral defect coverage. 3,4 Free flaps, including the radial forearm or the anterolateral thigh flap, have been in use for the last two decades with great achievement in terms of a wide range of intra-oral defect reconstruction. It is pertinent to note that free flap transfers entail highly qualified staff and microsurgical arrangements, which are commonly linked with longer operative time as well as hospital stays^{5,6}. The reconstruction application of the submental artery flap (SAF) has ranged from small to moderate-sized maxilla-facial soft tissue defects⁷⁻⁹.

Previous clinical research has elaborated on the fact that SAF is related to reduced donor site illnesses in addition to satisfactory outcomes for OSCC-associated defects^{6,10,11}. There have been some concerns relating to SAF interference with the effectiveness of level I lymph node dissections as well as reduced oncologic-OSCC patient prognosis. Due to oncological concerns, there are some studies that recommend the use of SAF only in patients with no clinical or radiological evidence

related to metastasis of a cervical lymph node of level I (cN0)^{12,13}.

In recent years, surgeons have reported innocuous SAF reconstruction in cases with oncological node-positive (pN+) OSCC^{8,14}. However, this evidence seems insufficient due to small-scale studies with limited follow-up time and the unavailability of consensus on signs of SAF in a pN+ setting. The comparison of clinical features as well as oncological outcomes becomes very important for evaluating the oncological wellbeing and consistency of SAFs in patients with pN+ OSCC-associated defects, exclusively for pN+ T1–4 staged OSCC-related defects, having primary pN0 and pN+ OSCC, and undergoing surgical tumour resection as well as SAF reconstruction.

Reconstruction of intra-oral defects with a submental artery flap (SAF) is a surgical technique used in the fields of oral and maxillofacial surgery and plastic surgery. This procedure is commonly performed to address defects or tissue loss within the oral cavity, often resulting from cancer resection, trauma, or other medical conditions. The submental artery flap is a reliable and versatile option for reconstructing such defects. The submental artery flap is particularly useful in cases where other reconstructive options may not be suitable or when preserving the function and aesthetics of the oral cavity is of utmost importance. This technique has been widely adopted due to its reliability and the favourable outcomes it offers for patients with intra-oral defects⁵⁻⁹.

The present study was designed for the evaluation of reconstruction of intra-oral defects with submental artery flaps among pN+ and pN0 oral squamous cell carcinoma patients. The results will also prove substantial in evaluating the oncological reliability and safety of submental artery flaps for both pN+ and pN0 oral squamous cell carcinoma patients. This analysis can provide insights into the efficacy and outcomes of this surgical technique in patients with varying nodal statuses.

A large-scale multi-center study along with a longer follow-up time is required for the exact demonstration and evaluation of safety related to submental flap usage in OSCC reconstruction.

Received on 11-05-2023

Accepted on 24-07-2023

MATERIALS AND METHOD

In the present study, a total of 55 diagnosed cases of oral squamous cell carcinoma were included through convenient sampling. The present study was conducted in the Department of Oral and Maxillofacial Surgery at the University of Lahore (UOL) after approval from IRB within the period of January 2022 to November 2022. The study was based on comparative analysis and a prospective design. An ethical approval was formally obtained before research initiation. The sample size was calculated using the WHO sample size calculator, wherein the confidence interval was taken as 95% and 5% of the power of the test and the margin of error, respectively. Males and females of all age groups and races were included in this study. Biopsy Proven cases of oral squamous cell carcinoma were the only ones included. The exclusion criteria consisted of patients who had completed or were undergoing chemotherapy, radiotherapy, or surgical procedures, and patients diagnosed with secondary or any other malignancy who refused to be part of this study. An informed consent was obtained from each patient before their enrollment as a study participant. All patients' demographic details as well as clinical presentation, history, and related comorbidities were detailed on a well-structured questionnaire. During surgery, all patients underwent tumour (OSCC) resection, neck dissection, and submental artery flap (SAF) reconstruction. This surgery was performed by a single surgeon wearing loupes at the department of oral and maxillofacial surgery in the UOL Teaching Hospital. Tumours were resected with a safety margin of at least 1-2 cm. Marginal clearance was achieved with the help of per-op frozen section analysis. After local tumour resection, a pinch test was performed, and a template was fabricated according to the size of the defect. Transverse cervical and anterior flap incisions were made down to the mandible. Subsequently, after the elevation of the subplatysmal flap, the marginal mandibular nerve was identified and preserved. The anteromedially directed submental artery and vein were identified after the facial artery and vein were exposed and dissected away from the submandibular gland. In this way, SAF was raised, which also incorporated the ipsilateral anterior belly of the digastric muscle, preserving the mylohyoid muscle. The pre-vascular, post-vascular, and pre-glandular lymph nodes were carefully excised as part of level Ib lymph nodes, and the submental triangle (level Ia) lymph nodes lying anterior to the anterior belly of digastric muscle were excised. Later, lymph nodes present superficially over the vascular pedicle were meticulously excised under loupes magnification. SAF was transferred to the recipient site intra-orally after creating a tunnel between the mylohyoid muscle, submandibular area, and labial vestibule (in accordance with the recipient site). The intra-oral recipient site was closed with a Vicryl Rapide 2-0 suture. The donor site was closed primarily in a layered fashion. After 21 days of surgery, patients with pN+ and high-grade tumours received adjuvant chemoradiotherapy after consultation with the oncologist. All 55 patients were included in a standardised post-therapeutic follow-up protocol that mainly included clinical consultations once every week for the first month, followed by monthly follow-up visits for the next 5 months. In these follow-up visits, the locoregional status was assessed clinically by the same surgeon, and any sort of recurrence was noted and dealt with with surgery. The cutoff date for follow-up was May 1, 2023. The data was analysed using SPSS 26.0. A chi-square test was used to analyse variables, wherein a p value <0.05 was taken as significant.

RESULTS

In the present study, the mean age of the patients was 58.81±1.2 years, with a significant variance in the pN+ and pN0 patients below 60 years of age. There were 27 males and 18 females

with primary treatment of T1–4 OSCC; systematic diseases and use of narcotics were higher in pN+ patients (Table 1).

The primary site of the tumour was observed to be highest in the tongue region in pN+ (52.17%) and pN0 (43.75%) cases, followed by the buccal mucosa, which presented with 30.43% of pN+ cases and 37.5% in pN0 patients. The pT stage presented the highest number of pN+ patients in the T3 stage, while pN0 cases were higher in both the T2 and T3 stages (Table 2).

The majority of the patients had moderately differentiated-grade tumours in pN+ (82.6%) and N0 (56.25%). The pN+ patients were opted for surgery + CRT (chemoradiotherapy), while combinational treatments were not opted for in the pN0 patients (Fig. 1).

Within the 55 cases for reconstruction with SAFs, there were 58.1% who had pN0, while 41.8% had pN+ presentation. In the pN0 patients, 96.8% did not have any recurrence, while 01 patient had local regional recurrence in the neck region. However, in the pN+ patients, 17.39% of the patients had local regional recurrence in the neck region of the tumour (Fig. 2).

Within the total lymph nodes analysed, it was observed that grade II was reported to be higher in males than females with N1M0 and N2M0 presentations in cases > 60 years old. With the increase in grading, there was no variance observed in the neck recurrence site. In a female case where the age was above 60 years, having T4N2M0 with a grade III tumour had a recurrence at neck level 4, and therefore the salvage treatment constrained surgery in addition to the targeted therapy (Table 3).

Table 1: Demographic of patients stratified by lymph node status

Variable	pN+ (n=23)	pN0 (n=32)	P value
Age (years)			
< 60	13	21	0.049
≥ 60	10	11	
Gender			
Male	19	18	0.851
Female	4	14	
Smoking			
Ever	12	6	0.035
Never	11	26	
Alcoholics			
Ever	2	1	0.212
Never	21	31	
Pan chewer			
Ever	19	7	0.025
Never	4	25	

Table 2: Characteristics of tumor along with its treatment on the basis of lymph nodes status

Variable	pN+ (n=23)	pN0 (n=32)	P value
Primary site			
Tongue	12	14	0.156
Buccal mucosa	7	12	
Retromolar trigone region	2	3	
Floor of mouth	1	1	
Mandibular alveolar mucosa	1	2	
pT Stage			
T1	-	2	0.352
T2	3	15	
T3	12	15	
T4	8	-	
Grade			
Well differentiated	-	14	0.311
Moderately differentiated	19	18	
Poorly differentiated	4	-	
Treatment			
Surgery	-	29	0.015
Surgery+ RT	6	3	
Surgery+ CRT	17	-	

Table 3: Comparison of total lymph nodes

Gender/Age	Site	pT NM	Grade	Treatment of Neck	Condition of LN	Post operative Treatment	Recurrent Site	Recurrence Month	Salvage Treatment
M/52	Buccal Mucosa	T4N0M0	II	Functional ND	Ib LN+	CRT	Neck level 2a	04	S
M/63	Tongue	T2N1M0	II	Functional ND	Ila LN+	CRT	Neck level 2b	05	S
M/51	Tongue	T3N1M0	II	Functional ND	Ila LN+	CRT	Neck level 3	06	S+CT
F/67	Buccal Mucosa	T3N2M0	III	Functional ND	Ib LN+	CRT	Neck level 2a	03	S
F/61	Tongue	T4N2M0	III	Functional ND	III LN+	CRT	Neck level 4	06	S+ targeted therapy

Fig. 1: Illustration of various sites of tumor and pN staging

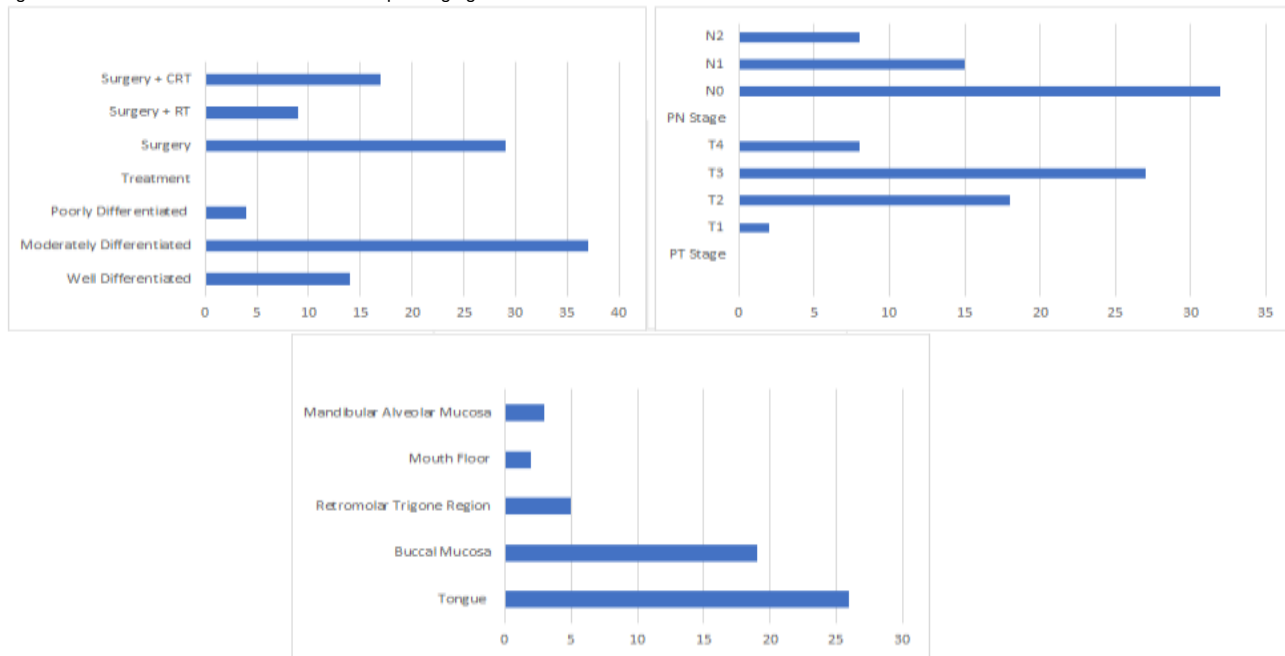
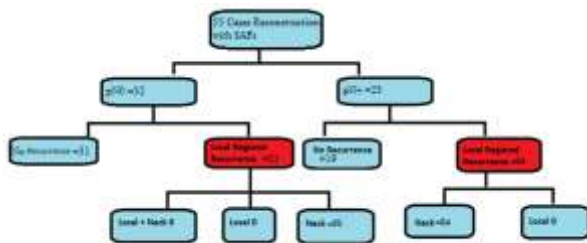


Fig. 2: Lymph node analysis flow chart



DISCUSSION

This was a comparative analysis study that provided a valuable insight into the effectiveness of submental artery flap reconstruction in different patient populations, helping clinicians make informed decisions in the management of oral squamous cell carcinoma patients. OSCC is specifically preferred to maximise the radial area for tumour resection. This showed significant improvement in quality of life and rehabilitation of oral function. Though the microvascular free flap has now become the gold standard for treatment, every patient is satisfied enough with this procedure. Although the use of microvascular free flap transfer has become the “gold standard” in recent years, not every patient is a candidate for a microvascular procedure.

In the present study, a smoking history was observed in the majority of the patients, while 47.2% were pan chewers. The result of the present study highlights that the majority of the patients were >60 years of age, and this further adds to the elevated risk of free flap techniques. Furthermore, these systematic conditions increase the risk of tumours in older patients. The present study, as well as related literature elsewhere, has detailed the fact that pedicled SAF reconstruction proves helpful in decreasing perioperative risk along with maintaining oncologic goals and reconstruction. The present study also highlights that SAF reconstruction did not increase the incidence of loco-regional tumour recurrence and that utilisation of SAF was not related to the individual oncological prognosis in patients with T1-T4 OSCC. Similar findings have been reported in a comparative analysis of reconstructing intra-oral defects with the submental artery flap in pN+ (pathologically confirmed positive lymph nodes) and pN0 (pathologically confirmed negative lymph nodes) oral squamous cell carcinoma patients. This is a critical topic in the field of head and neck surgery^{10,11}.

Although there is contrary literature available wherein it is stated that SAF may not be able to properly address every defect^{14,15,16}. However, in the present study, by comparing the clinical results of pN0 and pN+ patients, it was demonstrated that submental artery flaps did not increase the chances of loco-regional tumour recurrence, and oncological prognosis was also not related in patients with T1-T4 OSCC^{12,13}. In previous studies, the oncological safety of SAF has been clearly demonstrated through comparisons between both types of flap treatment^{13,16,17}.

Despite the above-reported evidence, researchers have long debated the safety parameters of SAF in pN+ patients. The present study also shows the recurrence rate within the pN+ and pN0 was observed as 17.39% and 3.125%, respectively. The local recurrence, specifically in the neck region, was reported in the current research and is comparable with another study, which reported 11.1%⁹. Mizrachi et al¹⁸ confirmed that around 15% of cN0 OSCC patients developed neck failure. The results of this study are also comparable with the present research interpretations, although lower than the results provided by Mizrachi and his colleagues¹⁸. Similar findings have been reported in earlier studies, where the recurrence rate was within 0-12%, with the neck being the general site of local recurrence^{9,12,19,20}.

When a large piece is needed for reconstruction of mylohyoid muscle, a musculocutaneous flap and skin territory of 10x16 cm² could be safely harvested, according to the results of various studies^{17,18}. However, free flap transfer is also a suitable option that can facilitate resection and ensure proper surgical margins. Various studies have also proved submental artery flap safety^{19,20}.

CONCLUSION

Vigilant neck dissection In addition to suitable adjuvant treatments, the use of SAF does not increase the risk of locoregional recurrence in patients suffering from pN+ OSCC in comparison to those with pN0 OSCC.

Authorship and contribution declaration: Each author of this article fulfilled following Criteria of Authorship:

1. Conception and design of or acquisition of data or analysis and interpretation of data.
2. Drafting the manuscript or revising it critically for important intellectual content.
3. Final approval of the version for publication.

All authors agree to be responsible for all aspects of their research work.

Conflict of interest: None

Funding: None

REFERENCES

1. Gong ZJ, Ren ZH, Wang K, Tan HY, Zhang S, Wu HJ. Reconstruction design before tumour resection: a new concept of through-and-through cheek defect reconstruction. *Oral Oncol.* 2017;74:123–9.
2. De Bree R, Takes RP, Castelijns JA, Medina JE, Stoeckli SJ, Mancuso AA, Hunt JL, Rodrigo JP, Triantafyllou A, Teymoortash A, Civantos FJ. Advances in diagnostic modalities to detect occult lymph node metastases in head and neck squamous cell carcinoma. *Head & neck.* 2015 Dec;37(12):1829-39.
3. Patel AV, Thuener JE, Clancy K, Ascha M, Manzoor NF, Zender CA. Submental artery island flap versus free flap reconstruction of lateral facial soft tissue and parotidectomy defects: comparison of outcomes and patient factors. *Oral Oncol.* 2018;78:194–9.
4. Faisal M, Adeel M, Riaz S, Anwar A, Rashid A, Usman S, et al. The submental island flap in head and neck cancer. *Ann Maxillofac Surg.* 2018;8:287–91.
5. Chaudhary B, Gong Z, Ling B, Lin Z, Abbas K, Hu M, et al. Application of the submental island flap in the reconstruction of intraoral defects. *J Craniofac Surg.* 2014;25:e309–12.
6. Sebastian P, Thomas S, Varghese BT, Iype EM, Balagopal PG, Mathew PC. The submental island flap for reconstruction of intraoral defects in oral cancer patients. *Oral Oncol.* 2008;44:1014–8.
7. Martin D, Pascal JF, Baudet J, Mondie JM, Farhat JB, Athoum A, et al. The submental island flap: a new donor site. Anatomy and clinical applications as a free or pedicled flap. *Plast Reconstr Surg.* 1993;92:867–73.
8. Sittitrai P, Srivanitchapoom C, Reunmakkaew D, Yata K. Submental island flap reconstruction in oral cavity cancer patients with level I lymph node metastasis. *Brit J Oral Max Surg.* 2017;55:251–5.
9. Kramer FJ, Bohrsen F, Moser N, Schliephake H. The submental island flap for the treatment of intraoral tumor-related defects: no effect on recurrence rates. *Oral Oncol.* 2015;51:668–73.
10. Moubayed SP, Rahal A, Ayad T. The submental island flap for soft-tissue head and neck reconstruction: step-by-step video description and long-term results. *Plast Reconstr Surg.* 2014;133:684–6.
11. Rahpeyma A, Khajehahmadi S. Submental artery island flap in intraoral reconstruction: a review. *J Cranio Maxill Surg.* 2014;42:983–9.
12. Howard BE, Nagel TH, Donald CB, Hinni ML, Hayden RE. Oncologic safety of the submental flap for reconstruction in oral cavity malignancies. *Otolaryngol Head Neck Surg.* 2014;150:558–62.
13. Mäkitie A, Vuola J, Lassus P, Bäck L, Acarturk T, Suominen S, et al. Submental artery flap with sentinel lymph node biopsy in the reconstruction of oral cancer. *J Reconstr Microsurg.* 2015;32:153–9.
14. Eskander A, Strigenz D, Seim N, Ozer E. Submental artery island flap with simultaneous level I neck dissection. *Head Neck.* 2018;40:842–5.
15. Faltaous AA, Yetman RJ. The submental artery flap: an anatomic study. *Plast Reconstr Surg.* 1996;97:56–60.
16. Amin AA, Sakkary MA, Khalil AA, Rifaat MA, Zayed SB. The submental flap for oral cavity reconstruction: extended indications and technical refinements. *Head Neck Oncol.* 2011;3:51.
17. Rahpeyma A, Khajehahmadi S, Razmara F. Submental flap in intraoral reconstruction after pathologic resections: indications and limitations. *J Maxillofac Oral Surg.* 2015;14:57–62.
18. Mizrachi A, Migliacci JC, Montero PH, McBride S, Shah JP, Patel SG, et al. Neck recurrence in clinically node-negative oral cancer: 27-year experience at a single institution. *Oral Oncol.* 2018;78:94–101.
19. Zanoni DK, Montero PH, Migliacci JC, Shah JP, Wong RJ, Ganly I, et al. Survival outcomes after treatment of cancer of the oral cavity (1985–2015). *Oral Oncol.* 2019;90:115–21.
20. Liang L, Zhang T, Kong Q, Liang J, Liao G. A meta-analysis on selective versus comprehensive neck dissection in oral squamous cell carcinoma patients with clinically node-positive neck. *Oral Oncol.* 2015;51:1076–81

This article may be cited as: Khan A, Warraich RA, Ali S, Rahim AU, Nauman M, Kirmani U: Reconstruction of Intra-Oral Defects with Submental Artery Flap: A Comparison of pN+ and pN0 Oral Squamous Cell Carcinoma Patients. *Pak J Med Health Sci.* 2023; 17(9): 2-5.