

Comparison of Intra-lesional Verapamil and Intra-lesional Triamcinolone Acetonide in Treatment of Keloid

RUBAB ANJUM^{1*}, TAHIR HASSAN¹, MUHAMMAD KHURRAM SHAHZAD¹, NAIMA ALIYA¹, ZUNAIRA ANJUM², GUL-E- RUKH³

¹Department of Dermatology, Sheikh Zayed Hospital, Rahim Yar Khan-Pakistan

²Department of Medicine, CMH Hospital, Lahore-Pakistan

³Department of Anaesthesia, HBS General Hospital, Islamabad-Pakistan

Correspondence to Dr Rubab Anjum, E-mail: anjumrubab722@gmail.com, Tel+92-332-7692579

ABSTRACT

Background: Keloid is a fibrous tissue that extends past the edges of an incision. Intralesional triamcinolone acetonide is the corticosteroid most frequently used to treat keloids.

Aim: To contrast the effects of intralesional triamcinolone acetonide and intralesional verapamil in treating keloid among dermatology department patients.

Study Design: Comparative clinical study.

Methodology: The current study was carried out at dermatology department with enrollment of 60 individuals each in both groups. Using a 30 gauge needle connected to an insulin syringe, both groups underwent intra-lesional injections in keloids three weeks apart for a total of six sessions. After the treatment was over for three months, a follow-up was conducted. SPSS 23 was used for the data analysis. Chi-square/exact Fisher's tests with a p-value of less than 0.05 were used to compare the gender distribution, outcomes, responder, and recurrence rate between the two groups.

Results: Patients in group A had a mean age of 28.1 +/- 5.4 years, while those in group B had a mean age of 29.3 +/- 4.7 years. There was insignificant difference in terms of remission between both groups with 53 (88.3%) of patients in group A and 58 (96.7%) of patients in group B. However, recurrence was seen in 2 (3.3%) of the patients in group B, compared to 6 (10%) of the patients in group A, with an insignificant p-value (0.272).

Practical Implication: Due to its affordability and safety, this study aided researchers in examining the effectiveness of intra-lesional verapamil as a treatment for keloid removal. Second, it contributed to the body of knowledge in the area regarding other comparable and successful treatment choices.

Conclusion: It was concluded that there was insignificant difference among both groups with respect to outcomes having p-value greater than 0.05.

Key words: Keloid, Intralesional Verapamil, Triamcinolone Acetonide and Clinical Outcomes.

INTRODUCTION

Keloid is a fibrous tissue that extends past the edges of an incision¹. They result from an overgrowth of dermal collagen and have a negative physiological and physical impact.² Collage and glycosaminoglycan deposition are increasing histologically. They consist of thicker collagen whorls that have been hyalinized and more cellular skin tissue³.

They typically do not spontaneously regress, and after excision, they show a high likelihood of recurrence. Keloids begin to thicken and produce raised patches within 3 to 4 weeks⁴. Although they can occur everywhere on the body, the sternum, shoulders, earlobes, and cheeks are where they most frequently do^{2,5}. In some instances, vulnerable persons can develop keloids on their sternums on their own. It can occur after the onset of acne or a chickenpox infection^{4,6}.

Frequent keloids can be challenging to cure because of their complexity. There are many different techniques being used, but none of them, whether used separately or in combination, yield results that are very encouraging⁵. Literature review showed that various medical options like compression bandages, silicone gel, scar revision surgery, intralesional interferon injection, and laser therapy have been employed both for its prevention and treatment⁶. Intralesional triamcinolone acetonide, which inhibits fibroblast growth factors, lowers collagen and glycosaminoglycan synthesis, and accelerates collagen and fibroblast degeneration, is the corticosteroid most frequently used to treat keloids^{7,8}.

According to previous studies new agent like verapamil, was also used to treat them. Its intra-lesional administration reduces extracellular collagen while increases production of collagenases, thus breaking collagen easy⁸⁻¹⁰.

Due to lack of local data regarding verapamil role in keloid management so we planned current study to compare the effects

of intralesional triamcinolone acetonide and intralesional verapamil in treating keloid in dermatology department patients.

METHODOLOGY

This was comparative clinical study. Patients were enrolled through simple random sampling with written consent. Study was conducted at OPD Department of Dermatology Sheikh Zayed Hospital Rahim Yar Khan after permission from ethical committee. The sample size of present study was 120 patients. Each selected group will have 60 patients. The sample size was estimated using 90% power of the study, 95% confidence level, and assuming the efficacy of Verapamil is 53.5% and 78.5% with Triamcinolone.

Patients were divided into 02 groups (A&B). In each group, Group-A received intra-lesional verapamil and Group-B received intra-lesional triamcinolone acetoneid. Both groups received intra-lesional injections in keloids 03 weeks apart for maximum six sessions using a 30-gauge needle attached to an insulin syringe with mild modifications with previous study.¹⁰ Follow up was done after 03 months of completion of treatment. Baseline data was taken on proforma.

Both males/females patients having age (15-50 years), size of Keloid (Upto 15 cm), number of Keloids (Upto 4), duration of keloids (02years) were included. However, patients having known hypersensitivity reaction to verapamil and triamcinolone acetoneid, other co-morbidities like cardiovascular disease, infected keloids or previously treated patients for keloids during last 03 months or pregnant/lactating mothers were excluded.

Statistical Analysis: Data was analyzed through SPSS 23. Mean \pm SD were given for numeric data i.e., age and number of keloids. The frequency and percent were calculated for categorical data i.e., gender, results, responder and recurrence. Chi-square/ Fisher's exact tests were used to compare the gender distribution, results, responder and recurrence rate between both groups with p-value less than 0.05 as significant. Independent sample t test was also applied.

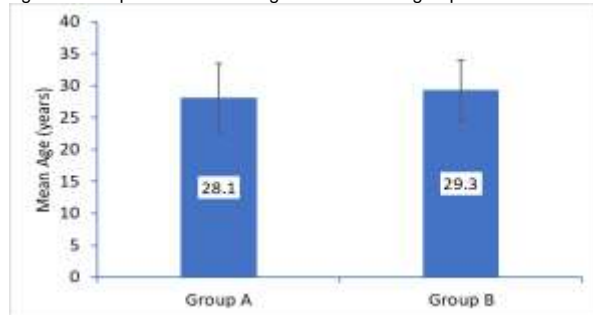
Received on 07-11-2022

Accepted on 26-04-2023

RESULTS

Comparison of mean \pm SD for ages among both groups showed that group-A had 28.1 ± 5.4 years while other group-B had 29.3 ± 4.7 years as shown in figure-1.

Figure 1: comparison of mean age between both groups



To compare the distribution of gender between two groups, the Chi-square test was employed. According to table-1, there was insignificant difference among gender distribution between two groups having p-value of 0.511.

Table-1: Comparison of gender distribution between both groups

Variables	Categories	Group A	Group B	P-value
Gender	Male	37 (61.7%)	34 (56.7%)	0.511
	Female	23 (38.3%)	26 (43.3%)	

The mean number of keloids and mean number of treatment sessions for patients who underwent treatment for keloids were displayed in the table-2 below. The average number of keloids for Group A (Verapamil) was 1.28 ± 0.49 . While for Group B (Triamcinolone), the mean number of keloids was 1.40 ± 0.49 and the mean number of treatment sessions was 3.38 ± 0.48 , the mean number of treatment sessions was 3.82 ± 0.39 in this group.

Table-2: Comparison of number of keloids and sessions between both groups

Variables	Group -A	Group B
Number of Keloids	1.28 ± 0.49	1.40 ± 0.49
Number of sessions	3.82 ± 0.39	3.38 ± 0.48

Table-3 displayed the frequencies of remission and recurrence in two patient groups. 53 (88.3%) of the patients in group A experienced remission, compared to 58 (96.7%) of the patients in group B. The two groups' remission rates did not differ statistically significantly, as shown by the p-value of 0.163. Similarly, two group's recurrence rates did not differ significantly, as shown by p-value of 0.272 (Table-3) although, there was low recurrence among groups.

Table-3: Comparison of remission and recurrence rate between both groups

Variables	Categories	Group A	Group B	P-value
Results	Remission	53 (88.3%)	58 (96.7%)	0.163
	Non-remission	7 (11.7%)	2 (3.3%)	
Recurrence	Yes	6 (10.0%)	2 (3.3%)	0.272
	No	54 (90.0%)	58 (96.7%)	

DISCUSSION

According to a literature review, hypertrophic scars and keloids are major cosmetic problems since they deform the affected area and produce modest abnormalities¹². They exhibit an augmented immune-inflammatory response to an unidentified trigger pathophysiologically. Because of this, patients need early and effective treatment to reduce additional physical and psychological morbidity. Newer, safe, and less expensive therapy methods are being sought to achieve better treatment outcomes with little

adverse effects as daily medical advancements take place. As a result, the keloid therapy drugs verapamil and triamcinolone were showing promising outcomes¹¹. Since there was no local comparative study on keloid treatment due to a lack of research culture, the current study was planned.

One hundred and twenty volunteers from both sexes were enrolled in the current study. In the current project, 59.1% more men than women (or 40.9% more men) were registered. Similar to other past studies, which included more men (55%) than women, our enrollment process was consistent with other studies¹².

One previous study held in 2020 at Nigeria compared the efficacy and side effects among patients given treatment for keloids. They concluded that complete resolution of symptoms happened in group receiving Triamcinolone over 6-8 weeks of treatment¹³. Our results were in line with above mentioned study that showed 3.3% recurrence in patients receiving Triamcinolone. Paradoxically, another study showed that there was statistically significant difference in Triamcinolone group with respect to change in Pliability score and height as compared to Verapamil.¹⁴ In present study, insignificant difference was seen among both groups.

In the current study, keloids could last up to two years and there could be as many as four keloids. According to our findings, the average number of keloids in Group-A (Verapamil) was 1.28 ± 0.49 . While for Group-B (Triamcinolone), the mean number of keloids was 1.40 ± 0.49 and the mean number of treatment sessions was 3.38 ± 0.48 , the mean number of treatment sessions for this group was 3.82 ± 0.39 . One earlier study's duration of keloids (scars) was 4-9 months, therefore^{12,15}.

53(88.3%) of the patients in group A experienced remission, compared to 58(96.7%) of the patients in group B. There was no statistically significant difference in the rates of remission between the two groups, as indicated by the p-value of 0.163 (table-3). Similar to this, in many other earlier investigations, groups receiving intralesional triamcinolone shown significant levels of remission up to 90%¹⁵⁻¹⁷. Our findings were in accordance with a prior study, which found that both groups had even high levels of remission up to 97% with no discernible p-value between the groups.

Similar to this, the intra-lesional verapamil group saw slightly higher recurrence (10%) than the control group (3.3%). Several earlier trials that indicated intra-lesional Triamcinolone as an efficient treatment for keloids revealed a similar, low failure rate of 5%. Nonetheless, several research used VSS scores to track advancements in results¹². This scoring system, which took into account keloid height, vascularity, and pigmentation, was absent from the current investigation. Hence, the clinical results varied.

Limitations of study: Financial constrains and limited resources with no genetic workup and long follow-ups added to limitations.

CONCLUSIONS

It was concluded that there was insignificant difference among both groups with respect to outcomes having p-value greater than 0.05 when applied as treatment for keloids. Therefore, intra-lesional verapamil can be used as new safe and cheap treatment for keloids as its treatment outcomes were similar to standard treatment hence, it can help in better management of keloids among patients at our clinical setups.

Author's contribution: RA, TH & MKS: Overall supervision and Write up and literature review, NA, ZA & GER: Literature review help in write-up.

Conflict of interest: None

Funding: None

REFERENCES

- Kant SB, van den Kerckhove E, Colla C, Tuinder S, van der Hulst RRWJ, Piatkowski de Grzymala AA. A new treatment of hypertrophic and keloid scars with combined triamcinolone and verapamil: A retrospective study. *Eur J Plast Surg* 2018;41:69-80.

2. Parnell LKS. Itching for knowledge about wound and scar pruritus. *Wounds* 2018;30:17–36.
3. Aggarwal A, Ravikumar BC, Vinay KN, Raghukumar S and Yashovardhana DP (2018): A comparative study of various modalities in the treatment of keloids. *Int J Dermatol.*, 57(10): 1192- 1200.
4. Berman B, Maderal A, Raphael B (2017): Keloids and hypertrophic scars: pathophysiology, classification, and treatment. *Dermatol Surg.*, 43: S3-S18.
5. Perdanasari AT, Torresetti M, Grassetti L, Nicoli F, Zhang YX and Dashti T (2015): Intralesional injection treatment of hypertrophic scars and keloids: a systematic review regarding outcomes. *Burns Trauma*, 3:14.
6. Tripathi, Soni K, Agrawal P, Gour V, Mondal R and Soni V (2020): Hypertrophic scars and keloids: a review and current treatment modalities. *Biomedical Dermatology*, 4:11
7. Verhiel S, Piatkowski de Grzymala A and van der Hulst R (2015): Mechanism of Action, Efficacy, and Adverse Events of Calcium Antagonists in Hypertrophic Scars and Keloids: A Systematic Review. *Dermatol Surg.*, 41:1343–1350.
8. Wang R, Danielsen PL, Ågren, MS, Duke J, Wood F, Zeng XX, Mao Y and Cen Y (2021): Corticosteroid Injection Alone or Combined with Surgical Excision of Keloids versus Other Therapies Including Ionising Radiotherapy: A Systematic Review and Meta-Analysis of Randomised Controlled Trials. *Eur. Burn J.*, (2):41–54.
9. Kuang J, An P and Li W (2021): Comparative efficacy and safety of verapamil and triamcinolone in keloid and hypertrophic scar treatment: a meta-analysis. *Journal of Cosmetic and Laser Therapy*, 18: 1-9.
10. Li Z and Jin Z (2016): Comparative effect and safety of verapamil in keloids and hypertrophic scar treatment: a meta-analysis. *Therapeutics and clinical risk management.*, 12:1635-1641.
11. Yang SY, Yang JY, Hsiao YC and Chuang SS (2017): A comparison of gene expression of Decorin and MMP13 in hypertrophic scars treated with calcium channel blocker, steroid, and interferon: a human-scar-carrying animal model study. *Dermatol Surg.*, 43 (Suppl 1): S37- S46.
12. Zamanian A, Nokandeh M, Behrangi E, Fazel Z and Azizian Z (2017): Comparing Efficacy and Tolerability of Triamcinolone and Verapamil in Treatment of Hypertrophic Scars and Keloids, *J Skin Stem Cell*, 4(3-4): e69390.
13. Belie O, Ugburo AO, Mofikoya BO, Omidiji OA, Belie MF. A comparison of intralesional verapamil and triamcinolone monotherapy in the treatment of keloids in an African population. *Nigerian Journal of Clinical Practice.* 2021;24(7):986-92.
14. Tumrani R, Hanif MM, Hassan T, Hanif N. Comparing the Efficacy of Intralesional Verapamil Hydrochloride vs Triamcinolone Acetonide in Treatment of Keloids/Hypertrophic Scars. *Pakistan Journal of Medical Research.* 2022;61(1):15-8.
15. Garg AM, Shah YM, Garg A, Zaidi S, Saxena K, Gupta K, et al. The efficacy of intralesional triamcinolone acetonide (20mg/ml) in the treatment of keloid. *Int Surg J* 2018; 5(3): 868-72.
16. Shin JU, Kim SH, Kim H, et al. TSLP Is a Potential Initiator of Collagen Synthesis and an Activator of CXCR4/SDF-1 Axis in Keloid Pathogenesis. *J Invest Dermatol* 2016; 136: 507.
17. Abedini R, Sasani P, Mahmoudi HR, Nasimi M, Teymourpour A, Shadlou Z. Comparison of intralesional verapamil versus intralesional corticosteroids in treatment of keloids and hypertrophic scars: A randomized controlled trial. *Burns* 2018; 44(6): 1482-8.