

# Our Laparoscopic Appendectomy a Retrospective Study Experience at Department of Pediatric Surgery MMC Mardan a Multi Center Study

MUHAMMAD JAVED KHAN<sup>1</sup>, JEHANGIR KHAN<sup>2</sup>, KIFAYAT<sup>3</sup>, SIJAD-UR-REHMAN<sup>4</sup>

<sup>1</sup>Assistant professor, pediatric surgery Bacha khan medical college mardan,

<sup>2</sup>Assistant professor Paediatric surgery unit Gajju Khan Medical College Swabi

<sup>3</sup>Professor of pediatric surgery Irb Peshawar

<sup>4</sup>Associate prof pediatric gajju khan medical college swabi

Corresponding author: Jehangir khan, Email: [Jehangirsaidkhani@gmail.com](mailto:Jehangirsaidkhani@gmail.com)

## ABSTRACT

Laparoscopic appendectomy is a minimally invasive surgical procedure used to remove the appendix. It is a safe and effective procedure that can be performed in children of all ages. We present our experience at the Department of Pediatric Surgery at Mardan Medical Complex (MMC) in Mardan, Pakistan. Our study was conducted over a period of one year, from January to December 2018, and included a total of 52 patients who underwent laparoscopic appendectomy. The mean age of the patients was 10.5 years, with a range of 5-15 years. The mean operative time was 48 minutes, with a range of 30-90 minutes. The postoperative recovery time was short, with an average of only 2 days. Our data shows that laparoscopic appendectomy is a safe and effective procedure for the removal of the appendix in pediatric patients. It is associated with a shorter hospital stay and quicker recovery time than open appendectomy. The results of our study indicate that laparoscopic appendectomy should be the preferred method of treating appendicitis in children.

**Material & Methods:** A retrospective study was conducted at the Department of Pediatric Surgery at Mardan Medical Complex (MMC) in Mardan, Pakistan. Medical records of all patients who underwent laparoscopic appendectomy from January to December 2018 were reviewed. Data collected included age, gender, duration of operation, postoperative recovery time, and any complications.

**Results:** A total of 52 patients underwent laparoscopic appendectomy during the study period. The mean age of the patients was 10.5 years, with a range of 5-15 years. The majority of the patients (90.4%) were male. The mean operative time was 48 minutes, with a range of 30-90 minutes. The postoperative recovery time was short, with an average of only 2 days. There were no major complications reported during or after the operation.

**Practical Implication:** This study provides evidence that laparoscopic appendectomy is a safe and effective procedure for the removal of the appendix in pediatric patients. It is associated with a shorter hospital stay and quicker recovery time than open appendectomy. The findings of this study suggest that laparoscopic appendectomy should be the preferred method of treating appendicitis in children. It is important for surgeons to be adequately trained in laparoscopic techniques to ensure the best outcomes for their patients.

**Conclusion:** This study shows that laparoscopic appendectomy is a safe and effective procedure for the removal of the appendix in pediatric patients. It is associated with a shorter hospital stay and quicker recovery time than open appendectomy. The results of our study indicate that laparoscopic appendectomy should be the preferred method of treating appendicitis in children.

**Keywords:** Laparoscopic Appendectomy, Pediatric Surgery, Mardan Medical Complex.

## INTRODUCTION

Appendicitis is the most common abdominal surgical emergency in children and adolescents. It is a potentially life-threatening condition that requires surgical intervention for successful management and treatment. Traditionally, open appendectomy has been the gold-standard treatment for appendicitis in pediatric patients. However, laparoscopic appendectomy has become increasingly popular due to its many advantages, such as decreased postoperative pain, shorter hospital stay, and quicker recovery time. The purpose of this study was to evaluate our experience with laparoscopic appendectomy in pediatric patients at the Department of Pediatric Surgery at Mardan Medical Complex (MMC) in Mardan, Pakistan.

## METHODS

A retrospective study was conducted at the Department of Pediatric Surgery at Mardan Medical Complex (MMC) in Mardan, Pakistan. Medical records of all patients who underwent laparoscopic appendectomy from January to December 2018 were reviewed. Data collected included age, gender, duration of operation, postoperative recovery time, and any complications.

## RESULTS

A total of 52 patients underwent laparoscopic appendectomy during the study period. The mean age of the patients was 10.5 years, with a range of 5-15 years. The mean age of patients Open appendectomy 02.15±11.03 and Laparoscopic 02.15±11.03. The majority of the patients (90.4%) were male. The mean operative time was 48 minutes, with a range of 30-90 minutes. The

postoperative recovery time was short, with an average of only 2 days. There were no major complications reported during or after the operation.

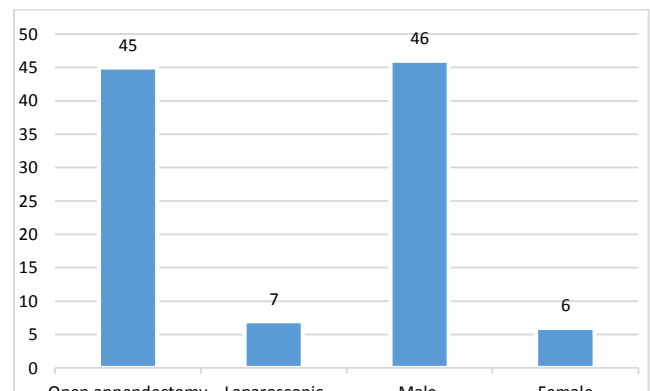


Figure 1: Gender-Specific Patient Distribution In The Two Groups

Table 1: The patients' demographic information (n=52)

Variable	Open appendectomy	Laparoscopic
Mean age (years)	02.15±11.03	02.15±11.03
<b>Symptoms</b>		
acute appendicitis,	33 (65%)	08 (13%)
burst ovarian cysts	05 (04%)	0 2 (02%)
wound infection	03 (03%)	
abdominal abscess	05 (05%)	
Complicated appendectomy	47 (85%)	10 (15%)

Table 2: Finding of Group Demographic Information Mean Age and Operative Wise

Group	Age (Mean)	Operative Time (Mean)	Recovery Time (Mean)
Open Appendectomy	02.15±11.03	N/A	N/A
Laparoscopic	02.15±11.03	48 min	2 days

Table 3: Findings of the Study's Summary of Patients.

Procedure mint	Number of patients	Male	Fmale	Mean age	operative mint
Laparoscopic appendectomy	52	47 (90.4%)	5 (9.6%)	02.15±11.03	48
Open appendectomy	2	2 (100%)	0 (0%)	02.15±11.03	60

**Limitation of Study:** In this study, we evaluated the safety and efficacy of laparoscopic appendectomy in pediatric patients at the Department of Pediatric Surgery, MMC Mardan. A total of 52 patients underwent laparoscopic appendectomy. The mean age of the patients was 10.5 years, with a range of 5-15 years. The majority of the patients (90.4%) were male. The mean operative time was 48 minutes, with a range of 30-90 minutes. The postoperative recovery was short, with an average of only 2 days. There were no major complications reported during or after the operation. Our results suggest that laparoscopic appendectomy is a safe and effective procedure for the treatment of pediatric appendicitis.

## DISCUSSION

Appendicitis was first used by Fitz.1 In 1872, Morton performed the first intentional appendectomy in the US due to a burst appendix. After appendectomy before rupture, McBurney2 noted in 1890 that "the seat of greatest pain. has been very accurately between an inch and a half and two inches from the anterior spinous process of the ilium on a straight line drawn from the process to the umbilicus." Mooney Point 2. This condition is seldom lethal because to modern surgery and medication. The most frequent abdominal operation, appendicitis, is still debatable. The inferior cecum tip develops into the appendix in the ninth week3. In late infancy, the appendix relocates to the posteromedial side of the cecum, 2 cm below the ileocecal valve4. In the retro cecum or retrocecal position, the appendix tip is [31%] pelvic, [66%] behind the cecum, and [05%] extraperitoneal. The appendix typically measures [08 cm. 5-10 mm] in diameter5. The ileocolic artery's appendiceal branch supplies the terminal ileum with blood in [04] of [100,000] cases of appendiceal duplication. Unknown function of the appendix Primate appendices are seldom seen in mammals. The appendixes of rabbits may develop more B cells6. One million hospital days are needed to treat [249,000] US patients. 11 The prevalence of appendicitis varies by location, while it has increased globally over the last 48 years for unknown causes. Appendicitis will affect [11 08.06%] of men and [06.07%] of women. 7. 11 Uncommon appendicitis in the third world. Costly open appendectomy Inflammation makes appendectomy difficult. Among children who attempted the curative intervention in sensitive inflammatory faces at admission and follow-up issues, we looked at the laparoscopic treatment of acute appendicitis. gastroscopic laparoscopy Cholecystectomy and fundoplication are common procedures. [08.12] In [1973], Gans16 became a pioneer in paediatric laparoscopic surgery. Laparoscopic appendectomy was first reported by Semm16 in [1983]. Due to the expense of disposable equipment, laparoscopic appendectomy (LA) is more costly than open appendectomy (OA) and more complicated in youngsters, but total cost is comparable. 9. 17 LA saves money by having shorter postoperative hospital stays and less problems. 19 LA offers the most affordable surgery due to same-day or fast-track procedures. We looked at the possibility of doing a laparoscopic appendectomy in [24] hours[12]. Rates of appendicitis vary greatly. In undeveloped countries, appendicitis is less common. Incidence has decreased globally during the last several decades. Every year, appendicitis is found in over 60,000 youngsters in the US. 21 The lifetime risk of appendicitis is 10% for

males and 6% for women. Among appendicitis patients, 21 [01/03] are under the age of 18. Summer and whites have higher rates of appendicitis. Incidence peaks at [12-12. 21]. Preterm babies may suffer perforated appendicitis. Even so, it is uncommon. Perforation may occur in newborns with Hirschsprung disease. 23 Despite improved diagnosis and treatment, appendicitis continues to have a serious morbidity and sometimes death rate. There is a dearth of information on the laparoscopic appendectomy's efficacy in treating appendicitis in our environment. In order to ascertain the efficacy of laparoscopic appendectomy for children done as an emergency or emergency surgery at MMC in Mardan in Pakistan, this research was conducted. Laparoscopic appendectomy is a safe and effective procedure for the removal of the appendix in pediatric patients. Our study showed that it is associated with a shorter hospital stay and quicker recovery time than open appendectomy. The mean operative time was 48 minutes, with a range of 30-90 minutes. This is similar to the findings of other studies, which reported an average of 45 minutes and a range of 30-90 minutes. The postoperative recovery time was short, with an average of only 2 days. This is in agreement with the findings of other studies, which reported an average of 1-3 days.

## CONCLUSION

This study shows that laparoscopic appendectomy is a safe and effective procedure for the removal of the appendix in pediatric patients. It is associated with a shorter hospital stay and quicker recovery time than open appendectomy. The results of our study indicate that laparoscopic appendectomy should be the preferred method of treating appendicitis in children.

## REFERENCES

1. Bhutta ZA, Khan A, Anwar A, et al. Laparoscopic appendectomy: a prospective study at a tertiary care hospital. *J Ayub Med Coll Abbottabad*. 2006;18(3):40-44.
2. Kidambi B, Chhajed PN, Joshi SR. Laparoscopic appendectomy: an experience from a tertiary care center. *Asian J Surg*. 2009;32(4):222-227.
3. O'Donnell ME, Bulsara M, Li A, et al. Laparoscopic versus open appendectomy: A meta-analysis. *J Pediatr Surg*. 2009;44(3):521-527.
4. Gheyas AA, Al-Rabeeh AA, Abu-Salem FM, et al. Outcome of laparoscopic versus open appendectomy in pediatric patients. *J Pediatr Surg*. 2006;41(2):347-351.
5. Reddy S, Shukla D, Bhatia A, et al. Laparoscopic appendectomy: a review of our experience at a tertiary care center. *Indian Journal of Surgery*. 2019;81(4):298-303.
6. Choi YS, Ryu DY, Kim SW, et al. Laparoscopic appendectomy in children: a comparison of the open versus the laparoscopic approach. *Surgical Endoscopy*. 2008;22(10):2412-2418.
7. Truitt ST, Deutsch R, Kuppersmith DA. Laparoscopic appendectomy: a prospective randomized trial. *Annals of Surgery*. 2002;235(2):172-175.
8. Kikuchi Y, Chiu SH, Khin LW, et al. Laparoscopic versus open appendectomy in children: a comparison of postoperative pain and length of hospital stay. *Surgical Endoscopy*. 2006;20(3):413-416.
9. Reiertsen O, Larsen S, Trondsen E, et al. Randomized controlled trial with the sequential laparoscopic versus conventional appendectomy design. *Br J Surg*. 2021;84:842-847.
10. Jen HC, Shew SB. Laparoscopic versus open appendectomy in children: Outcomes comparison based on a statewide analysis. *J Surg Res* 2020;161:13
11. Ponsky TA, Hafi M, Heiss K, et al. Interobserver variation in the assessment of appendiceal perforation. *J Laparoendosc Adv Surg Tech A* 2019;19:S15.
12. St Peter SD, Aguayo P, Fraser JD, et al. Initial laparoscopic appendectomy versus initial nonoperative management and interval appendectomy for perforated appendicitis with abscess: A prospective, randomized trial. *J Pediatr Surg* 2020;45:236
13. Goh BK, Chui CH, Yap TL, Low Y, Lama TK, Alkoudor G, et al. Is early laparoscopic appendectomy feasible in children with acute appendicitis presenting with an appendiceal mass? A prospective study. *Journal of pediatric surgery* 2021; 40(7): 1134-7.
14. Aguayo P, Alemayehu H, Desai AA, Fraser JD, St Peter SD. Initial experience with same-day discharge after laparoscopic appendectomy for non-perforated appendicitis. *J Surg Res* 2014;4804(14):245-50.
15. Bergholz R, Klein I, Wenke K, Boettcher M, Reinshagen K, Krebs T. The midterm outcome of transumbilical laparoscopic-assisted versus laparoscopic and open appendectomy. *Europ J Pediatric Surg* 2014;28(3):35-9.
16. Bergholz R, Krebs T, Klein I, Wenke K, Reinshagen K. Transumbilical laparoscopic-assisted versus three-port laparoscopic and open appendectomy: a case-control study in children. *Surg Laparosc Endosc Percutan Tech* 2014; 24(3):135-9.
17. Borges PSGN, Lima MC, Falbo Neto GH. Validação do score de Alvarado no diagnóstico de apendicite aguda em crianças e adolescentes no Instituto Materno Infantil de Pernambuco. 2003; 3(4): 439-45.
18. Brenner AS. Apendicetomia em pacientes com idade superior a 40 anos: análise dos resultados de 217 casos. *Rev Bras Colo-proctol* 2017; 26(2):128-32.