

ORIGINAL ARTICLE

Histological Pattern of Ovarian Tumor in Reproductive age group in a Tertiary Care HospitalNAILA QURESHI¹, FAHMIDA PARVEEN MEMON², AMBREEN MUGHAL³¹Consultant Gynaecologist in Obstetrics & Gynaecology Dept. Sayed Abdullah Shah Institute of Medical Health Sciences, Sehwan, Hyderabad²Associate Professor of Obstetrics & Gynecology Dept. Liaquat University of Medical and Health Sciences, Hyderabad³Senior Registrar of Obstetrics & Gynecology Dept. Liaquat University of Medical and Health Sciences, HyderabadCorrespondence to: Fahmida Parveen Memon, Email: dr_memon16@yahoo.com, Cell: 0332 3526836**ABSTRACT****Objectives:** To find out the frequency of histological pattern of ovarian tumor in reproductive age group in a tertiary care Hospital.**Study Design:** Cross sectional study. Place & duration of study: Department of Obstetrics & Gynecology, Liaquat University of medical and health sciences hospital, Hyderabad from October 2021 to September 2022.**Methodology:** All patients with ovarian tumor in reproductive age admitted during study periods were included in study. The diagnosis of ovarian tumors was suspected from clinical features and ultrasound findings and confirmed on histopathology. Data analysis was performed on SPSS version 24. Chi-Square test of significance (chi square test) was applied to see association among categorical variables. P value ≤ 0.05 was taken as significant.**Results:** Similarly pattern of ovarian tumors was as followed; such as cord stromal, germ cell and epithelial ovarian 50%, 33.96% and 16.04% respectively among 106 women. High incidence of sex cord and epithelial tumors was observed in older age (above 40 years) group 25% and 68.8% respectively but germ cell tumor was observed mostly in younger age group 92.6% in 21-30 years as compared to older age women and 6.3% in above 40 years.**Practical Implication:** Our research establishes the basis for future studies on ovarian tumor in Pakistan, allowing for better health policy decisions to be made based on this information.**Conclusion:** Histopathological examination shows that epithelial and germ cell tumors collectively constitute large number of cases specifically in older age. Histological examination in early stage of life is important therapeutically and prognostically.**Keywords:** Ovarian tumors, Malignancies, Histological pattern, Reproductive age, Parity**INTRODUCTION**

Ovarian tumors in females are common malignant entities worldwide in every age group¹. Among all types of gynecological cancers malignant ovarian cancers are raising challenges for gynecologists. It is also 2nd most reproductive malignancy in females having main tumors such as cord stromal, germ cell and epithelial ovarian². Clinical signs of this cancer cannot be easily identified³. Signs and symptoms include pain and abdominal swelling, gastrointestinal symptoms include urinary symptoms, weight loss, fatigue, back pain, lack of energy and abdominal pain⁴.

Ovaries also called pelvic organs situated on both sides of uterus anterior side of rectum and behind the broad ligament⁵. Posterior location to broad ligament and its relationship to fallopian tube confirm its laterality and ease the sampling and procedure of salpingo-oophorectomy⁶. Totipotent and multipotent nature of mesenchymal cells results in a wide range of neoplastic cell transformation. It is quite difficult to differentiate that lesion is neoplastic or non-neoplastic, but malignancies of ovary constitute 3rd common type of malignant cancers after cervical and endometrial⁷.

Ovarian cancer incidence increasing day by day worldwide and now it becomes fifth leading cause of deaths in women, about 50% cancers of genital tract⁸. Word "silent killer" is also in use because of its late diagnosis until in advance stage of disease. Approximately 2 lac women diagnosed with ovarian tumors every year and 1 lac deaths every year⁹. In Pakistani population unfortunately increasingly encountered disease. In a multi center study conducted in 1973 and supported by PMRC (Pakistan Medical Research Council) ovarian malignancy was observed 3.37%¹⁰.

Obvious symptoms were not observed in early stage of disease, usually women present with advance stage of disease where prognosis is not good although complex and intensive therapies are available^{11,12}. Lesions of benign or malignant nature can be diagnosed by bimanual examination, history taking, ultrasonography is ideal investigation that can give information about origin and consistency but final diagnostic test is tissue biopsy^{13,14}.

Since the day of histological diagnosis of ovarian tumors introduced no local study available yet, this stud will help in fulfilling local reference gap and also support the medical professionals in counseling the patients preoperatively with provision of good management plan.

METHODOLOGY**Study Seeting & Duration:** Study was conducted Obstetrics & Gynecology Department after permission from ethical committee of Liaquat University of medical and health sciences hospital, Hyderabad from October 2021 to September 2022.**Sample Size:** Sample size was calculated by using software with proportion of ovarian tumors 4.74%, power of study 80% and confidence interval 95%.**Inclusion Criteria:** Females of reproductive age 20-49 years presented at indoor or outdoor department having ovarian tumor presenting complaints like bloating, mass in abdomen, pelvic pain and swelling and discomfort, clinical confirmed adnexal mass that was confirmed on ultrasonography were included.**Exclusion Criteria:** Female above reproductive age (49 years), history of ovarian tumor surgery and refused to give written consent were excluded.**Methodology:** Written informed consent was taken after detail description of purpose of study. After ultrasonography biopsy was taken by a consultant gynecologist having minimum five years experience and case assisted by researcher himself. Biopsy sample was sent pathology laboratory for examination and findings were recorded. All information regarding clinical, radiological and histopathological were recorded.**Data Analysis:** Version 24 of SPSS was used for analyzing such as qualitative variables for frequencies as well as quantitative variables for mean (SD). Test of significance (t-test and chi square test were applied to see association among variables. Probability value ≤ 0.05 was taken as significant.**RESULTS**

A total of 106 patients were enrolled, mean age of patients and duration of symptoms was 34.57 ± 6.2 , 4.3 ± 1.06 respectively. Regarding age women were divided between age 21-30 years 27(25.47%), 31-40 years 63(59.43%) and > 40 years 16(15.09%).

Primiparous and multiparous women were 61(57.55%) and 45(42.45%) respectively. Similarly pattern of ovarian tumors was as followed; epithelial cell tumor 53 (50%), germ cell tumor 36 (33.96%), sex cord tumor 17 (16.04%) among 106 women.

High incidence of sex cord and epithelial tumors was observed in older age (above 40 years) group 4 (25%) and 11 (68.8%) respectively but germ cell tumor was observed mostly in younger age group 25 (92.6%) in 21-30 years as compared to older age women and 1 (6.3%) in above 40 years. Similarly epithelial cell tumor was observed mostly in multiparous women 32(71.1%) and germ cell tumor was observed in primiparous women 28(45.9%).

Ovarian tumor rates were compared amongst women with varied parities (defined as a difference in the number of children each woman has had). The highest rates of benign and malignant ovarian tumors, Epithelial cell tumor (34.4% vs. 71.1%), Germ cell tumor, (45.9% vs. 17.8%), sx cord-stromal tumor (19.7% vs. 11.1%) were observed in women with primiparous and multiparous respectively as shown in table 3.

Table-1: Demographics, parity and histopathological pattern

Characteristics	Frequency (percentage)/Mean (SD)
Age	34.57 ± 6.2
Duration of disease	4.3 ± 1.06
Parity	
Primiparous	61 (57.55%)
Multiparous	45 (42.45%)
Histological pattern of ovarian tumor	
Epithelial cell tumor	53 (50%)
Germ cell tumor	36 (33.96%)
Sex cord tumor	17 (16.04%)

Table-2: Histopathologic pattern and age of patients

Histological pattern of ovarian tumor	Age Groups (Years)			P values
	21 to 30 Years n=27	31 to 40 Years n=63	>40 Years n=16	
Epithelial cell tumor	2(7.4%)	40(63.5%)	11(68.8%)	0.0005
Germ cell tumor	25(92.6%)	10(15.9%)	1(6.3%)	0.0005
Sex cord-stromal tumor	0(0%)	23(20.6%)	4(25%)	0.029

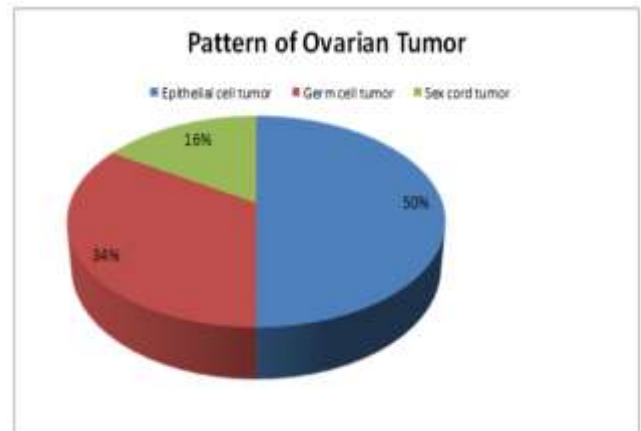


Figure 1: The distribution of all ovarian cancers according to kind

Table-3: Histopathological pattern and parity

Histological pattern of ovarian tumor	Primiparous n=61	Multiparous n=45	P-Value
Epithelial cell tumor	21(34.4%)	32(71.1%)	0.0005
Germ cell tumor	28(45.9%)	8(17.8%)	0.003
Sex cord-stromal tumor	12(19.7%)	5(11.1%)	0.23

Table-4: Histopathological pattern and duration of symptoms

Histological pattern of ovarian tumor	Duration of complain (months)		P-Value
	≤4 months n=64	>4 months n=42	
Epithelial cell tumor	33(51.6%)	20(47.6%)	0.69
Germ cell tumor	26(40.6%)	10(23.8%)	0.07
Sex cord-stromal tumor	5(7.8%)	12(28.6%)	0.004

DISCUSSION

Malignant ovarian cancer is a leading cause of mortality from gynecological malignancies in reproductive age¹⁵. A wide variety of neoplasm like connective tissue, epithelial tissue and wide variety of embryonic and germinal cells are involved that can be diagnosed on histopathological examination. Its diagnosis is also difficult because of pathologic condition variations that may present with similar manifestations clinically and radiologically, but a good knowledge of age specific morphology can ease the diagnosis¹⁶.

In our study mostly patients having age above 40 years, Mondal et al¹⁷ conducted a study on 957 women with ovarian tumors and reported median age 35 years but malignancy was observed in women with age above 40 years. Another study by Jha et al¹⁸ have reported similar findings that 47.2% ovarian tumors diagnosed in women with age 20-40 years but malignant ovarian tumors diagnosed in above 40 years 73.1% population.

In an Iranian study by Gilani et al¹⁹ reported median age of patients 49 years who were having malignant lesions and epithelial cell lesions observed in 67.1%, of cases, germ cell and cord lesions were observed as 17.1% and 9.2% respectively. Murthy et al²⁰ shows similar findings in Indian population that older age is more prone for malignant ovarian cancer and efforts should be made to diagnose it in early stage of life.

Histologically heterogeneity was observed in ovarian tumors, classification of these tumors by World Health Organization also made on basis their heterogenesis²¹. Just like our study Shy et al²² was also reported similar findings that surface epithelial lesions are commonest observed in 48.8% of women, but in another study by Di et al²³ reported much higher incidence of surface epithelial tumors 63.5%.

In our study 2nd most common tumor is germ cell tumor that was observed in 33.96% of women and cord or stromal cell tumors were observed in 16.04% population. Lancaster et al²⁴ reported germ cell tumors constitute 29.3% of total ovarian tumors; similarly Lucas et al²⁵ reported 45% germ cell tumors followed by 17% cord or stromal cell tumors.

In a Pakistani study Arshad et al²⁶ reported similar findings that benign tumors mostly found in younger and reproductive age, 47.2% tumors observe in 20-40 years of age but malignancy was observed in older age (above 40 years) as 73.1% cases observed. A very close observation was reported by Khan et al²⁷ and shown 76% benign ovarian tumors, among malignant cases surface epithelial tumors were most common with 34.78% proportion.

The researcher knows this to be the first study of its kind to be carried out in Pakistan. Research in Pakistan is in its infancy because of decades of constant war, but its authors are optimistic that their latest study may pave the way for future large-scale investigations of ovarian cancers.

Despite these benefits, the present study's generalizability is limited because it was conducted in a private tertiary care hospital setting and relied on extrapolation to draw conclusions. In addition, many instances were left out of the study due to a lack of immunohistochemistry stains, which could have impacted the study's internal validity.

CONCLUSION

Histopathological examination shows that epithelial and germ cell tumors collectively constitute large number of cases specifically in older age. Ovarian tumors are enormous clinical challenge for gynecologist, radiotherapists and oncologists, on physical examination and laboratory investigation it is much difficult to diagnose. Histological examination in early stage of life is important therapeutically and prognostically.

REFERENCES

1. Upreti P, Reddy GT. A retrospective observational study of clinicopathological spectrum of ovarian tumors. Indian Journal of OBGYN. 2021;7(2):157-62.
2. Iversen L, Fielding S, Lidegaard O, Mørch LS, Skovlund CW, Hannaford PC. Association between contemporary hormonal

- contraception and ovarian cancer in women of reproductive age in Denmark: prospective, nationwide cohort study. *bmj*. 2018;362:p3609
3. Matsuo K, Machida H, Blake EA, Holman LL, Rimel BJ, Roman LD et al. Trends and outcomes of women with synchronous endometrial and ovarian cancer. *Oncotarget*. 2018 Jun 6;9(47):28757.
 4. Iftikhar F, Anum H, Iftikhar N, Ijaz A, Gul N. Histological pattern of ovarian neoplasms and their age wise distribution-study conducted At A Tertiary Care Hospital. *Journal of Rawalpindi Medical College*. 2018;22(S-2):73-6.
 5. Ibrahimkhal AS, Malakzai HA, Haidary AM, Hussaini N, Abdul-Ghfar J. Pathological Features of Ovarian Tumors, Diagnosed at a Tertiary Care Hospital in Afghanistan: A Cross-sectional Study. *Cancer Management and Research*. 2022 Jan 1;3325-33.
 6. Iftikhar F, Anum H, Iftikhar N, Ijaz A, Gul N. Histological pattern of ovarian neoplasms and their age wise distribution-study conducted at a tertiary care hospital. *J Rawalpindi Med Coll*. 2018;22(S-2):73-76.
 7. Chandra K, Arora N. Clinicopathological analysis of ovarian tumors: a two year retrospective study. *Int J Reprod Contracept Obstetr Gynecol*. 2019;8(8):3016.
 8. Bray F, Ferlay J, Soerjomataram I, Siegel R, Torre L, Jemal A. Erratum: global cancer statistics 2018: GLOBOCAN estimates of incidence and mortality worldwide for 36 cancers in 185 countries. *CA Cancer J Clin*. 2020;70(4):313.
 9. Siegel RL, Miller KD, Jemal A. Cancer statistics, 2019. *CA Cancer J Clin*. 2019;69(1):7-34. doi:10.3322/caac.21551
 10. Jafarey NA, Zaidi SH. Cancer in Pakistan. *JPMA*. 1987;(Special Communication):178-83.
 11. Itha MB, Veeragandham S. Study of histopathological spectrum of ovarian neoplasms: An experience at a tertiary care hospital. *Int J Clin Diagn Pathol*. 2019;2:408-13.
 12. Mukhiya G, Sharma N, Savalia KA. Ovarian Neoplasms: Clinicopathological Spectrum in Tribal Rajasthan, India. *Journal of Clinical & Diagnostic Research*. 2021;15(7):13-18.
 13. Ranjoalkar AP, Sharma S, Valiathan M, Pai K, Pai M, Bakkannavar SM. Histopathological Spectrum of Ovarian Tumors: A 3-Year Retrospective Study in a Tertiary Care Centre in Southern India. *Call for Editorial Board Members*. 2020;13(1):19-25.
 14. Mallika B, Chakravarthy VK, Rao DR. Histopathological study of ovarian tumours. *Journal of Evolution of Medical and Dental Sciences*. 2019;8(9):551-5.
 15. Suleiman AY, Pity IS, Mohammed MR, Hassawi BA. Histopathological patterns of ovarian lesions: a study of 161 cases. *Biocell*. 2019;43(3):175. doi:10.32604/biocell.2019.06884
 16. Yousif HM, Mohammed RA, Missawi HM, Elsawaf ZM, Albasri AM. Histopathological patterns of primary malignant ovarian neoplasms in different age groups in Al Madinah Almunawwarah region, KSA. *J Taibah Univ Med Sci*. 2019;14(1):73-78. doi:10.1016/j.jtumed.2018.11.005
 17. Mondal SK, Banyopadhyay R, Nag DR, Roychowdhury S, Mondal PK, Sinha SK. Histologic pattern, bilaterality and clinical evaluation of 957 ovarian neoplasms: a 10-year study in a tertiary hospital of eastern India. *J Can Res Ther*. 2011;7:433-7.
 18. Jha R, Karki S. Histological pattern of ovarian tumors and their age distribution. *Nepal Med Coll J*. 2008;10:81-5.
 19. Gilani MM, Behnamfar F, Zamani F, Zamani N. Frequency of different types ovarian cancer in Vali-e-Asr Hospital (Tehran University of Medical Sciences) 2001-2003. *Pak J Biol Sci*. 2007;10:3026-8.
 20. Murthy NS, Shalini S, Suman G, Pruthvish S, Mathew A. Changing trends in incidence of ovarian cancer - the Indian scenario. *Asian Pac J Cancer Prev*. 2009;10:1025-30.
 21. Tavassoli FA, Devilee P, editors. *Pathology and genetics of tumors of the breast and female genital tracts*. Lyon: IARC Press; 2003. p114.
 22. Shy Y. Histological classification in 10,288 cases of ovarian malignant tumors in China. *Zhinghua Fu Chan Ke Za Zhi*. 2002 Feb;37(2):97-100.
 23. Di Bonito L, Patriarca S, Delendi M, Alberico S. Ovarian tumours: anatomohistopathological contribution to their interpretation. *Eur J Gynaecol Oncol*. 1988;9(4):324-30.
 24. Lancaster EJ, Muthuphei MN. Ovarian tumours in Africans: a study of 512 cases. *Cent Afr J Med*. 1995;41:245-8.
 25. Lucas SB, Vella EJ. Ovarian tumors in Malawi - a histopathological study. *J Obstet Gynaecol East Cent Africa*. 1983 Sep;2(3):97-101.
 26. Arshad M, Niazi S. Frequency and histological spectrum of malignant ovarian tumors at King Edward Medical University, Lahore. *Biomedica* 2015; 31: 269-76.
 27. Khan AA, Luqman M, Jamal S, Mamoon N, Mushtaq S. Clinicopathological analysis of Ovaria tumors. *Pak J Pathol* 2005; 16:28-32.