

ORIGINAL ARTICLE

Evaluate the Results of Closed Interlocking Nail Shaft of Femur Vs. Open Interlocking NailSHAMS UR REHMAN¹, SYED BAKHT SARDAR², KAMRAN SAEED³, RAZA ASKARI⁴, FAZL UR RAHMAN SAEED⁵, IRFAN ALI⁶¹Assistant professor Orthopaedic, MTI Lady Reading Hospital Peshawar²Registrar, Department of Orthopaedic, Khyber Teaching Hospital Peshawar³Associate Professor Orthopaedic, Sialkot Medical College Sialkot Pakistan⁴Assistant Professor Orthopaedic, Dow International Medical College, Dow University of Health Sciences⁵Assistant Professor, Department of Rehabilitation Medicine, PNS Shifa Hospital Karachi⁶Trainee Medical Officer, Surgical B ward, MTI-Mardan Medical Complex, MardanCorresponding author: Syed Bakht Sardar, Email: Dr.sb_s@yahoo.com**ABSTRACT****Objective:** The purpose of this research is to evaluate the efficacy of closed versus open interlocking nails in treating femur shaft fractures.**Study Design:** Retrospective cohort study**Place and Duration:** This Retrospective cohort study was conducted at MTI Lady Reading Hospital Peshawar and Khyber Teaching Hospital Peshawar in the duration from 1st March, 2022 to 31 August, 2022.**Methods:** This research involved 108 cases with age 20-72-year had femoral shaft fracture were included. After informed written consent, age, sex, body mass index, and fracture reason were computed. Patients were equally divided in two groups. Group I utilized open interlocking nails, whereas group II used closed. Post-operative radiological and surgical results were evaluated for union, non-union, and delayed union. Calculated infection prevalence for both groups. Flynn's criterion assessed functional results. SPSS 24.0 analyzed all data.**Results:** In group I operation time was higher as compared to group II with p value <0.004. Closed group union time was 17.3±6.51 weeks compared to open group 27.8±6.20 weeks. Group II had 51 (94.4%) unions, whereas group I had 45 (83.3%). Group I had 12 (22.2%) delayed unions while group II had 5 (9.3%). Closed interlocking nail performed better than open approach with p value <0.03. The closed interlocking group had fewer complications as compared to open approach (p <0.02).**Conclusion:** This study found that closed interlocking nails for the femur shaft were superior to open interlocking nails in terms of radiographic and functional success. In addition, patients who were given a closed interlocking nail experienced less complications after surgery.**Keywords:** Surgery, Femur Shaft, Complications, Closed/Open interlocking nail, Functional Outcomes**INTRODUCTION**

Shaft of femur fractures are among the most frequent in orthopaedic practise. The femur is the largest and heaviest load-bearing bone in the lower extremities. High-energy trauma, such as that caused by a car crash, a fall from a great height, an accident between an automobile and a pedestrian, or a gunshot wound, frequently leads to femoral shaft fractures, which may be accompanied by other injuries. The substantial morbidity and mortality associated with femoral shaft fractures [3, 4] emphasises the importance of prompt diagnosis and individualised treatment. Non-surgical care has given way to the most recent operational technique for treating femoral shaft fractures, as discussed in [4]. Fractures to the femur's shaft can be treated using a variety of methods. Our treatment options include [5] closed reduction, spica cast immobilisation, skeletal traction, femoral cast bracing, external fixation, internal fixation with plating, and un-reamed/reamed intramedullary interlocking nail. For femur shaft fractures in 1940, [5]

Kuntscher, the pioneer of intramedullary nailing, used closed cloverleaf nailing; [6] however, there were many reports of complications, including excessive radiation exposure, nail jamming, distal fragment splitting, and a failure to accurately reduce the fracture. Because of this, in 1950, Watson proposed open reduction and nailing of femoral shaft fractures. Nevertheless, the development of sophisticated image intensifier machines and Kuntscher's Detensor interlocking nail technology in 1968 widely popularised the closed interlocking nail, reducing radiation risks substantially. The benefits of closed intra medullary nailing include [9] the preservation of soft tissue envelope, the deposition of intramedullary bone grafts owing to reaming, and the preservation of fracture hematoma with osteogenic qualities. [10]

The success and quality of fracture healing of the femur treated with static and dynamic intramedullary osteosynthesis are ensured by the low incidence of infection, high stability and strength of fragments union, and the opportunity of early mobilization while conserving soft structure and peripheral circulation. [11,12] At our clinic, femoral shaft fractures are treated

using interlocking Nails. Unfortunately, the mechanism of locking of the interlocking nail is left to the discretion of the surgeon due to a lack of local clinical data and standard protocol. Our research will aid us in developing a department-wide uniform procedure for interlocking nails. In addition, the patient's weight-bearing, rehabilitation, and ability to return to work after surgery are all affected by the mechanism of locking.

The purpose of our study was to evaluate the union, nonunion, and infection rates of femur fracture shaft fractures treated with closed versus open interlocking nails.

MATERIAL AND METHODS

This Retrospective cohort study was conducted at MTI Lady Reading Hospital Peshawar and Khyber Teaching Hospital Peshawar in the duration of 1st March, 2022 to 31 August, 2022 and comprised of 105 patients. Patients age, sex, bod mass index and cause of fracture was calculated after taking informed written consent. Patients who did not give written consent, were younger than 20 years old, had a serious medical condition (such as kidney failure, cardiovascular disease, poly-trauma, multiple fractures, segmental fractures, bilateral femoral fractures, floating knee patients, pathological fractures), or had a complication (such as infection) prevented them from participating in the study.

The ages of the patients ranged from 20 to 72. All of the patients who qualified were randomly assigned to one of two groups. The open interlocking nail method was employed on the group O participants, whereas the closed interlocking nail method was used on the group P participants. Using radiology, Winquist and Hansen classified fractures into proximal, mid, and distal thirds. 16 Medical records were determined to be consistent with regards to the postoperative antibiotics, follow-up care, and rehabilitation therapy given to each patient. All of the surgeries were performed with the patients under general or spinal anaesthesia on a traction table, and an image intensifier was used to keep an eye on them throughout. Depending on the location and severity of the comminution of the fracture, an antegrade interlocking nail was either statically or dynamically secured into

the piriformis fossa. The fracture was either opened up close to the time of the interlocking nail procedure or after the guide wire had failed to pass through the fracture. On the first postoperative day, patients underwent isometric quadriceps exercises before beginning partial or full weight-bearing, which was determined by each patient's unique fracture pattern, method of dynamization, and degree of callus development. Surgery length, average union time, delayed union (inadequate callus at 14 weeks post operatively), dynamization, fracture union, and complications were all compared and contrasted between the two groups at one year post-surgery.

All of the data was analysed using SPSS 24.0. Statistical significance was determined using the Chi-square test, and a p value of 0.05 was employed. The usefulness of the results was measured using Flynn's criterion.

RESULTS

Comparing the ages of the two groups, there was no discernible difference. Sixty-five (60.2%) of the participants were male, whereas just forty-three (39.8%) were female. The most prevalent cause was a high-impact collision, followed by road traffic accidents and falls. In group I operation time was higher as compared to group II with p value <0.004.(table 1)

Table 1: Information characteristics and surgery time

Variables	Group I	Group II
Mean age (years)	27.2±10.66	27.5±6.39
Gender		
Male	33 (30.6%)	32 (29.6%)
Female	21 (19.4%)	22 (2.4%)
Cause of fracture		
collision	25 (23.1%)	28 (25.9%)
RTA	15 (13.9%)	16 (14.8%)
falling	14 (12.96%)	10 (9.3%)
Surgery Time (minutes)	90.16±8.56	60.7±13.88

Closed group union time was 17.3±6.51 weeks compared to open group 27.8±6.20 weeks. Group II had 51 (94.4%) unions, whereas group I had 45 (83.3%). Group I had 12 (22.2%) delayed unions while group II had 5 (9.3%).(table 2)

Table 2: The results of the operations on both groups after they were completed

Variables	Group I	Group II
Mean Union time (weeks)	27.8±6.20	17.3±6.51
Radiological Outcomes		
Union	45 (83.3%)	51 (94.4%)
Delayed Union	12 (22.2%)	5 (9.3%)
Non-Union	9 (16.7%)	3 (5.6%)

Flynn's criterion indicated that the closed interlocking nail technique was superior to the open technique, with a p-value < 0.05 indicating excellent or good results.(figure 1)

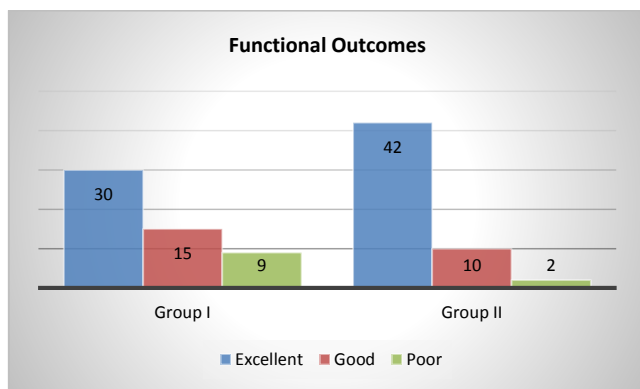


Figure 1: Comparison of functional outcomes among both groups

With a p value of less than 0.05, the rate of complications was also minimum in the closed group.(figure 2)

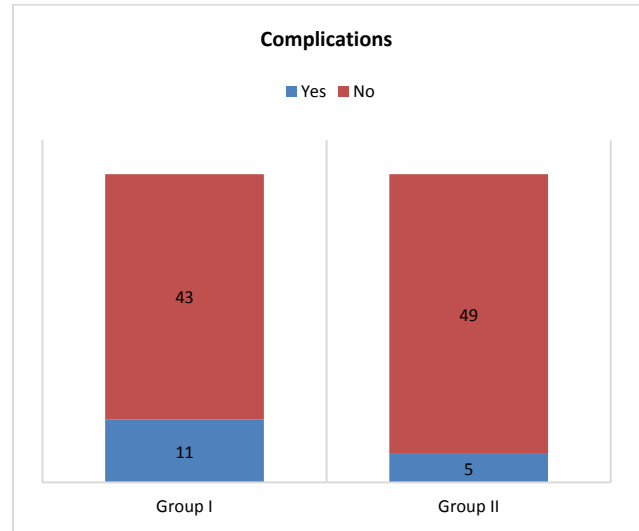


Figure 2: Analyzing postoperative complications in both groups

DISCUSSION

Common situations in which the femoral shaft is broken include motor vehicle accidents, automobile-pedestrian collisions, gunshot wounds, falls from extreme heights, and aeroplane crashes. They are common in people who have been hurt repeatedly, and can be fatal in some situations. The treatment aims to keep the patient's hip and knee in their normal, functioning range of motion while also facilitating the patient's capacity to achieve union on a continuing basis. It is recommended that the patient's hip and knee flexion range be at least 160 degrees for safe stair climbing.[13,14]

In the duration of our research, the majority of the patients were male, totaling 65 (60.2%), while only 43 (39.8%) were female. There was not any significant difference at all between the two groups in regard to their ages 27 years. The high impact of the accident was the most prevalent cause, followed by the RTA fall as the second most common cause. Our findings were on line with those of the research done in years gone by.[15,16] In group I operation time was higher as compared to group II with p value <0.004. Closed group union time was 17.3±6.51 weeks compared to open group 27.8±6.20 weeks. The comparatively long period of time needed for healing in our study's group that received open nailing is in line with the findings of prior research in the field.[17]

Twenty-three patients were treated with closed nailing and 24 patients were treated with open nailing by Tahririr [15], who only made a little incision (2.5cm) at the fracture site for each. Union times averaged 132.4 seconds for closed-nailing, and 17.72.3 seconds while open-nailing (P value 0.001). The only issue in the open nailing group was that one patient did not union. Researchers found that even in the absence of a fracture table or an image intensifier, open nailing through a small incision was effective in treating patients with multiple injuries. Unfortunately, our investigation did not allow us to identify the size of the incision at the fracture site; so, we assumed that a long enough incision was used for fracture reduction and guide wire transit.[15,16]

Comparing 57 femurs fixed with closed interlocking nails to 49 femurs fixed with open nails, Seetharmaiah et al. [18] found that the average radiological union time was 22.6 weeks in closed nailing and 24.21 weeks in open nailing, with shortening occurring in 7(12.2%) patients in closed nailing and 5(10.2%) patients in open nailing. Using Thoreson's criteria, the researchers observed that functional results following closed nailing were outstanding in 68.4 percent of patients, good in 24.5%, and fair in 7. There was a significant improvement in function after open nailing in 55.1% of

patients, a substantial improvement in function in 28.5%, and a moderate improvement in function in 16.3%.

In our study Group II had 51 (94.4%) unions, whereas group I had 45 (83.3%). Group I had 12 (22.2%) delayed unions while group II had 5 (9.3%) Flynn's criterion indicated that the closed interlocking nail technique was superior to the open technique, with a p-value < 0.05 indicating excellent or good results. In contrast to the abundance of studies comparing closed versus open methods, the literature study provides few information on the former. Although open and closed nailing each have their advantages, Rokkanen et al. [19] argue that closed nailing yields somewhat better results overall. In 42 cases of femoral fractures, Rascher et al. found that closed intramedullary fixation brought back normal anatomy [20]. Leighton, on the other hand, conducted a follow-up study after two years to evaluate the relative merits of open and closed nailing methods. He found no statistically significant difference in clinical outcomes between patients who employed a closed procedure and those who utilized an open approach [21]. Except this complications were also seen minimum in closed interlocking nail group.[22]

CONCLUSION

This study found that closed interlocking nails for the femur shaft were superior to open interlocking nails in terms of radiographic and functional success. In addition, patients who were given a closed interlocking nail experienced less complications after surgery.

REFERENCES

- 1 Ali MA, Hussain SA, Khan MS. Evaluation of results of interlocking nails in femur fractures due to high velocity gunshot injuries. *J Ayub Med Coll Abbottabad*. 2008;20 (1):16-9. PMID:19024178.
- 2 Kimmatkar N, Hemnani JT, Hemnani T, Jain S. Diaphyseal femoral intramedullary nailing: closed or open intervention. *International Journal of Scientific Study*. 2014;1(5):15-8.
- 3 Afsar SS, Gulzar M, Babar IU. A one year review of various complications in fracture shaft of femur managed with closed intramedullary interlocking nail. *Journal of Postgraduate Medical Institute (Peshawar-Pakistan)*. 2013;27(3):336-41.
- 4 Mirza A, Ellis T. Initial management of pelvic and femoral fractures in the multiply injured patient. *Critical care clinics*. 2004;20(1):159-70. DOI: 10.1016/S0749-0704(03) 00096-4.
- 5 Naeem-Ur-Razaq M, Qasim M, Khan MA, Sahibzada AS, Sultan S. Management Outcome OF Closed Femoral Shaft Fractures by Open Surgical Implant Generation Network (SIGN) Interlocking Nails. *J Ayub Med Coll Abbottabad*. 2009;21(1):21-4. PMID:20364733.
- 6 Kuntscher G, Marknag D. Nailing of femoral fractures. *Clin Ortho*.1940; 200:400-403.

- 7 Street DM. The Evolution of intramedullary nailing. In *The science and practice of intramedullary nailing*.1st edition.Philadelphia. Mosby. 1987;1-15.
- 8 Watson Jones R. Medullary nailing of fractures after fifty years. *J Bone Joint Surg*. 1950; 32(B):694-700
- 9 Kuntscher G. The Detensor nail forfracture shaft of femur. *Clin Ortho*. 1968; 75:143-150
- 10 Tahririan MA, Andalib A. Is there a place for open intramedullary nailing in femoral shaft fractures?. *Adv Biomed Res*.2014;3:157-16
- 11 Khan IA, Ahmad S, Shah MA, Ahmad S, Shafiq M, Shafaq SA. Static versus dynamic interlocking intramedullary nailing in fractures shaft of femur. *Gomal J Med Sci* 2015; 13:104-108.
- 12 Robinson CM, Adams CI, Craig M, Doward W, Clarke MC ,Auld J. Implant-Related Fractures of the Femur Following Hip Fracture Surgery. *J Bone Joint Surg [Am]* 2002;84:1116- 22.
- 13 Jhunjunwala HR, Dhawale AA. Is augmentation plating an effective treatment for non-union of femoral shaft fractures with nail in situ? *European Journal of Trauma and Emergency Surgery*. 2016 ; 42(3):339-43.
- 14 Grubor P, Krupic F, Biscevic M, Grubor M. Contraversies in Treatment of Acetabular Fracture. *Med Arch* 2015; 69(1):16–20.
- 15 Tahririan MA, Andalib A. Is there a place for open intramedullary nailing in femoral shaft fractures?. *Adv Biomed Res*.2014;3:157-162
- 16 Haq SN, Abidi SA, Jalil SA, Ahmed SA, Tunio ZH, UmerMF,et al.Comparison of Closed Versus Open Interlocking Nail Femur: A Retrospective Cohort Study in a Tertiary Care Hospital.*J Pak Orthop Assoc*. 2020;32(3)
- 17 O'Toole RV, O'Brien M, Scalea TM, Habashi N, Pollak AN, Turen CH.Resuscitation before stabilization of femoral fractures limits AcuteRespiratory Distress Syndrome in patients with multiple traumaticinjuries despite low use of Damage Control Orthopedics. *Journal ofTrauma-Injury Infection and Critical Care*. 2009;67(5):1013-1021
- 18 SeetharamaiahVB, BasavarajannaS, Mahendra AR, VivekanandaswamyAN. Comparison of Closed and Open Interlocking Nailing Techniques In Femoral Shaft Fractures. *J of Evidence Based Med & Hlthcare*.2015;2(49):8514-8518.
- 19 Closed or open intramedullary nailing of femoral shaft fractures? a comparison with conservatively treated cases. Rokkanen P, Slätis P, Vanka E. <https://pubmed.ncbi.nlm.nih.gov/5770411/>
- 20 Closed nailing of femoral shaft fractures. Rascher J, Nahigian SH, Macys JR, Brown JE. https://journals.lww.com/jbjsjournal/abstract/1972/54030/closed_nailin_g_of_femoral_shaft_fractures.6.aspx.
- 21 Open versus closed intramedullary nailing of femoral shaft fractures. Leighton RK, Waddell JP, Kellam JF, Orrell KG. *J Trauma*
- 22 Thoresen B, Alho A, Ekeland A, Strømsøe K, Follerås G, Haukebø A. Interlocking intramedullary nailing in femoral shaft fractures. A report of forty-eight cases. *JBJS Case Connector*. 1985(9):1313-20