

ORIGINAL ARTICLE

Efficacy and Safety of Suprachoroidal Triamcinolone Acetonide in Cases of Resistant Diabetic Macular EdemaYASIR AHMAD¹, SAUD UL HASSAN MEMON², SHAHID ANWAR BHATTI³, FAISAL NAWAZ⁴, WALEED AHMAD⁵, MARIA SALEEM⁶¹FCPS Ophthalmology, Senior Registrar, Alshifa Trust Eye Hospital, Rawalpindi²Ophthalmologist, Sindh Institute of Ophthalmology and Visual Science(SIOVS), Hyderabad³Associate Professor of Eye Sahara Medical College, Narowal⁴Assistant Professor, Ophthalmology, Vitreo Retina, Peshawar Medical College and Allied hospitals, Peshawar⁵Registrar Ophthalmology, Al Shifa Trust Eye Hospital, Rawalpindi⁶Senior Registrar, Classified Eye Specialist, PAF Hospital/ Fazaia Medical College, IslamabadCorresponding Author: Dr. Saud Ul Hassan Memon, Email:- saudmemon_1987@yahoo.com**ABSTRACT****Background and Aim:** Patients with diabetes are at risk of losing their vision due to diabetic macular edema (DME). Symptoms of diabetic macular edema occur as fluid leaks from retinal vessels into the surrounding neural retina due to hypoglycemia-induced damage to the blood-retina barrier. The current study aimed to assess the safety and efficacy of suprachoroidal triamcinolone acetonide in resistant diabetic macular edema cases.**Patients and Methods:** This interventional case series was carried out on 32 diabetic macular edema cases in the Department of Ophthalmology, Hayatabad Medical Complex, Peshawar during the period from April 2019 to September 2019. All the patients above 16 years of age with Type-1 DM or Type-2 DM were enrolled in this study. Intraocular Pressure (IOP), Baseline Best Corrected Visual Acuity (BCVA), and Central Subfield Thickness (CST) were determined and recorded. Post-SCTA follow-up was done in one and three months. During follow-up, the measured clinical factors were noted and analyzed in SPSS version 26.**Results:** Of the total 32 diabetic macular edema cases, 15 (46.9%) were male and 17 (53.1%) were females. The overall mean age was 48.64 ± 8.72 years. The frequency of prior injections received were 6.2 with maximum 12 and minimum four. CST pre-injection mean value was 612.8 ± 198.3 μ m and CST post-injection mean value at one and three months was 308.6 ± 62.6 μ m and 302.72 ± 58.64 μ m respectively. Statistical significance was found in pre and post one-month CST injections. The BCVA pre-injection and post-injection mean value at one and three months was 0.8 ± 0.19 and 0.49 ± 0.29 and 0.39 ± 0.20 respectively. At the one and three months post injection, there was statistical significance for both pre and post injection CST. A mean IOP of 12.32 mmHg was recorded pre-injection. Previously, 14.82 mmHg and 14.48 mmHg of intraocular pressure were recorded respectively after one and three months of injection.**Conclusion:** The present study found that Triamcinolone Acetonide (TA) was administered for anatomical and functional improvement. OCT macular thickness can be improved and refractory diabetic macular edema can be reduced using SCT.**Keywords:** Resistant diabetic macular edema, Efficacy, Suprachoroidal Triamcinolone**INTRODUCTION**

Diabetic macular edema (DME) is the leading cause of peripheral vision loss in diabetics with diabetic retinopathy. The foundation of DME management has shifted significantly since a few years back [1]. Previously, laser was the cornerstone of DME management, but three key anti vascular endothelial growth factor (anti-VEGF) medications are now available, including ranibizumab, aflibercept, and bevacizumab [2]. Despite their widespread usage in DME, some individuals do not respond to this form of treatment [3]. Inflammatory conditions, such as macular edema and decreased vision, have been treated with triamcinolone acetonide (TA) for decades [4]. Anti-VEGF medications expenses and poor prognosis, intravitreal injection of TA (IVTA) can be utilized as an alternate strategy in situations of anti-VEGF drug resistance, although the primary downsides of IVTA in DME care were secondary glaucoma and cataract development [5]. Intravitreal Triamcinolone Acetonide (IVTA) has long been used as an alternate treatment for instances that do not respond to anti-VEGF drugs or when compliance is an issue. Despite the direct impact of IVTA in reversing DME and restoring the retinal barrier of damaged blood, its usage has been hampered by a number of undesirable side effects. The requirement for recurrent injections owing to the diminishing impact of IVTA and reverberation of macular edema is the most noticeable. Its usage also causes increased intraocular pressure (IOP) and cataract development [6].

In order to reduce the intravitreal steroids adverse effects, there has recently been an increasing trend in exploring suprachoroidal space for medication administration. Steroid delivery through suprachoroidal route to posterior segment, investigators considered the risk-benefit ratio, taking into account the intervention level, concertation of anterior and posterior segment, and incidence of drug delivered [7]. Other studies have confirmed the suprachoroidal route safety and efficacy in terms of

medication administration [8, 9]. Corticosteroids can also be used as a stand-alone treatment for eyes that are not suitable for anti-VEGF therapy or that were only partially receptive to earlier anti-VEGF therapy [10]. Intravitreal Triamcinolone Acetonide (IVTA) has long been used as an alternate medication in circumstances where anti-VEGF medicines have not been effective or when compliance has been a concern. Its usage is also associated with increased intraocular pressure (IOP) and cataract development [11]. The present study aimed to assess the efficacy and safety of suprachoroidal triamcinolone acetonide in diabetic macular edema cases.

METHODOLOGY

This interventional case series was carried out on 32 diabetic macular edema cases in the Department of Ophthalmology, Hayatabad Medical Complex, Peshawar during the period from April 2019 to September 2019. All the patients above 16 years of age with Type-1 DM or Type-2 DM were enrolled in this study. Non-randomized sampling technique was used for patient's selection. Intraocular Pressure (IOP), Baseline Best Corrected Visual Acuity (BCVA), and Central Subfield Thickness (CST) were determined and recorded. Post-SCTA follow-up was done in one and three months. During follow-up, the measured clinical parameters were recorded again. It excluded patients with macular edema, severe macular ischemia, cataract, uveitis, and ocular hypertension due to any other cause, high IOP, history of prior intraocular surgery, or treatment naive DME. Patients who had previously had periocular or intravitreal triamcinolone acetonide therapy during the preceding 6 months, as well as prior anti-VEGF medication within the previous 90 days, were also excluded. Any patient with IOP more than 21 mmHg, history of prior intraocular surgery, or treatment naive individuals with DME, uveitis, ocular

hypertension, cataract, or macular ischemia (confirmed on fundus fluorescein angiography) were excluded from this trial.

Identification of treatment resistance was done in cases where DME failed to anti-VEGF treatment during follow-up for one month. Central Subfield Thickness (CST), Spectral Domain Optical Coherence Tomography, and BCVA were used for determination of the reactant failure. During the initial stage of assessment, patients underwent complete ocular examination such as examination of anterior/posterior segment and IOP measurement. After injection, patients were followed-up for three months. CST, BCVA, and IOP were recorded during each follow-up. Variation in CST and BCVA were the main outcomes measured. SPSS version 26 was used for data analysis. For regularly distributed data, the paired t-test was employed. Statistical significance was defined as a p-value of 0.05.

RESULTS

Of the total 32 diabetic macular edema cases, 15 (46.9%) were male and 17 (53.1%) were females. The overall mean age was 48.64 ± 8.72 years. The frequency of prior injections received were 6.2 with a range of 4-12. CST pre-injection mean value was 612.8 ± 198.3 um and CST post-injection mean value at one and three months was 308.6± 62.6 um and 302.72± 58.64 um respectively. Statistical significance was found in pre and post one-month CST injection. The BCVA pre-injection and post-injection mean value at one and three months was 0.8 ± 0.19 and 0.49 ± 0.29 and 0.39 ± 0.20 respectively. At the one and three months post injection, there was statistical significance for both pre and post injection CST. Figure-1 illustrate the gender's distribution. Pre and post injections CST is shown in Table-I. Pre and post injection BCVA are shown in Table-II. A mean IOP of 12.32 mmHg was recorded pre-injection. Previously, 14.82 mmHg and 14.48 mmHg of intraocular pressure were recorded respectively after one and three months of injection as shown in Table-III.

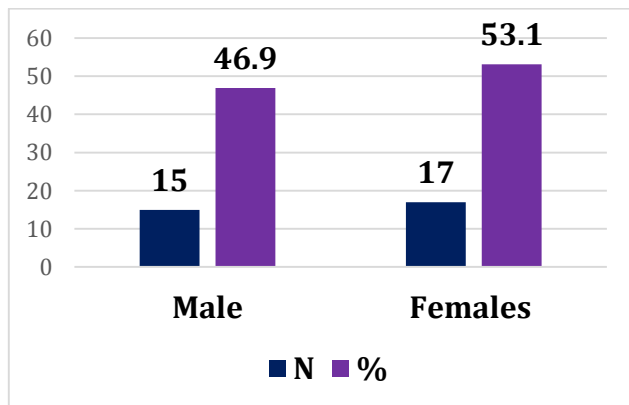


Figure-1 Gender's distribution (n=32)

Table-I Pre and post injections CST mean values

Central Subfield Thickness	Baseline	One month	Three months
Pre-injection CST	612.8 ± 198.3 um	-	-
Post-injection CST	-	308.6± 62.6 um	302.72± 58.64 um

Table-II Pre and post injections BCVA mean values

Best Corrected Visual Acuity	Baseline	One month	Three months
Pre-injection BCVA	0.8 ± 0.19	-	-
Post-injection BCVA	-	0.49 ± 0.29	0.39 ± 0.20

Table-III Pre and post injections IOP mean values

Intra Ocular Pressure	Baseline	One month	Three months
Pre-injection IOP	12.32 mmHg	-	-
Post-injection IOP	-	14.82 mmHg	14.48 mmHg

DISCUSSION

The present study mainly focused on safety and efficacy of suprachoroidal triamcinolone acetonide in diabetic macular edema cases and found that Triamcinolone Acetonide (TA) was used to enhance anatomical and functional outcomes. SCT can enhance OCT macular thickness and minimize refractory diabetic macular edema. Although intravitreal anti-VEGF medications have proven highly effective in treating diabetic macular edema (DME), they do not remove edema in all patients, indicating that processes other than VEGF are involved in the etiology of DME. Numerous investigations [12, 13] discovered that delivery of anti-VEGF injections in a single patient required from 9 to 11 doses for DME remission in the first to 17 years. Ozurdex has shown significant effectiveness in treating both refractory and naïve DME [14]. However, its usage has been associated with a significant increase in intraocular pressure (IOP) [15, 16]. IVTA's effectiveness in treating DME has been thoroughly established in recent years. Repeated investigations, however, have revealed a very high frequency of cataract development and increasing IOP with time. This is especially true when using numerous successive injections to treat persistent DME [17].

Corticosteroids delivered to the suprachoroidal space have a beneficial outcome comparable to intravitreal administration. Though, suprachoroidal administration has a longer half-life and a lower frequency of IOP increase. In comparison to the intravitreal method, the medication has a relatively low anterior chamber presence [18, 19]. The HULK study (N = 20) was just completed, and it investigated the safety and effectiveness of SCTA for DME in treatment naïve and previously treated eyes [20].

SCTA is a unique therapy approach for diabetic macular edema. The eye posterior segment might have higher TA concentration achieve through SCTA therapy. The posterior segment might have 10 times greater TA concentration as compared to anterior concentration in turn minimizing the cataract progression IOP elevation that induced by TA intravitreal injection necessitating the need for such a low-cost modified microneedle for suprachoroidal injection [21, 22].

In an instance with complete cystoid macular edema, Elman et al[23] employed a novel microneedle to infuse TA suprachoroidally, resulting in significant improvement in BCVA. In microneedle, 30-gauge needle rubber stopper was added, allowing just needle 1 mm entrance to the sclera. Additionally, Willoughby et al.[24] employed an analogous approach to the current trial for suprachoroidal injection of triamcinolone acetonide with a 26-G needle and intracath sleeve, with significant BCVA improvement and CMT decrease and no rise of IOP[25]. According to the current study, the majority of recurrent edema cases were recorded three months after injections, with 60% of eyes requiring repeat injections.

In our study, a mean IOP of 12.32 mmHg was recorded pre-injection. Previously, 14.82 mmHg and 14.48 mmHg of intraocular pressure were recorded respectively after one and three months of injection. Another research found that topical anti-glaucoma eye drops increased IOP 19 to 24 mmHg in single patient after one month and subsequently decreased to 16 mmHg three months later [26]. The present study established the SCTA safety in terms of intraocular pressure. Conversely, In contrast, recent investigations on dexamethasone implants in patients with blockage of retinal vein and posterior uveitis found that IOP rose in 25% of instances eight weeks after the injection [27].

CONCLUSION

The present study found that Triamcinolone Acetonide (TA) was administered for anatomical and functional improvement. OCT macular thickness can be improved and refractory diabetic macular edema can be reduced using SCT.

REFERENCES

1. Tayyab H, Ahmed CN, Sadiq MAA. Efficacy and safety of suprachoroidal triamcinolone acetonide in cases of resistant diabetic macular edema. *Pak J Med Sci.* 2020;36(2):42-47. doi: <https://doi.org/10.12669/pjms.36.2.1194>.
2. Habet-Wilner Z, Noronha G, Wykoff CC. Suprachoroidally injected pharmacological agents for the treatment of chorioretinal diseases: A targeted approach. *Acta Ophthalmol.* 2019;97(5):460-472. doi: 10.1111/aos.14042.

3. Schmidt-Erfurth U, Garcia-Arumi J, Bandello F, Berg K, Chakravarthy U, Gerendas BS, et al. Guidelines for the Management of Diabetic Macular Edema by the European Society of Retina Specialists (EURETINA). *Ophthalmologica*. 2017;237(4):185-222. doi: 10.1159/000458539.
4. He Y, Ren XJ, Hu BJ, Lam WC, Li XR. A meta-analysis of the effect of a dexamethasone intravitreal implant versus intravitreal anti-vascular endothelial growth factor treatment for diabetic macular edema. *BMC Ophthalmol*. 2018;18(1):121. doi: 10.1186/s12886-018-0779-1.
5. Villegas VM, Schwartz SG. Current and Future Pharmacologic Therapies for Diabetic Retinopathy. *Curr Pharm Des*. 2018;24(41):4903-4910. doi: 10.2174/1381612825666190130140717.
6. Ghoraba HH, Leila M, Elgouhary SM, Elgemai EEM, Abdelfattah HM, Ghoraba HH, et al. Safety of high-dose intravitreal triamcinolone acetonide as low-cost alternative to anti-vascular endothelial growth factor agents in lower-middle-income countries. *Clin Ophthalmol*. 2018;12:2383-2391. doi: 10.2147/OPTH.S185274.
7. Diabetic Retinopathy Clinical Research Network, Elman MJ, Aiello LP, Beck RW, Bressler NM, Bressler SB, et al. Randomized trial evaluating ranibizumab plus prompt or deferred laser or triamcinolone plus prompt laser for diabetic macular edema. *Ophthalmology*. 2010;117(6):1064-1077. doi: 10.1016/j.ophtha.2010.02.031.
8. Blinder KJ, Dugel PU, Chen S, Jumper JM, Walt JG, Hollander DA, et al. Anti-VEGF treatment of diabetic macular edema in clinical practice: Effectiveness and patterns of use (ECHO Study Report 1). *Clin Ophthalmol*. 2017;11:393-401.
9. Bressler SB, Odia I, Glassman AR, Danis RP, Grover S, Hampton GR, et al. Changes in diabetic retinopathy severity when treating diabetic macular edema with ranibizumab: drcr. net Protocol I 5-Year Report. *Retina*. 2018;38(10):1896-1904. doi: 10.1097/IAE.0000000000002302.
10. Urbancic M, Gardasevic Topcic I. Dexamethasone implant in the management of diabetic macular edema from clinician's perspective. *Clin Ophthalmol*. 2019;13:829-840. doi: 10.2147/OPTH.S206769.
11. Goldstein DA, Do D, Noronha G, Kissner JM, Srivastava SK, Nguyen QD. Suprachoroidal Corticosteroid Administration: A Novel Route for Local Treatment of Noninfectious Uveitis. *Transl Vis Sci Technol*. 2016;5(6):14. doi: 10.1167/tvst.5.6.14.
12. Campochiaro PA, Wykoff CC, Brown DM, Boyer DS, Barakat M, Tanzanite Study Group, et al. Suprachoroidal Triamcinolone Acetonide for Retinal Vein Occlusion: Results of the Tanzanite Study. *Ophthalmol Retina*. 2018;2(4):320-328. doi: 10.1016/j.oret.2017.07.013.
13. Behar-Cohen F. Recent advances in slow and sustained drug release for retina drug delivery. *Expert Opin Drug Deliv*. 2019;16(7):679-686. doi: 10.1080/17425247.2019.1618829.
14. Shatz W, Aaronson J, Yohe S, Kelley RF, Kalia YN. Strategies for modifying drug residence time and ocular bioavailability to decrease treatment frequency for back of the eye diseases. *Expert Opin Drug Deliv*. 2019;16(1):43-57. doi: 10.1080/17425247.2019.1553953.
15. Lampen SIR, Khurana RN, Noronha G, Brown DM, Wykoff CC. Suprachoroidal space alterations following delivery of triamcinolone acetonide: post-hoc analysis of the Phase 1/2 HULK study of patients with diabetic macular edema. *Ophthalmic Surg Lasers Imaging Retina*. 2018;49(9):692-697. doi:10.3928/23258160-20180831-07.
16. Vujosevic S, Torresin T, Berton M, Bini S, Convento E, Midena E. Diabetic macular edema with and without subfoveal neuroretinal detachment: two different morphologic and functional entities. *Am J Ophthalmol*. 2017;181:149-155. doi:10.1016/j.ajo.2017.06.026.
17. Suciuc CI, Suciuc VI, Nicoara SD. Optical coherence tomography (angiography) biomarkers in the assessment and monitoring of diabetic macular edema. *J Diabetes Res*. 2020;2020:1-10. doi:10.1155/2020/6655021.
18. Korobelnik JF, Lu C, Katz TA, et al. Effect of baseline subretinal fluid on treatment outcomes in VIVID-DME and Vista-DME studies. *Ophthalmol Retina*. 2019;3(8):663-669. doi:10.1016/j.oret.2019.03.015.
19. Eski Yucel O, Birinci H, Sullu Y. Outcome and predictors for 2-year visual acuity in eyes with diabetic macular edema treated with Ranibizumab. *J Ocul Pharmacol Ther*. 2019;35(4):229-234. doi:10.1089/jop.2018.0082.
20. Wykoff CC, Khurana RN, Lampen SIR, et al. Suprachoroidal triamcinolone acetonide for diabetic macular edema: the HULK trial. *Ophthalmol Retina*. 2018;2(8):874-877. doi:10.1016/j.oret.2018.03.008.
21. Choovuthayakorn J, Tantraworasin A, Phinyo P, et al. Factors associated with 1-year visual response following intravitreal bevacizumab treatment for diabetic macular edema: a retrospective single center study. *Int J Retina Vitre*. 2021;7(1):1-10. doi:10.1186/s40942-021-00286-9.
22. Nagpal M, Mehrotra N, Juneja R, Jain H. Dexamethasone implant (0.7 mg) in Indian patients with macular edema: Real-life scenario. *Taiwan J Ophthalmol*. 2018;8(3):141-148. doi: 10.4103/tjo.tjo_62_17.
23. Elman MJ, Ayala A, Bressler NM, Browning D, Flaxel CJ, Glassman AR, et al. Diabetic Retinopathy Clinical Research Network. Intravitreal Ranibizumab for diabetic macular edema with prompt versus deferred laser treatment: 5-year randomized trial results. *Ophthalmology*. 2015;122(2):375-381. doi: 10.1016/j.ophtha.2014.08.047.
24. Willoughby AS, Vuong VS, Cunefare D, Farsiou S, Noronha G, Danis RP, et al. Choroidal Changes After Suprachoroidal Injection of Triamcinolone Acetonide in Eyes With Macular Edema Secondary to Retinal Vein Occlusion. *Am J Ophthalmol*. 2018;186:144-151. doi: 10.1016/j.ajo.2017.11.020.
25. Lampen SIR, Khurana RN, Noronha G, Brown DM, Wykoff CC. Suprachoroidal Space Alterations Following Delivery of Triamcinolone Acetonide: Post-Hoc Analysis of the Phase 1/2 HULK Study of Patients with Diabetic Macular Edema. *Ophthalmic Surg Lasers Imaging Retina*. 2018;49(9):692-697. doi: 10.3928/23258160-20180831-07.
26. Yeh S, Kurup SK, Wang RC, et al. Suprachoroidal injection of triamcinolone acetonide, CLS-TA, for macular edema due to noninfectious uveitis: a randomized, Phase 2 study (DOGWOOD). *Retina*. 2019;39(10):1880-1888. doi:10.1097/IAE.0000000000002279.
27. Urbancic M, Gardasevic Topcic I. Dexamethasone implant in the management of diabetic macular edema from clinician's perspective. *Clin Ophthalmol*. 2019;13:829-840. doi:10.2147/OPTH.S206769.