

# Comparison of Clipped Laparoscopic Cholecystectomy and Clipless Laparoscopic Cholecystectomy in Context of Biliary Leakage

AURANGZEB KHAN<sup>1</sup>, ZULFIQAR ALI SHAR<sup>2</sup>, MUNAWER LATIF MEMON<sup>3</sup>, ABDUL RASHEED ZAI<sup>4</sup>, SADAF CHANDIO<sup>5</sup>

<sup>1</sup>Assistant Professor, Department of Surgery Unit-II, Benazir Bhutto Hospital, Rawalpindi

<sup>2</sup>Assistant Professor, <sup>3</sup>Postgraduate Student, Department of General Surgery, Khairpur Medical College, Khairpur Mirs

<sup>3</sup>Assistant Professor, Department of Surgery, Wah Medical College POF Hospital, Wah Cantt

<sup>4</sup>Associate Professor of Surgery, Indus Medical College Tando Muhammad Khan

Correspondence to: Aurangzeb Khan, Email: [aurangzebkhandr@gmail.com](mailto:aurangzebkhandr@gmail.com), Cell: 0333-5104022

## ABSTRACT

**Objective:** To compare the outcome of clipped laparoscopic cholecystectomy and clipless laparoscopic cholecystectomy in context of biliary leakage.

**Study Design:** Cross-sectional analytical study

**Place and Duration of Study:** Department of Surgery Unit-II, Benazir Bhutto Hospital Rawalpindi from 1<sup>st</sup> September 2021 to 31<sup>st</sup> August 2022.

**Methodology:** One hundred and twenty patients were included in the study and divided into two major groups. The biochemical analysis and ultrasonography was performed post 8 hours fasting. Group one had those cases which underwent clipped laparoscopic cholecystectomy while group 2 had those cases which underwent clipless laparoscopic cholecystectomy. The age of the patients was selected between 40 to 60 years and the prevalence for this sampling was considered as 20% in Pakistan. The demographic details, clinical history, signs and symptoms, clinical diagnosis based on USG, lipid profiling, and variables as post-operative time, hospital stay and ease in procedure were documented.

**Results:** The mean age of the cases underwent clipped laparoscopic cholecystectomy was 42.3±12.11 year with 40 females and 20 males who underwent those procedures. The mean age of the cases underwent clipless laparoscopic cholecystectomy was 40±11.05 years with 45 females and 15 males. The present study results evidently highlighted the fact that there were high percentage cases of biliary leakage seen in clipped cases than in the clipless cases. There were 22 cases with 36.6% in clipped groups while 9 cases with biliary leakage such as 15% in clipless group.

**Conclusion:** Clipless laparoscopic cholecystectomy is a better optional procedure with efficient usefulness in context to biliary leakage, operation time and hospital stays.

**Keywords:** Outcome, Clipped laparoscopy cholecystectomy, Clipless laparoscopic cholecystectomy, Biliary leakage

## INTRODUCTION

Cholecystectomy is a most commonly reported operative procedure for the removal of gall bladder. The gall bladder stones have been reported mostly in females above forty years having a high BMI levels. The stones are mostly due to cholesterol deposits. The diagnosis of the gall stones or any other gall complication such as polyps, Adenomyomatosis performed through clinical symptoms analysis and ultrasonography. The ultrasound can identify the size of gall bladder and its morphological examination. Magnetic resonance cholangio-pancreatography (MRCP) imaging technique is also used for complete size and location detection of stones. The prevalence of gall bladder stone in Pakistan ranges from 8 to 20% in patients within 40-60 years of age.<sup>1-3</sup>

Laparoscopic cholecystectomy is commonly performed for the removal of gall stones. Previously the use of harmonic scalpel was done for dividing cystic artery and the liver bed dissection. However, the recent developments can now provide safe division through harmonic scalpel sealing device technique and also the cystic duct closure within 6mm diameter.<sup>4-8</sup> This procedure also has concerns regarding production of smoke as well as unfavorable injuries to abdominal organs.<sup>9</sup>

Within the various techniques used during cholecystectomy, one important evolution in technology is based on the application of clipless laparoscopic cholecystectomy. In this technique the division of cystic duct is conducted through vessels sealing-device. It is an ultrasonic device. However, scientist major concern in using this procedure is of biliary leakage. The rate of complications which might be involved with the biliary leakage is an addressable concern.<sup>10</sup> The present study was therefore planned to compare two procedures such a conventional method of clipped laparoscopic cholecystectomy and clipless laparoscopic cholecystectomy in context of biliary leakage. The study result provided evidential proof of which process is more effect and appropriate for providing safer outcomes for the health of the patients undergoing cholecystectomy procedure.

## MATERIALS AND METHODS

This cross-sectional analytical study was carried out at Department of Surgery Unit-II, Benazir Bhutto Hospital Rawalpindi from 1<sup>st</sup> September 2021 to 31<sup>st</sup> August 2022. A total of 120 patients were included in the study and divided into two major groups. Each patient was informed of the research in detail and was requested for their consent of participation. Only those cases which consented were enrolled as cases of the study. The inclusion criteria were based on sporadic pain in right hypochondria, vomiting/nausea in some cases, indigestion and bloating, pain or discomfort in upper abdomen, confirmation through ultrasound and biochemical lipid profile results. Patient shaving all clinical symptoms but no confirmation through ultrasound or MRCP test were excluded from the study. The biochemical analysis and ultrasonography was performed post 8 hours fasting. Groups one had those cases which underwent clipped laparoscopic cholecystectomy while group 2 had those cases which underwent clipless laparoscopic cholecystectomy. The group 1 was named as "clipped" while group 2 was named as "clipless". The sample size was generated through using WHO sample size calculator software with 80% power of test and 95% CI application. The age of the patients was selected between 40 to 60 years and the prevalence for this sampling was considered as 20% in Pakistan. The demographic details, clinical history, signs and symptoms, clinical diagnosis based on USG and lipid profiling were recorded on a well-structured questionnaire. Prior to surgery a STAT dose of antibiotic was started and MRCP imaging results were collected for identifying the location, size of stones and also excluding presence of any stone in the common biliary duct. The variables as post-operative time, hospital stay and ease in procedure were documented. In clipped laparoscopic cholecystectomy cases the conventional method clipping of the cystic duct as well as artery was performed and dissection of gall bladder was done from liver bed through electro-cauterization. In clipless laparoscopic cholecystectomy cases using harmonic scalpel for closure was applied and dividing cystic duct and artery as well as dissection of gall bladder from the liver bed was conducted through harmonic

scalpel. Each patient was discharged after operation and requested for a follow up post 1 week. MRCP was repeated in suspected cases of biliary leakage. The outcomes in context to biliary leakage were compared and analyzed in both groups. Data was analyzed by using SPSS version 26.0. The Chi-square test and student's t test were used for the analysis where p value <0.05 was taken as significant.

**RESULTS**

The mean age of the cases underwent clipped laparoscopic cholecystectomy was 42.3±12.11 year with 40 females and 20 males who underwent those procedures. The mean age of the cases that underwent clipless laparoscopic cholecystectomy was 40±11.05 years with 45 females and 15 males. In both cases there were more females than males as of 33.3% and 25% respectively (Table 1).

The present study results evidently highlighted the fact that there were high percentage cases of biliary leakage seen in clipped cases than in the clipless cases. There were 22 cases with 36.6% in clipped groups while 9 cases with biliary leakage such as 15% in clipless group. This difference between both group was significant (P value =0.014) [Fig. 1].

The BMI was higher in clipped cases than clipless cases. Hypertension and diabetes was also reported more in clipped cases than clipless. However the difference was not significant. The important finding operation time s as well as the hospital stay in days of clipped laparoscopic cholecystectomy was higher than that of clipless with a value as 28.3±6.11 vs 21.1±4.3 and 2.37±0.75 vs 1.76±0.74 respectively (Table 2).

Table 1: Demographic features of clipped and clipless cases

Variable	Clipped (n=60)	Clipless (n=60)
Age (years)	42.3±12.11	40±11.05
Duration of cholestasis (days)	12.05±3.34	13.05±11.2
Gender		
Female	40 (66.6%)	35 (58.3%)
Male	20 (33.3%)	15 (25%)

Table 2: Comparison of comorbidities, operation time and hospital; stay within the groups

Variable	Clipped (n=60)	Clipless (n=60)	P value
BMI	26.3±4.11	25.3±3.3	0.55
Hypertension	17 (28.3%)	14 (23.4%)	0.06
Diabetes mellitus	2 (3.3%)	1 (1.6%)	0.68
Operation time	28.3±6.11	21.1±4.3	0.04
Hospital stay in days	2.37±0.75	1.76±0.74	0.03
Benefit in difficult procedure	1 (1.6%)	8 (13.3%)	0.001

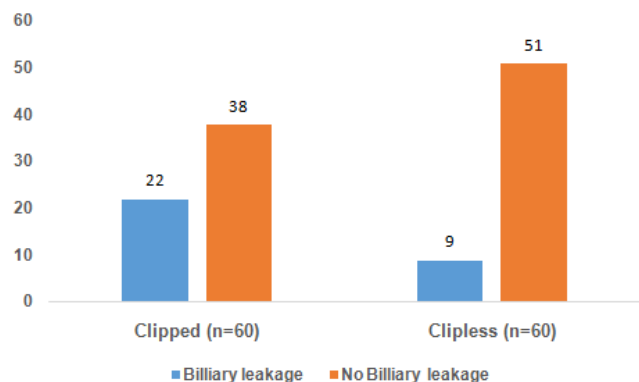


Fig. 1: Comparison of biliary leakage outcome within clipped and clipless cases

**DISCUSSION**

Laparoscopic cholecystectomy has dramatically revolutionized the

world of medical sciences by introducing safer and reliable source of treatment. In this method, cystic arteries are cystic ducts can be ligated by various methods including harmonic scalpel, intra/extra corporeal ligation and by simple clip method. In clip method, certain complications are also reported including duodenal ulcers, internalization in bile duct and bile leakage. Clipless laparoscopic cholecystectomy has been introduced in recent years. Surgery of this type can be done by using harmonic scalpel which is the most recent advancement in laparoscopic surgical method.<sup>11-13</sup> Present study was aimed to determine the effectiveness of clipless method in laparoscopic cholecystectomy.

This method appeared to be a better choice as it gave economical benefits by reducing the cost of clips with almost same efficiency and safety. Similar results have been reported by Seenu et al.<sup>14</sup> Intracorporeal knot ligation is a better alternative approach as compared to clipping method. Basic training of intracorporeal knot ligation should be recommended in laparoscopic surgical methods. Bile leakage was observed in clip surgery and no such leakage was reported in by any of the patient clipless surgical method. Bile leakage is also extensively reported by other studies as well.<sup>15-18</sup>

Biliary leakage could be possibly done by various methods such as inadequate closure of the duct, slippage of the clips, necrosis of the duct or migration of the clip to the biliary tract. Clipless surgery does not involve any such hazards as it could be done through internal knotting method which minimizes the chances of biliary leakage and any such complications. It involves less pain and almost minimal chances of port site infections and necrosis.<sup>19-22</sup>

**CONCLUSION**

Clipless laparoscopic cholecystectomy is better optional procedure with efficient usefulness in context to biliary leakage, operation time and hospital stays. Clipless surgery can be used as in case to decrease morbidity and reduce mortality.

**REFERENCES**

1. Abounozha S, Ibrahim R, Alshahri T. Is the rate of bile leak higher in clipless laparoscopic cholecystectomy compared to conventional cholecystectomy? *Ann Med Surg* 2021; 62: 186-9.
2. Sanawan E, Qureshi AU, Qureshi SS, Cheema KM, Cheema MA. Effectiveness of ultrasound shear for clipless laparoscopic cholecystectomy versus conventional unipolar electrocautery in patients with cholelithiasis. *J Coll Phys Surg Pak* 2017; 27(10): 611-5.
3. Hayat N, Duja B, Ahmed T, Rehan AG. To determine the importance of age and sex in the clinical presentation and subsequent outcome in cholelithiasis. *JUMDC* 2013; 4:36-41.
4. Carbonell AM, Joels CS, Kercher KW. A comparison of laparoscopic bipolar vessel sealing devices in the hemostasis of small, medium and large sized arteries. *J Laparoscope Surg Tech A* 2003; 13: 377-80.
5. Denes B, de la Torse RA, Krummel TM, Evaluation of a vessel sealing system in a porcine model. In 21<sup>st</sup> World Congress of Endourology, Canada 2003.
6. Fullum T, Kim S, Dan P, Turner PL. Laparoscopic dome down cholecystectomy with the LCS-5 harmonic scalpel. *J Soc Laparoendosc Surg* 2005; 9: 51-7.
7. Cengiz Y, Jänes A, GrehnÅ,. Randomized clinical trial of traditional dissection with electrocautery versus ultrasonic fundus first dissection in LC. *Br J Surg* 2005; 92: 810-3.
8. Janssen IMC, Swank DJ, Boonstra O, Knipscheer BC, Klinkenbijn JHG, van Goor H. Randomized clinical trial of ultrasonic versus electrocautery dissection of the gallbladder in laparoscopic cholecystectomy. *Br J Surg* 2003; 90: 799.
9. Amarin NS. Harmonic scalpel and clipless cholecystectomy. *World J Laparosc Surg* 2008; 1: 6-8.
10. Foschi D, Cellierino P, Corsi F, Previde P, Allevi, Raffaele. Closure of the cystic duct by ultrasonic energy. *Endosc Percutaneous Tech* 2009; 19: 34-8.
11. Kandil T, El Nakeeb A, El Hefnawy E. Comparative study between clipless laparoscopic cholecystectomy by harmonic scalpel versus conventional method: a prospective randomized study. *J Gastrointest Surg* 2010; 14: 323-8.
12. Huscher CGS, Lirici MM, Di Paola M, et al. Laparoscopic

- cholecystectomy by ultrasonic dissection without cystic duct and artery ligation. *Surg Endosc* 2003; 17: 442-51.
13. Champault A, Vons C, Dagher I, Amerlinck S, Franco D. Low-cost laparoscopic cholecystectomy. *Brit J Surg* 2002; 89: 1602-7.
  14. Seenu V, Shridhar D, Bal C, Parshad R, Kumar A. Laparoscopic cholecystectomy: cystic duct occlusion with titanium clips or ligation? A prospective randomized study. *Trop Gastroenterol* 2004; 25: 80-3.
  15. Nelson TM, Nakashima M, Mulvihill SJ. How secure are laparoscopically placed clips? *Arch Surg* 1992; 127: 718-20.
  16. McMahon AJ, Fullarton G, Baxter JN, O'Dwyer PJ. Bile duct injury and bile leakage in laparoscopic cholecystectomy. *Brit J Surg* 1995; 82: 307-13.
  17. Abounozha S, Alshahri T, Alammari S, Ibrahim R. Clipless laparoscopic cholecystectomy is a better technique in reducing intraoperative bleeding. *Ann Med Surg* 2021; 62: 431-4.
  18. Wills E, Crawford G. Clipless versus conventional laparoscopic cholecystectomy. *J Laparoendosc Adv Surg Tech A* 2013; 23(3): 237-9.
  19. Singal R, Sharma A, Zaman M. The safety and efficacy of clipless versus conventional laparoscopic cholecystectomy: our experience in an Indian Rural Center. *Maedica (Bucur)* 2018; 13(1):34-43.
  20. ElGeidie AA. New technique of clipless laparoscopic cholecystectomy. *Surg Sci* 2012; 3(6): 310-13.
  21. Vu T, Aguilo R, Marshall NC. Clipless technique of laparoscopic cholecystectomy using the harmonic scalpel. *Ann R Coll Surg Engl* 2008; 90(7): 612.
  22. Mahmoud MS, Hamed AE, Mekki M. Clipless laparoscopic cholecystectomy using ultrasonic dissection. *Med J Cairo Uni* 2020; 88: 1157-63.