

ORIGINAL ARTICLE

Functional and Radiological Outcome of Anterior Cervical Discectomy and Titanium Cage Fusion in the Management of Patients with Degenerative Cervical Spine Disease

SARDAR SOHAIL AFSAR¹, YAQOOB UR REHMAN², AKBAR ALI³¹Chairman and associate professor orthopaedics, Nowshera medical college and qazi Hussain Ahmed medical complex, Nowshera²Assistant Professor, Qazi Hussain Ahmad Medical Complex/ Nowshera Medical College³Assistant professor, Nowshera medical college and qazi Hussain Ahmed medical complex Nowshera

Corresponding author: Akbar Ali, Email: aksafi135@gmail.com

ABSTRACT

Background: The causes of cervical radiculopathy include trauma, disc herniation, instability, spondylosis and, in rare cases, malignancies. Degenerative spinal disorders are often treated by anterior cervical discectomy.

Objective: To assess the functional and radiological outcome of anterior cervical discectomy and titanium cage fusion in the management of patients with degenerative cervical spine disease

Methodology: The current study was descriptive study carried out at the orthopedic department, Qazi Hussain Ahmad Medical College, Nowshera from August 2021 to August 2022. All the relevant laboratory and radiological investigations were carried out for the enrolled patients. Cervical radiographs were examined for fusion, cage subsidence, and kyphosis at each visit. The functional outcomes, quality of life and pain level was determined for all the patients. IBM SPSS version 23 was employed for analysis of data.

Results: In the current study, totally 50 patients were enrolled. The male participants in this study were 30 (60%) while female patients were 20 (40%). The mean age of the patients was 53 (± 5.32). The pre-operative mean NDI, VAS and EQ-5D-5L index was 42 (5.90), 8.11 (2.11) and 0.54 (0.01) respectively while the post-operative mean NDI, VAS and EQ-5D-5L index was 19 (2.81), 2 (1.88) and 0.75(0.01) respectively ($p < 0.05$). In all the enrolled patients radiographical fusion was achieved successfully. Segmental subsidence was reported in 2 (4%) patients while kyphosis was not observed in any of our patients.

Conclusion: Our study concludes that in patients with symptomatic degenerative cervical spine disease, the anterior cervical discectomy and titanium cage fusion is an effective and safe surgical procedure with excellent functional and radiological outcome. Our study observed minimal complication rate by using this procedure.

Keywords: Radiological outcome; Anterior cervical discectomy; titanium cage fusion; degenerative cervical spine disease

INTRODUCTION

The causes of cervical radiculopathy include trauma, disc herniation, instability, spondylosis and, in rare cases, malignancies¹. Cervical spondylosis accounts for the majority of cervical radiculopathies, whereas disc herniation accounts for 25% of cases². Cervical radiculopathy has been found to have a point prevalence of 3.5 per 1,000 and a yearly incidence of 83 per 100,000³. A more prevalent cause of neurological dysfunction at the present time is cervical spondylosis⁴. Degenerative alterations include disc herniation, osteophyte formation, osteoarthritic facet joint hypertrophy, and ligament hypertrophy. Most of the time, the condition is thought to be asymptomatic, however it is observed that in 10-15% of instances, there is compression of cord and nerve root, which may result in clinical symptoms⁵. In these situations, conservative treatment is often used in the management. Physical therapy, anti-inflammatory drugs, cervical immobilization, and other measures are often used in the conservative care⁶. Surgery of any kind is often only used to treat individuals who have worsening neurological symptoms and pain that cannot be managed conservatively. Degenerative cervical spine illnesses were first treated by anterior cervical discectomy in 1950s and early 1960s⁶⁻⁸. For patients with severe degenerative cervical spine disease, anterior cervical discectomy and fusion (ACDF) is thought to be the most reliable and experimentally verified surgical procedure⁹. In ACDF surgery, spine surgeons employ a variety of graft materials to strengthen the fusion^{9, 10}. Although autografts are often the primary option, their related morbidities must not be disregarded¹⁰. For the goal of interbody fusion during ACDF surgery, cages have been adopted in order to reduce the risks associated with auto graft problems¹¹. Titanium and Polyetheretherketone (PEEK) cages are the most often used cage materials. The PEEK cage is a biocompatible radiolucent¹². It is made of polyetheretherketone, titanium, and carbon fiber reinforced polymers¹³. Domed-shaped titanium cages (TTN) feature a diamond-porous structure with a pore width of 60 μ m and a porosity of 80%¹⁴. It has a cellular implant with a strong structure¹⁵. Proteins, mesenchymal cells, and bone cells adhere more

quickly to TTN cages due to their hydrophilic properties, which contribute to maximal blood contact in vivo and eventually promote fusion¹⁶. When TTN is utilised for cervical fusion in patients with anterior cervical discectomy, excellent functional and radiological outcomes have been documented^{17, 18}. In our study, no such study has been carried out. Therefore this study was piloted to assess the functional and radiological outcome of anterior cervical discectomy and titanium cage fusion in the management of patients with degenerative cervical spine disease.

MATERIALS AND METHODS

The current study was descriptive study carried out at the orthopedic department, Qazi Hussain Ahmad Medical College, Nowshera. The study was carried out for a period of one year from August 2021 to August 2022. The study approval was taken from the institutional review board. The overall sample size based on the WHO calculator for sample size was 50 patients.

Inclusion criteria:

- Adult patients of both the gender
- Patients with diagnosed symptomatic single level degenerative cervical spine disease with failed conservative treatment
- Patients want to participate in our study

Exclusion criteria:

- Patients with traumatic spine injuries,
- Patients with previous cervical spine surgeries,
- Patients having infections
- Patients having tumours
- Patients with multilevel instability
- Patients not willing to participate in our study

The study objective was explained to all the participants and then informed consent was taken. All the data was collected in a special designed proforma for this study. All the enrolled patients were examined clinically. All the relevant laboratory and radiological investigations were carried out for the enrolled patients. Under general anesthesia all the surgeries were performed. The diseased level was identified using an

intraoperative image intensifier. Decompression of the neural elements was achieved through excision or opening of the posterior longitudinal ligament, after meticulous microdiscectomy and removal of posterior cervical osteophyte. After using a titanium cage for the interbody fusion, homeostasis was achieved. Every patient received a soft cervical collar after surgery. Following that, they were scheduled every two weeks for the first month and then every two months till one year. Cervical radiographs were examined for fusion, cage subsidence, and kyphosis at each visit. Neck Disability Index (NDI) score was used to determine the functional outcome¹⁹. EQ-5D-5L score was used to determine the quality of life²⁰. Visual Analogue Scale (VAS) was used to determine the pain intensity of neck and arm²¹. IBM SPSS version 23 was employed for analysis of data. Age was documented as mean (\pm SD) while gender and post operative complications and site of problem were documented as percentage and frequency.

RESULTS

In the current study, totally 50 patients were enrolled. The male participants in this study were 30 (60%) while female patients were 20 (40%). (Figure 1) The mean age of the patients was 53 (\pm 5.32). Based on the site of cervical intervertebral spaces, C5C6 was involved in 27 (54%) patients while C4C5 was involved in 23 (46%) patients. (Figure 2) Based on pre-operative sign, cervical radiculopathy was observed in 30 (60%) patients while myelopathy was observed in 20 (40%) patients. (Figure 3) The pre-operative mean NDI, VAS and EQ-5D-5L index was 42 (5.90), 8.11 (2.11) and 0.54 (0.01) respectively while the post-operative mean NDI, VAS and EQ-5D-5L index was 19 (2.81), 2 (1.88) and 0.75(0.01) respectively ($p < 0.05$). (Figure 4) In all the enrolled patients radiographical fusion was achieved successfully. Based on post operative complication, Segmental subsidence was reported in 2 (4%) patients while kyphosis was not observed in any of our patients.

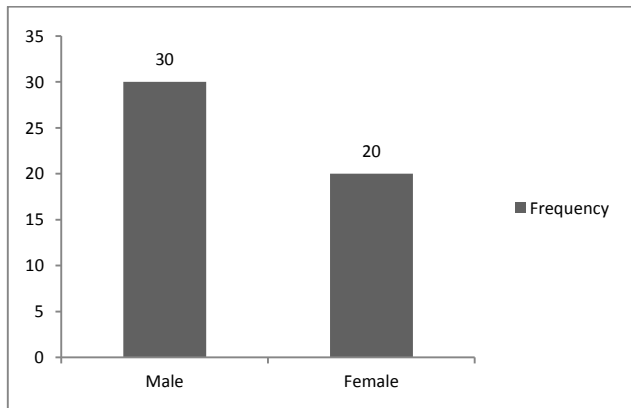


Figure 1: Distribution of patients on gender basis

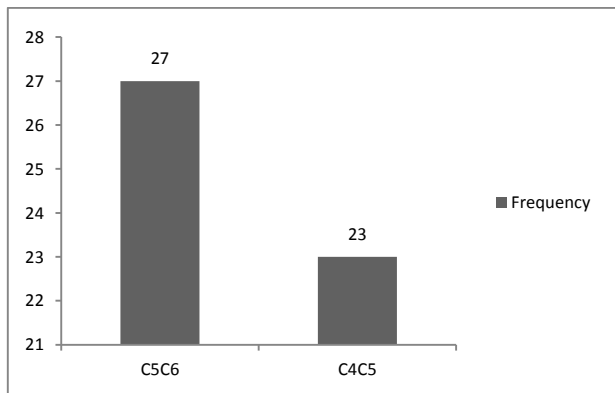


Figure 2: Distribution of patients based on the site of cervical intervertebral spaces

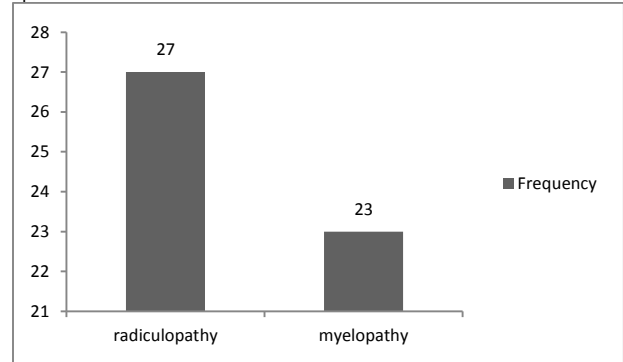


Figure 3: Distribution of patients based on pre-operative sign

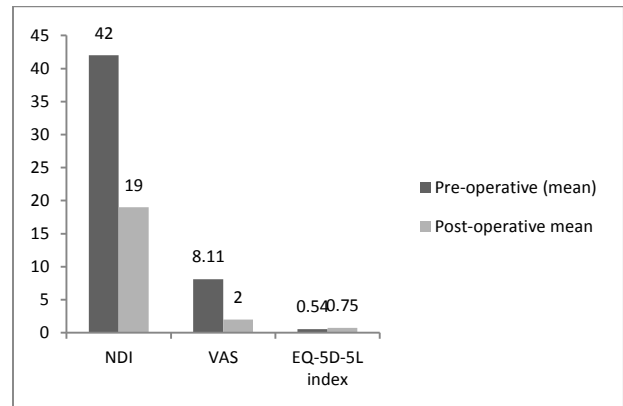


Figure 4: Mean Pre-operative and post-operative NDI, VAS and EQ-5D-5L index

DISCUSSION

Cervical spondylotic myelopathy and radiculopathy progress with age²². Due to pain and neurological abnormalities, the condition affects how the patient functions and engages in everyday activities. Doctors are very concerned about having a good management strategy. The severity of the condition and the degree of neurological recovery after the operation are crucial considerations²³. Degenerative spinal disorders are often treated by anterior cervical discectomy. In the current study, totally 50 patients were enrolled. The male participants in this study were 60% while female patients were 40%. The mean age of the patients was 53 (\pm 5.32). Based on the site of cervical intervertebral spaces, C5C6 was involved in 54% patients while C4C5 was involved in 46% patients. Based on pre-operative sign, cervical radiculopathy was observed in 60% patients while myelopathy was observed in 40% patients. The pre-operative mean NDI, VAS and EQ-5D-5L index was 42 (5.90), 8.11 (2.11) and 0.54 (0.01) respectively while the post-operative mean NDI, VAS and EQ-5D-5L index was 19 (2.81), 2 (1.88) and 0.75(0.01) respectively ($p < 0.05$). In all the enrolled patients radiographical fusion was achieved successfully. Based on post operative complication, Segmental subsidence was reported in 2 (4%) patients while kyphosis was not observed in any of our patients. Another study was carried out by A M Siddiqui et al. on patients with degenerative cervical spine disease. They treated 38 patients by using anterior cervical discectomy and titanium cage fusion. In their study, female predominate a male which is not in accordance with our study. In their study, radiological union was achieved in all the patients which is similar with our findings. In their study there was a significant decrease in post-operative mean NDI, VAS and EQ-5D-5L index as compared to preoperative mean NDI, VAS and EQ-5D-5L index which is also in accordance with our study

findings. In their study Segmental subsidence was observed in 2.63% patients while in our study it was observed in 4% patients. Kyphosis was not observed in their study which is consistent with our research findings²⁴. Interbody spacers are available in a variety of forms and sizes and are constructed from a variety of materials^{25, 26}. We used titanium cage for fusion and achieved successful fusion in all cases. A study done by Moreland et al. achieved fusion in 78% patients in their series with improvement in VAS and Oswestry pain and disability index²⁷. Another study done by Hauerberg compared anterior cervical discectomy with or without fusion with Ray titanium cage and documented no statistically significant difference in both groups in terms of severity of pain and patient satisfaction. The rate of fusion however was found to be slightly higher in cage group²⁸. A study done by Junaid et al. compared cervical titanium cage with PEEK in 149 patients and noted no significant difference in functional and radiological outcome at one year follow up²⁹. A study done by Sugawara et al. treated 41 patients with ACDF and titanium cages and noted 95% fusion rates and excellent and good outcome in 80% of their patients as per Odom's criteria at 5 years follow up³⁰.

CONCLUSION

Our study concludes that in patients with symptomatic degenerative cervical spine disease, the anterior cervical discectomy and titanium cage fusion is an effective and safe surgical procedure with excellent functional and radiological outcome. Our study observed minimal complication rate by using this procedure. We therefore recommend this technique as treatment of choice for single level degenerative cervical spine disease.

REFERENCES

- Caridi JM, Pumberger M, Hughes AP. Cervical radiculopathy: a review. *HSS Journal*. 2011;7(3):265-72.
- Radhakrishnan K, Litchy WJ, O'fallon WM, Kurland LT. Epidemiology of cervical radiculopathy: a population-based study from Rochester, Minnesota, 1976 through 1990. *Brain*. 1994;117(2):325-35.
- Todd AG. Cervical spine: degenerative conditions. *Curr Rev Musculoskelet Med*. 2011;4(4):168-74.
- Young WF. Cervical spondylotic myelopathy: a common cause of spinal cord dysfunction in older persons. *Am Fam Physician*. 2000;62(5):1064-70.
- Bednarik J, Kadanka Z, Dusek L, Novotny O, Surelova D, Urbanek I, et al. Presymptomatic spondylotic cervical cord compression. *Spine (Phila Pa 1976)*. 2004;29(20):2260-9.
- Nikolaidis I, Fouyas IP, Sandercock PA, Statham PF. Surgery for cervical radiculopathy or myelopathy. *Cochrane Database Syst Rev*. 2010(1).
- Smith G, Robinson R. The Journal of Bone & Joint Surgery. *J Bone Joint Surg Am*. 1958;40(3):607-24.
- Cloward RB. The anterior approach for removal of ruptured cervical disks. *J Neurosurg*. 1958;15(6):602-17.
- Robinson RA. Fusions of the cervical spine. *JBJS*. 1959;41(1):1-6.
- Silber JS, Anderson DG, Daffner SD, Brislin BT, Leland JM, Hilibrand AS, et al. Donor site morbidity after anterior iliac crest bone harvest for single-level anterior cervical discectomy and fusion. *Spine (Phila Pa 1976)*. 2003;28(2):134-9.
- Chong E, Pelletier MH, Mobbs RJ, Walsh WR. The design evolution of interbody cages in anterior cervical discectomy and fusion: a systematic review. *BMC Musculoskelet Disord*. 2015;16(1):1-11.
- Shousha M, Ezzati A, Boehm H. Four-level anterior cervical discectomies and cage-augmented fusion with and without fixation. *Eur Spine J*. 2012;21(12):2512-9.
- Cho D-Y, Liao W-R, Lee W-Y, Liu J-T, Chiu C-L, Sheu P-C. Preliminary experience using a polyetheretherketone (PEEK) cage in the treatment of cervical disc disease. *Neurosurgery*. 2002;51(6):1343-50.
- Spetzger U, Frasca M, König SA. Surgical planning, manufacturing and implantation of an individualized cervical fusion titanium cage using patient-specific data. *Eur Spine J*. 2016;25(7):2239-46.
- Arts M, Torensma B, Wolfs J. Porous titanium cervical interbody fusion device in the treatment of degenerative cervical radiculopathy; 1-year results of a prospective controlled trial. *The Spine Journal*. 2020;20(7):1065-72.
- Li Z-j, Wang Y, Xu G-j, Tian P. Is PEEK cage better than titanium cage in anterior cervical discectomy and fusion surgery? A meta-analysis. *BMC Musculoskelet Disord*. 2016;17(1):1-9.
- Luo Y, Cao X, Chen J, Gu J, Yu H, Sun J, et al. Platelet-Derived Growth Factor-Functionalized Scaffolds for the Recruitment of Synovial Mesenchymal Stem Cells for Osteochondral Repair. *Stem Cells Int*. 2022;2022.
- Cabraja M, Oezdemir S, Koeppen D, Kroppenstedt S. Anterior cervical discectomy and fusion: comparison of titanium and polyetheretherketone cages. *BMC Musculoskelet Disord*. 2012;13(1):1-9.
- Vernon H, Mior S. The Neck Disability Index: a study of reliability and validity. *J Manipulative Physiol Ther*. 1991.
- Kim TH, Jo M-W, Lee S-i, Kim SH, Chung SM. Psychometric properties of the EQ-5D-5L in the general population of South Korea. *Qual Life Res*. 2013;22(8):2245-53.
- Boonstra AM, Preuper HRS, Reneman MF, Posthumus JB, Stewart RE. Reliability and validity of the visual analogue scale for disability in patients with chronic musculoskeletal pain. *Int J Rehabil Res*. 2008;31(2):165-9.
- Fehlings MG, Smith JS, Kopjar B, Arnold PM, Yoon ST, Vaccaro AR, et al. Perioperative and delayed complications associated with the surgical treatment of cervical spondylotic myelopathy based on 302 patients from the AOSpine North America Cervical Spondylotic Myelopathy Study: Presented at the 2011 Spine Section Meeting. *J Neurosurg Spine*. 2012;16(5):425-32.
- Azimi P, Shahzadi S, Benzel EC, Montazari A. Functional evaluation using the modified Japanese Orthopedic Association score (mJOA) for cervical spondylotic myelopathy disease by age, gender, and type of disease. *J Inj Violence Res*. 2012;4(3 Suppl 1):42.
- Siddiqui AM, Khan ZA, Zahoor A-W, Butt U, Shah IA. Role of Anterior Cervical Discectomy and Titanium Cage Fusion in patients with Degenerative Cervical Spine Disease. *Journal of Pakistan Orthopaedic Association*. 2022;34(03):112-5.
- Korinath M. Treatment of cervical degenerative disc disease—current status and trends. *Central European Neurosurgery-Zentralblatt für Neurochirurgie*. 2008;69(03):113-24.
- Cahill DW, Martin GJ, Hajjar MV, Sonstein W, Graham LB, Engelman RW. Suitability of bioresorbable cages for anterior cervical fusion. *J Neurosurg Spine*. 2003;98(2):195-201.
- Moreland DB, Asch HL, Clabeaux DE, Castiglia GJ, Czajka GA, Lewis PJ, et al. Anterior cervical discectomy and fusion with implantable titanium cage: initial impressions, patient outcomes and comparison to fusion with allograft. *The Spine Journal*. 2004;4(2):184-91.
- Hauerberg J, Kosteljanetz M, Bøge-Rasmussen T, Dons K, Gideon P, Springborg JB, et al. Anterior cervical discectomy with or without fusion with ray titanium cage: a prospective randomized clinical study. *LWW*; 2008.
- Junaid M, Rashid MU, Bukhari SS, Ahmed M. Radiological and clinical outcomes in patients undergoing anterior cervical discectomy and fusion: Comparing titanium and PEEK (polyetheretherketone) cages. *Pakistan journal of medical sciences*. 2018;34(6):1412.
- Sugawara T, Itoh Y, Hirano Y, Higashiyama N, Mizoi K. Long term outcome and adjacent disc degeneration after anterior cervical discectomy and fusion with titanium cylindrical cages. *Acta Neurochir (Wien)*. 2009;151(4):303-9.