

ORIGINAL ARTICLE

Histopathological Spectrum of Phyllodes Tumor of Breast in a Tertiary Health Care Center: A 5-Year Retrospective StudyPARSA KAINAT¹, MUHAMMAD RAHIL KHAN², SORATH SINDHU³, RIYASAT AHMED MEMON⁴, ZAHID ALI NOHRI⁵, MARYAM ANMOL⁶¹MBBS, Department of Pathology/ Liaquat University of Medical and Health Sciences Jamshoro Sindh²MBBS FCPS (Histopathology), Department of Pathology/ Liaquat University of Medical and Health Sciences Jamshoro Sindh³MBBS, M. Phil, Department of Pathology/ Liaquat University of Medical and Health Sciences Jamshoro Sindh⁴MBBS, FCPS (Histopathology), Department of Pathology/ Bilawal Medical College LUMHS Jamshoro Sindh⁵MBBS, M.Phil., Department of Pathology/ Liaquat University of Medical and Health Sciences Jamshoro Sindh⁶MBBS, Department of Pathology/ Liaquat University of Medical and Health Sciences Jamshoro Sindh

Corresponding author: Parsa Kainat, Email: Parsakainat@gmail.com, Cell: 03330134484

ABSTRACT**Objectives:** This study was done to evaluate the histopathological spectrum of phyllodes tumor of breast in women of various age groups.**Study design:** Cross-sectional descriptive study**Place and Duration:** This cross-sectional study was done at the Department of histopathology, Liaquat University of Medical and Health sciences, Jamshoro, Pakistan. 2017-2021.**Methods:** Total 178 cases of phyllodes tumors were retrospectively identified. The clinical history of patients was taken from computer storage data followed by review of microscopic slides by two histopathologists. Excel 2021 and SPSS 22 were used for statistical analysis.**Results:** The mean age was 35.37±11.74 (range 12-70 years). Most of the cases were of benign phyllodes tumors 55.1%(n=98). Maximum number of cases were of the age groups 30-39 years (36.5%(n=65)). Two cases of malignant phyllodes tumor were noted in age groups 11-20 years.**Conclusion:** Phyllodes tumor of breast is more common in 3rd decade. A multidisciplinary approach including complete and thorough clinical examination, careful histopathologic evaluation should be done to ensure prompt treatment to patients.**Keywords:** Phyllodes tumor, Fibroepithelial lesion, Histopathologic examination**INTRODUCTION**

According to the American cancer society, almost 10% women experience breast lump once in their life. These breast lumps are mostly benign fibroepithelial lesions. Phyllodes tumor are rare biphasic neoplasms with characteristic histologic and imaging features. Phyllodes tumors mostly present in 40s to 50s and can locally recur and metastasize.¹ Benign phyllodes tumor shares same morphologic and clinical features with fibroadenomas while malignant phyllodes tumor can be difficult to differentiate with sarcomatous carcinomas on histopathology. Presence of a leaf like pattern with stromal cellularity favors phyllodes tumor in a biopsy specimen while on cytopathology, the distinction is difficult. In addition to the overlapping morphology, phyllodes tumor also shares same MED12 genetic mutation as fibroadenoma. This distinction is necessary in order to optimize the surgical intervention as phyllodes tumor requires wide local excision with 1cm safe margin to avoid recurrence.²

Women can report with phyllodes tumor at any age although 35-55 years is the most common age of presentation. The clinical presentation in phyllodes tumor can be delayed as they are slow growing and painless. The tumor can be as small as <1cm to as large as 40cm. As current methods of preoperative diagnosis have lower accuracy, surgeons often face restriction in establishing an appropriate treatment plan for patients.³

The clinical presentation of these phyllodes tumor varies from one subtype to another with malignant subtype carrying the worst outcome and lowest survival rate. However, their classical presentation is as a rapidly growing mass or a lump that had been stable for years.⁴

Fibroepithelial lesions in breast consist of a wide variety of tumors that range from the benign fibroadenoma to malignant phyllodes of breast. Despite having a criterion for their classification, pathologists often face challenge in reaching a definite diagnosis as there are a lot of overlapping features. Radiologic findings and clinical data are often unhelpful in reaching a diagnosis. The current criteria comprise of multiple factors like mild, moderate or severe atypia that leads to subjective variation.⁵

Distinguishing fibroadenomas from phyllodes tumor on physical examination is extremely difficult. On the hand ultrasound is often not helpful in differentiating between benign, borderline and malignant phyllodes tumor. Therefore, the diagnosis often

requires use of some intervention as core biopsy but that too can be unreliable due to sampling errors.⁶

Phyllodes Tumor of breast comprises of almost 2 to 3 % cases of fibroepithelial tumors of breast and 0.2 to 2% of all breast tumors. WHO has classified phyllodes tumors into benign, borderline and malignant as shown in figure 1-3. The classification depends on various factors such as stromal cellularity overgrowth, number of mitosis and tumor margins.⁷ Benign phyllodes tumor is the most common subtype with almost 70% of the total cases.⁸ Regardless of the tumor grade or subtype, safe margin of excision is the prime predictor in determining local recurrence. The widely accepted treatment modality for phyllodes tumor is surgical resection with a safe margin of 1cm.⁹

There are fewer studies done on the genetic alteration involved in phyllodes tumor. Gene sequencing also suggests fibroadenoma to be a discretional precursor of phyllodes. In recent years, some studies have elaborated MED12, TERT, RB1 and EGFR mutations to be the key driver gene alteration in phyllodes tumor. However further studies are required to evaluate whether genetic studies would be helpful in the diagnosis.¹⁰

Women presenting at young age with carcinoma breast are at an increased risk of death. In comparison with older women, local recurrence of tumor as well as metastatic disease is also very common among young patients.¹¹ This study was aimed to analyze histopathological spectrum of phyllodes in women over a period of 5 year in various age groups.

METHODS

This cross-sectional study was done at the department of histopathology, Liaquat university of medical and health sciences Jamshoro Sindh. Total 179 cases of phyllodes tumor were retrospectively identified. Complete clinical history and histopathological reports of patients were retrieved from computer data storage. The microscopic slides were reviewed by two histopathologist. All biopsy specimen of Phyllodes tumor of breast in females received at the department of histopathology during 2017 to 2021 irrespective of age were included in the study while specimen with autolytic changes and Trucut biopsy specimen with insufficient biopsy material were excluded. The diagnoses remained the same after review by histopathologist. Excel 2021 and SPSS version 22 were used for statistical analysis. Distribution

of phyllodes tumor was calculated in 7 age groups. Descriptive statistics were applied to calculate mean age, frequency and percentages and standard deviation. Mean and standard deviation was calculated for age. Frequency and percentage were calculated for qualitative variables such as histopathological types. This study was approved by the institutional review board DOC# LUMHS/DEAN/BMS

RESULTS

Total 178 cases were included in the study. The mean age was 35.37±11.74 (range 12-70 years). Most of the cases were of benign phyllodes tumors 55.1%(n=98). Mostly biopsies were excisional 64%(n=114). Maximum number of cases were of the age groups 30-39 years 36.5% (n=65) as shown in graph 1. Two cases of malignant phyllodes tumor were noted in age groups 11-20 years. Demographic and morphological characteristics are discussed in table 1.

Table 1: Demographic and morphological characteristics of phyllodes tumor.

Factor	N (%)
Age	
<20	17 (9.6)
20-29	35(19.7)
30-39	65(36.5)
40-49	32(18.0)
50-59	6(3.4)
>60	4(2.2)
Type of biopsy	
Incisional biopsy	28(15.7)
Excisional biopsy	114(64)
Mastectomy	36(20.2)
Marital status	
Married	144(80.9)
Unmarried	34(100.0)
Histopathological findings	
Benign	98(55.1)
Borderline	37(20.8)
Malignant	43(24.2)

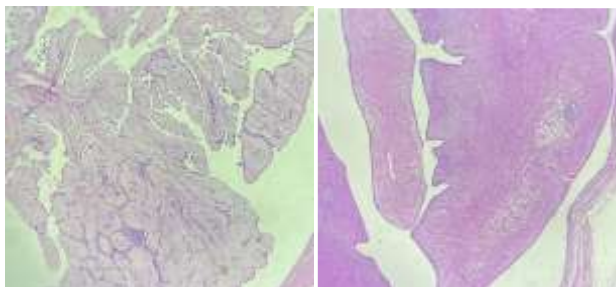
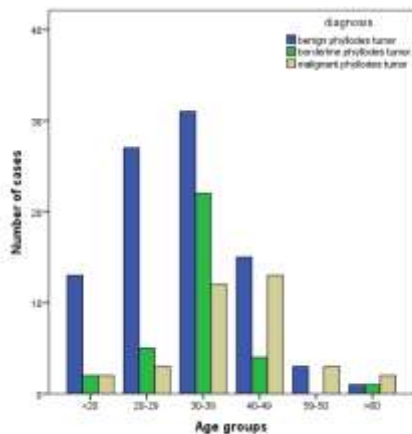


Figure 1: Benign phyllodes tumor. A) low stroma to epithelium ratio (B) Characteristic leaf like pattern

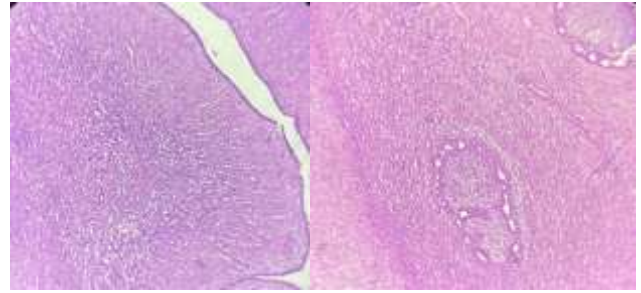


Figure 2: Borderline phyllodes tumor. (A) Moderate stromal atypia (B) epithelial structures distorted by stromal overgrowth.

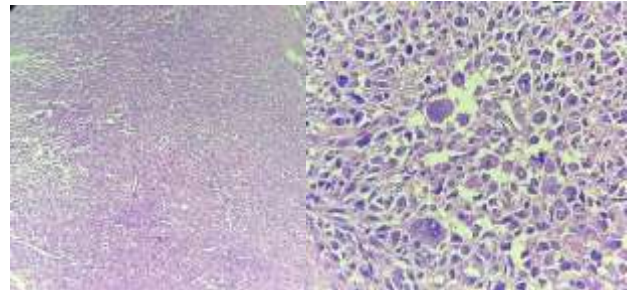


Figure 3: Malignant phyllodes tumor. (A) Marked stromal atypia (B) Stromal giant cells.

DISCUSSION

Phyllodes tumors are rare primary breast neoplasm with mesenchymal and epithelial components. It affects younger population more as compared to the more common fibroepithelial lesion fibroadenoma. Depending on the histopathological subtype, the tumor may behave as completely benign to a very malignant neoplasm with distant metastasis.¹²

Physical examination along with ultrasonography and mammogram is used for assessment of breast lumps. If clinically warranted, fine needle aspiration and core needle biopsy is also done. When a breast lump cannot be clearly categorized as fibroadenoma or phyllodes tumor, excisional biopsy is usually recommended to avoid possibility of neglecting a malignant tumor. Hence preoperative identification of phyllodes tumor is emphasized in order to avert any operative complications such as incomplete excision or overtreatment.⁶

Almost 1 to 15% patients with phyllodes tumor have disseminated disease at presentation. The clinical behavior in phyllodes tumor can be dynamic. Patients with malignant phyllodes carry 20-25% risk of distant metastasis. However, metastatic behavior has also been reported in benign type of tumors.¹³

Malignant phyllodes tumor spreads to favored sites as lung, liver, brain, adrenal gland, bone and rarely heart and oral cavity can also be involved. It spreads via hematogenous route. Some patients develop metastasis in distant sites synchronously while others develop few months after the primary tumor. Patients with distant metastasis have a poor outcome. Wide local excision or mastectomy is done in such patients with a possibility of treatment failure with tumor recurrence. Hormonal therapy is not given in such patients in contrast to other breast malignancies. Chemotherapy and radiation therapy along with wide local excision is the mainstay of treatment. However, it has a confined role in improving the outcome and survival of patients.¹⁴

Ji-Yeon et al¹⁵discussed various genetic alterations involved in malignant phyllodes and their potential therapeutic benefit. However, there are no studies which explain these genetic alterations and their correlation to clinical prognosis or outcome. Up to 80% malignant phyllodes tumor does not metastasize and there has been no effective treatment in such patients.

According to li tao et al¹⁶ there are no specific age groups subjective to increased mortality rates in breast cancer.

Comparison of various prognostic factors among young and old patients is not well understood and has been poorly linked to survival.

In our study, significant number of cases were of women in 3rd decade of life. Mei et al¹⁷ reported that the younger and older patients had a poorer outcome than the middle-aged patients. This variation among different age groups can be explained with hormonal receptor status but no difference was identified in terms of clinicopathological factors or comorbid conditions. This disparity needs further exploration so better treatment-based approaches can be provided to improve prognosis in young population.

Therefore, careful evaluation of histologic subtype, tumor border, mitosis, stromal hyperplasia or atypia should be carefully considered as management and treatment approaches are different in all subtypes.³

CONCLUSION

Phyllodes tumor of breast is more common in 3rd decade. Phyllodes tumor in younger women should be carefully evaluated as the clinical behavior is dynamic and if left untreated can present with metastatic disease. A multidisciplinary approach including complete and thorough clinical examination, careful histopathologic evaluation should be done to ensure specific and prompt treatment to patients as prognoses varies among various subtypes.

REFERENCES

1. Chang J, Denham L, Dong EK, Malek K, Lum SS. Trends in the Diagnosis of Phyllodes Tumors and Fibroadenomas Before and After Release of WHO Classification Standards. *Ann Surg Oncol*. 2018 Oct 1;25(10):3088–95.
2. Tummid S, Kothari K, Agnihotri M, Naik L, Sood P. Fibroadenoma versus phyllodes tumor: A vexing problem revisited! *BMC Cancer*. 2020 Jul 13;20(1).
3. Zhou ZR, Wang CC, Sun XJ, Yang ZZ, Chen XX, Shao ZM, et al. Prognostic factors in breast phyllodes tumors: a nomogram based on a retrospective cohort study of 404 patients. *Cancer Med*. 2018 Apr 1;7(4):1030–42.
4. Thind A, Patel B, Thind K, Isherwood J, Phillips B, Dhaliwal K, et al. Surgical margins for borderline and malignant phyllodes tumours. Vol. 102, *Annals of the Royal College of Surgeons of England*. Royal College of Surgeons of England; 2020. p. 165–73.
5. Slodkowska E, Nofech-Mozes S, Xu B, Parra-Herran C, Lu FI, Raphael S, et al. Fibroepithelial lesions of the breast: a comprehensive morphological and outcome analysis of a large series. *Mod Pathol*. 2018 Jul 1;31(7):1073–84.
6. Stoffel E, Becker AS, Wurnig MC, Marcon M, Ghafoor S, Berger N, et al. Distinction between phyllodes tumor and fibroadenoma in breast ultrasound using deep learning image analysis. *Eur J Radiol Open*. 2018 Jan 1;5:165–70.
7. Mitus JW, Blecharz P, Jakubowicz J, Reinfuss M, Walasek T, Wysocki W. Phyllodes tumors of the breast. The treatment results for 340 patients from a single cancer centre. *Breast*. 2019 Feb 1;43:85–90.
8. Ditsatham C, Chongruksut W. Phyllodes tumor of the breast: Diagnosis, management and outcome during a 10-year experience. *Cancer Manag Res*. 2019;11:7805–11.
9. Toussaint A, Piaget-Rossel R, Stormacq C, Mathevet P, Lepigeon K, Taffé P. Width of margins in phyllodes tumors of the breast: the controversy drags on?—a systematic review and meta-analysis. Vol. 185, *Breast Cancer Research and Treatment*. Springer; 2021. p. 21–37.
10. Ng CCY, Md Nasir ND, Loke BN, Tay TKY, Thihe AA, Rajasegaran V, et al. Genetic differences between benign phyllodes tumors and fibroadenomas revealed through targeted next generation sequencing. *Mod Pathol*. 2021 Jul 1;34(7):1320–32.
11. Johnson RH, Anders CK, Litton JK, Ruddy KJ, Bleyer A. Breast cancer in adolescents and young adults. Vol. 65, *Pediatric Blood and Cancer*. John Wiley and Sons Inc.; 2018.
12. Singer A, Tresley J, Velazquez-Vega J, Yepes M. Unusual aggressive breast cancer: Metastatic malignant phyllodes tumor. *J Radiol Case Rep*. 2013;7(2):24–37.
13. Mituš JW, Blecharz P, Walasek T, Reinfuss M, Jakubowicz J, Kulpa J. Treatment of Patients with Distant Metastases from Phyllodes Tumor of the Breast. *World J Surg*. 2016 Feb 1;40(2):323–8.
14. Ramakant P, Selvamani, Therese MM, Paul MJ. Metastatic malignant phyllodes tumor of the breast: An aggressive disease—Analysis of 7 cases. *Indian J Surg Oncol*. 2015 Dec 1;6(4):363–9.
15. Kim JY, Yu JH, Nam SJ, Kim SW, Lee SK, Park WY, et al. Genetic and Clinical Characteristics of Phyllodes Tumors of the Breast. *Transl Oncol*. 2018;11(1):18–23.
16. Tao L, Schwab RB, Miguel YS, Gomez SL, Canchola AJ, Gago-Dominguez M, et al. Breast cancer mortality in older and younger patients in California. *Cancer Epidemiol Biomarkers Prev*. 2019 Feb 1;28(2):303–10.
17. Wang MX, Ren JT, Tang LY, Ren ZF. Molecular features in young vs elderly breast cancer patients and the impacts on survival disparities by age at diagnosis. *Cancer Med*. 2018 Jul 1;7(7):3269–77.