

ORIGINAL ARTICLE

The Outcome of Titanium Elastic Nail in Pediatric Femoral Diaphyseal Fracture in a Tertiary Care Hospital

AFFAN TAYYAB¹, BABAR JAN², DILEEP KUMAR³, FAHEEM AHMED⁴, SHAKEEL GUL⁵, MALIK NAVEED IQBAL⁶¹Fellow Orthopedic Surgery, Shaheed Mohtarma Benazir Bhutto Institute Of Trauma, Karachi²Fellow Orthopedic Surgery, Shaheed Mohtarma Benazir Bhutto Institute Of Trauma, Karachi³RESIDENT MEDICAL OFFICER, SHAHEED MOHTARMA BENAZIR BHUTTO INSTITUTE OF TRAUMA, KARACHI⁴Consultant Orthopedic Surgeon, Shaheed Mohtarma Benazir Bhutto Institute Of Trauma, Karachi^{5,6}RESIDENT MEDICAL OFFICER, SHAHEED MOHTARMA BENAZIR BHUTTO INSTITUTE OF TRAUMA, KARACHI

Corresponding author: Affan Tayyab

Abstract

Objective: To determine the outcome of titanium elastic nail in pediatric femoral Diaphyseal fracture in a tertiary care hospital.**Study Design:** A longitudinal study**Place and Duration:** The Department of Orthopedics, Shaheed Mohtarma Benazir Bhutto Institute of Trauma, Karachi from 5th January 2022 to 4th July 2022.**Methodology:** A total of 126 Patients with femoral shaft fractures who were hospitalized were included. Through a little incision, an intramedullary nail was pushed into the canal. Union and callus formation were monitored with serial radiographs, and weight bearing was gradually increased based on fracture healing. The chi-square test and stratification were utilized to attain this result. A significance level of 0.05 was used.**Results:** There were 76.2% male and 23.8% female. The mean nail diameter, radiological union, limb length discrepancy and angulation were 3.31 ± 0.32 mm, 8.71 ± 1.44 weeks, 1.09 ± 0.81 cm and $5.43\pm 2.63^\circ$ respectively. The mean follow-up was 4.30 ± 1.06 months. The pain was observed in 15.1% of children while in 66.7% of cases no complications were observed. A total of 66.7% of cases were with excellent, 18.3% with good and 15.1% with poor outcome.**Conclusion:** Titanium elastic nails have a high probability of good and excellent outcomes in children and it is a simple, minimally invasive implant technique.**Keywords:** Outcome, Titanium Elastic Nail, Pediatrics, Femoral Diaphyseal Fracture.

INTRODUCTION

Children commonly suffer diaphyseal femur fractures. Overall 2% of childhood fractures are from it. Children often attend the emergency room for femur injuries¹⁻⁵. Boys are more injured than girls. A fall could cause injury. Low-velocity trauma causes transverse fractures, while high-velocity trauma causes segmental fractures^{1, 6}. If the child's bones are appropriately aligned, the break will heal quickly and without complications.

Different fracture kinds and ages require different treatments. External fixing, submuscular plating, lodged nailing, and intramedullary nailing⁹⁻¹² are examples. These procedures have successfully treated these fractures, however, they vary in stability and potential consequences. Fixation1 seeks to preserve physis, reduce anatomy, and achieve stable fixation. Children younger than 6 years old usually get a Spica cast or traction first. Teenagers with mature skeletons undergo anterograde solid intramedullary nailing.^{2, 14, 15} 6-12-year-old children are heavier than those under 6 years of age. They have trouble accepting casts, complicating treatment. Locked intramedullary nails can treat femoral shaft fractures in children with fully developed bones.

Titanium Elastic Nailing (TEN) has been used in Europe for over 20 years to treat children's femur fractures^{2, 16}. In the US, titanium elastic nails are used to treat children's diaphyseal femur fractures.^{2, 17} The physis is respected, the patient can walk and bear weight sooner, the scar heals well, the implant is easy to remove, and the patient is delighted with the results.^{11, 18} Several studies^{12, 19-21} have explored the effectiveness and safety of this technique in individuals⁶⁻¹⁶.

Flexible intramedullary nails are popular for treating children's femoral shaft fractures. To support the bone, stainless steel or titanium elastic nails are inserted into the medullary canal. While not a tight fixation, it increases callus development, which improves healing¹.

Twenty-two children ages 6 to 16 years of age with femoral diaphyseal fractures were studied (TEN). Flynn's criteria for evaluating efficacy provided good ratings in 13 (59.0%) cases, good in six (27.2%), and poor in three (13.6%) cases.³

A review of existing literature regarding the outcome of operative stabilization of titanium elastic in pediatric femoral Diaphyseal fracture revealed that no local data is available in Pakistan. Using a Titanium Elastic Nail requires proper equipment

for nail Insertion along with an Image Intensifier available in a few specialized centers. Hence it is a more costly alternative to managing a patient in a Hip Spica or even plating. On the other hand, it has its own advantages as already discussed. Also, management in a hip Spica for example requires good hygiene practices which are not followed by parents belonging to a lower socioeconomic class than ours resulting in plaster complications which in turn translate into the added cost. Therefore, the purpose of this study is to determine the outcome of titanium elastic nails in pediatric femoral Diaphyseal fractures in our population as this will help to develop management guidelines, and treatment protocols to highlight the importance of stabilization of femur fractures by titanium elastic nails for the local population.

METHODOLOGY

The research was conducted between Jan 5th, 2022, and July 4th, 2022, in the Orthopedics Department of the Shaheed Mohtarma Benazir Bhutto Institute of Trauma in Karachi. We used World Health Organization (WHO) software and a 95% confidence interval to determine that there were 126 patients in the sample. The percentage of children who had unfavourable outcomes after suffering Diaphyseal femur fractures (P=13.6%, d=6%) led to this conclusion. It was accomplished by a strategy that did not rely upon chance.

This research was conducted after receiving clearance from the CPSP and the hospital's ethical review committee. The study involved children with femoral shaft fractures who have been seen in the orthopedics department at Shaheed Mohtarma Benazir Bhutto Institute of Trauma in Karachi during the preceding three days and who meet the inclusion criteria. Primary investigators were responsible for gathering patient demographics, medical history, and examination results. A titanium elastic nail is used to treat children's femoral diaphyseal fractures that occurred during the preceding three days (TEN).

A custom-made metal rod is implanted into the marrow canal of the femur during this treatment. The rod is placed into the fracture and holds the fragment in place. A minor incision was made in the patient's hip or knee so that an intramedullary nail (also known as a TEN) could be placed into the corresponding canal. Flynn's algorithm was used to calculate the diameter of each nail. Intraoperative evaluation ((width of the narrowest point

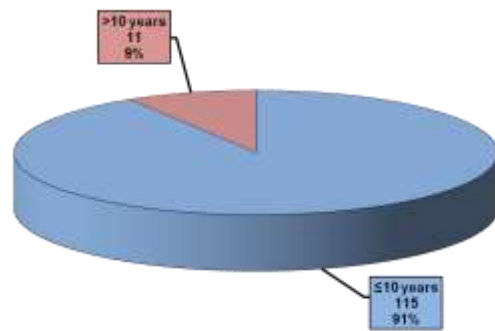
of the medullary canal on anteroposterior and lateral view x 0.4 mm)). Nail diameter equals medullary canal width in anteroposterior and lateral views. Each nail's size was meticulously chosen to occupy between one-third and forty percent of the medullary cavity. The nail's tip was also sent to aid in insertion, as it can be used to help prevent the nail from ricocheting off the opposite cortex. Additionally, this allowed the nail ends in the proximal femoral metaphysis to extend out more freely. After the broken region was minimized, the nail was driven into the proximal piece of bone. Once every six weeks, x-rays were taken to monitor the union and callus formation. Patients were given clearance to put all their weight on the repaired fracture once their callus had grown to the proper size. Any problems, no matter how little, were looked for using Flynn's criteria and operational definition, and all patients were re-examined after 6 months. We were able to keep bias and effect modifiers at bay by being very careful with our inclusion and exclusion criteria.

Social science statistical software, version 21, was used to compile and evaluate patient data (SPSS). Quantitative features including gender, femur side, femur position, pain status (present or absent), complications, and outcomes were given frequencies and percentages. Age, nail diameter, duration of radiological union, duration of follow-up, limb length discrepancy, and angle were all measured quantitatively to determine their means and standard deviations. In order for the Chi-square test to establish the significance of the potential effects of the demographic factors of gender, age, and orientation on the results, the data had to be stratified accordingly. A p-value of 0.05 was considered to be statistically significant.

RESULTS

Research into the effectiveness of using a titanium elastic nail to treat a child's femoral diaphyseal fracture was carried out in a

tertiary care hospital, and 126 patients aged 6 to 16 years of age participated in the study. Overall, there were 126 patients, with males making up 76.2% and females making up 23.8%. On average, the age of a patient was 9.8 years old, while their ages ran as low as 8.301 years. Ages are quantified in Table 1. One more classification was made by using age as a criterion. Graph 1 shows the breakdown of all the numbers. Nail diameter was 3.31±0.32 millimeters on average, the radiological union lasted 8.71±1.44 weeks, limb length discrepancy was 1.09 ±0.81 centimeters, and angulation was 5.43±2.63 degrees. Additionally, table 1 provides descriptive data on nail diameter, radiological union, limb length discrepancy, and angle led to the formation of further groups. As a whole, we followed up with everyone after an average of 4.30±1.06 months.



Graph 1: Percentage of Patients According To Age Groups (n=126)

Table 1: Descriptive Statistics

| | Descriptive Statistics | | | | | |
|------------------------------|------------------------|--------------------|--------|---------|---------|-------|
| | Mean | Standard deviation | Median | Minimum | Maximum | Range |
| Age (years) | 8.30 | 1.98 | 8.00 | 6 | 13 | 7 |
| Nail diameter (mm) | 3.31 | 0.32 | 3.50 | 2.50 | 4 | 1.50 |
| Radiological Union (weeks) | 8.71 | 1.44 | 8.00 | 6 | 12 | 6 |
| Limb Length Discrepancy (cm) | 1.09 | 0.81 | 0.80 | 0.20 | 3.00 | 2.80 |
| Angulation (degree) | 5.43 | 2.65 | 4.50 | 3 | 12.90 | 9.90 |
| Follow Up (Months) | 4.30 | 1.06 | 4.00 | 2 | 6 | 4 |

Table 2: Frequency Distribution

| | Frequency Distribution | | | Total |
|--------------|------------------------|------------|-----------|-------|
| | Frequency (%) | | | |
| Femur Side | Left | Right | | 126 |
| | 46 (36.5) | 80 (63.5) | | |
| Femur Site | Proximal | Middle | Distal | 126 |
| | 17 (13.5) | 86 (68.3) | 23 (18.3) | |
| Pain | Present | Absent | | 126 |
| | 19 (15.1) | 107 (84.9) | | |
| Complication | Absent | Mild | Major | 126 |
| | 84 (66.7) | 23 (18.3) | 19 (15.1) | |
| Outcome | Excellent | Good | Poor | 126 |
| | 84 (66.7) | 23 (18.3) | 19 (15.1) | |

Table 1 provides numerical summaries of the following occurrences. From the data in Table 2, we can see that of the 126 children analyzed, 36.5 percent had an issue with their left femur and 63.5 percent with their right femur. However, 68.3 percent of femur fractures occurred in the middle of the thigh bone. Of the 126 children evaluated, 15.1% were complaining of pain, while the other 66.7% had no complaints. Taking a look at Table 2 can give you an idea of how often you may experience certain types of discomfort and issues. Overall, positive results accounted for 66.7%, while neutral outcomes made up 18.3% and negative ones for 15.1%. Using a stratified sampling method, we analyzed the impact of age, gender, femur side, femur location, and femur angle on the outcome. The general consensus was that a p-value of 0.05

or less indicated statistical significance. There was a statistically significant association between gender (p = 0.000), femur position (p = 0.000), and angle (p = 0.000), as demonstrated by the results. The data for the associations are shown in Table 3, despite the lack of a statistically significant relationship between age and femur side (p=0.054) and (p=0.342).

Table 3: Frequency and Association

| Gender | Outcome | | | | P Value |
|----------------------------------|-----------|-----------|-----------|------------|----------|
| | Excellent | Good | Poor | Total | |
| Male | 66 (78.6) | 11 (47.8) | 19 (100) | 96 (76.2) | 0.000 * |
| Female | 18 (21.4) | 12 (52.2) | 0 (0) | 30 (23.8) | |
| Total | 84 | 23 | 19 | 126 | |
| *Significant at 0.05 level. | | | | | |
| Age | Outcome | | | | P Value |
| | Excellent | Good | Poor | Total | |
| ≤10 Years | 77 (91.7) | 23(100) | 15 (78.9) | 115 (91.3) | 0.054 ** |
| >10 Years | 7 (8.3) | 0(0) | 4(21.1) | 11 (8.7) | |
| Total | 84 | 23 | 19 | 126 | |
| **Not Significant at 0.05 level. | | | | | |
| Side of femur | Outcome | | | | P Value |
| | Excellent | Good | Poor | Total | |
| Left | 30 (35.7) | 11(47.8) | 5(26.3) | 46(36.5) | 0.342 ** |
| Right | 54 (64.3) | 12(52.2) | 14(73.7) | 80 (63.5) | |
| Total | 84 | 23 | 19 | 126 | |
| **Not Significant at 0.05 level. | | | | | |
| Site of femur | Outcome | | | | P Value |
| | Excellent | Good | Poor | Total | |
| Proximal | 12(14.3) | 0(0) | 5(26.3) | 17(13.5) | 0.000 |

| | | | | | |
|-----------------------------|-----------|----------|-----------|-----------|------------|
| Middle | 60(71.4) | 12(52.2) | 14 (73.7) | 86(68.3) | * |
| Distal | 12(14.3) | 11(47.8) | 0(0) | 23 (18.3) | |
| Total | 84 | 23 | 19 | 126 | |
| *Significant at 0.05 level. | | | | | |
| Angulation | Outcome | | | | P Value |
| | Excellent | Good | Poor | Total | |
| <5° | 84(100) | 0(0) | 0(0) | 84 | 0.000 * |
| 5-10° | 0(0) | 24(100) | 0(0) | 24 | |
| >10° | 0(0) | 0(0) | 19(100) | 19 | |
| Total | 84 | 24 | 19 | 126 | |
| *Significant at 0.05 level. | | | | | |

Chi-Square Test was applied.
P-values≤0.05 is considered significant.

DISCUSSION

Femoral shaft fractures account for 2% of pediatric fractures, yet clinicians have struggled to treat them. Previously, traction and casting were the gold standards for treating diaphyseal femoral fractures in children and adolescents.⁸ This technique has lasted so long because it's secure and has few flaws that could impair its efficacy. Orthopedic surgeons have tried many techniques to reduce bedrest and improve post-operative care. Recent research examined the financial and emotional effects of Spica casts on children and their families.⁹

Flexible intramedullary nailing has shown potential for broken bones. Titanium elastic nail is superior to other surgical methods in this age range because it is a load-sharing internal splint that doesn't break open physis, permits early movement, and maintains bones in place. Due to fixation flexibility, the external bridging callus occurs faster.¹⁰

Since this is a closed procedure, neither the periosteum nor fracture hematoma must be moved. Infection risk decreases. The average operation time is 46 minutes, with other studies showing 45 and 55 minutes. Saikia et al. (70 minutes), Mann et al. (94 minutes), and Bar-On et al (74 minutes). When a closed reduction fails, an open reduction is needed to remedy the problem. The average hospital stay was 10.5 days, with the median being 9 days.¹¹

This was much longer than Ann Ho et al (5.5 days). Saikia et al. found similar results in India (9.8 days). Herndon et al. found that non-surgical patients spent 28 days in the hospital compared to 17 for surgical patients. Children treated with titanium elastic nails spent less time in the hospital, walked with support earlier, and returned to school sooner than those treated with traction and a cast.¹²

Only four people needed a hip Spica after surgery. Three patients required a derotation splint. Titanium elastic nails have good rotational stability and didn't need immobilization. External stabilization is determined by surgeons. In research, bridging calluses appeared after 4.53 weeks on average. This trial was lengthier than the Flynn et al. trial, which lasted 4 weeks (3 weeks). Jalan et al. observed that partial and full weight bearing last 4.56 and 6.86 weeks, respectively.¹³⁻¹⁵

Early mobilization reduces hospitalization, school absences, joint stiffness, and muscle atrophy. X-rays and patient reports of pain-free weight bearing demonstrate union after 6.86 weeks.¹⁶

After that, patients could fully weight-bear on their legs. Flynn et al., Cramer et al., Mann et al., and Galpin et al. found no delayed and nonunion cases. A total of 90% of study participants had a full knee range of motion after 12 weeks. Overall 10% of knees permanently confined to 20-30 degrees improved after nail removal. Patients were instructed to do stretches, hip abductor exercises, and knee extensor exercises at home before surgery.¹⁷⁻¹⁹

Three of the four lengthening cases included children ages 6 to 10 years, and the other involved teenagers. Ann Ho and colleagues found that following more patients reduced lengthening (10 cases at 12 months and 3 cases at 18 months). Further monitoring is needed to determine the true calf length differential among patients. Only 6 people studied had misalignment, and none was more than 10 degrees wrong.¹⁹⁻²⁰

The first three had different-sized nails. When bent in the same direction, nails of different thicknesses provide different restoring forces, causing the proximal fragment to varus or valgus. Always use nails of the same thickness and bent to avoid this. The last three fractures did not align with the curve's apex. Overall 7 of 24 people treated with traction did not recover effectively, but none of the 21 children treated with intramedullary nailing did. In 5 cases, nails were too long and bent, and in 2 cases, insertion sites were too deep.²¹

When insertion points are too close to the bone, muscles often hurt. Too-long nails in the femoral end can obstruct the iliotibial tract, making knee bending difficult. Everyone who has this condition got their nails cut. According to Luhmann et al., technical challenges can be minimized if the nail protruding from the femur is less than 2.5 cm. Straightened nail tips reduce insertion pain. Ligier et al. (10.5%) and Flynn et al. (6.8%) found the same.⁹⁻¹¹

In Jalan et al investigation's nails had no wriggle room. Titanium nails don't budge, whereas titanium elastic nailing needs balancing the strains of two flexible implants. Ender nails that stack the medullary canal are shiftier. One person got a mild infection near the entry, which responded satisfactorily to antibiotic therapy over a week. No infections worsened.²²

The perineum wasn't appropriately cushioned during intraoperative stress, causing a vulval hematoma. Then, safeguards and padding were added. This investigation revealed the failure of closed reduction. If surgery takes longer than expected, use traction. One patient experienced cork screw surgery. A fresh, correctly put nail replaced the destroyed one. After 6 months, the nails were surgically removed without issues. Nails have been removed as early as 6 weeks after surgery. Early nail removal can induce refracture, and if it doesn't, it may have been done too late.²¹⁻²⁵

CONCLUSION

Our research shows that titanium elastic nails are an excellent physeal-protecting implant device for children, with a large percentage of cases producing satisfactory or even extraordinary results. Because of this, patients spend a significantly shorter amount of time in the hospital and are discharged from the facility sooner. Aside from the cost savings associated with medical care, this also has societal and financial benefits.

Funding Source: None

Conflict: No conflict of interest

Ethical Approval: It was taken from the ethical review committee

REFERENCES

- Mishra AK, Chalise PK, Shah SB, Adhikari V, Singh RP. Diaphyseal femoral fractures in children treated with titanium elastic nail system. *Nepal Med Coll J.* 2012; 15(2):95-7.
- Moroz LA, Launay F, Kocher MS, Newton PO, Frick SL. Titanium elastic nailing of fractures of the femur in children predictors of complications and poor outcome. *J Bone Joint Surg.* 2006; 88(10):1361-6.
- Saikia KC, Bhuyan SK, Bhattacharya TD, Saikia SP. Titanium elastic nailing in femoral diaphyseal fractures of children in 3-16 years of age. *Indian J Orthop.* 2007; 41(4):381.
- Baldwin K, Hsu JE, Wenger DR, Hosalkar HS. Treatment of femur fractures in school-aged children using elastic stable intramedullary nailing: a systematic review. *J PediatrOrthop.* 2011; 20(5):303-8.
- Eapen J, Selvam N, Lingaraj SN. Titanium elastic nailing in femoral diaphyseal fractures of children 3 to 14 years of age: long term follow up. *Stanley Med J.* 2015; 2(2):6-11.
- Bridgman S, Wilson R. Epidemiology of femoral fractures in children in the West Midlands region of England 1991 to 2001. *J Bone Joint Surg Brit.* 2004; 86:1152-7.
- Sheikh SI, Ullah M, Khan A, Iqbal J. Ender's nail for Diaphyseal long bone lower limb fractures in children. *J Rawalpindi Med Coll.* 2012; 16:25-7.
- Kanellopoulos AD, Yiannakopoulos CK, Soucaos PN. Closed, locked intramedullary nailing of pediatric femoral shaft fractures through the tip of the greater trochanter. *J Trauma.* 2006; 60:217-2.

9. Ligier JN, Metaizeau JP, Prevot J, Lascombes P. Elastic stable intramedullary nailing of femoral shaft fractures in children. *J Bone Joint Surg Brit.* 1988; 70:74-7.
10. Flynn JM, Hresko T, Reynolds RAK, Blasier D, Davidson R, Kasser J. Titanium elastic nails for pediatric femur fractures: a multicenter study of early results with analysis of complications. *J Pediatr Orthop.* 2001; 21:4-8.
11. Cramer KE, Limbird TJ, Green NE. Open fractures of the diaphysis of the lower extremity in children. Treatment, results, and complications. *J Bone Joint Surg Am.* 1992; 74(2):218-32.
12. Flynn JM, Skaggs DL, Sponseller PD. The surgical management of paediatric fractures of the lower extremity. *Instr Course Lect* 2003; 52: 647-59.
13. Salem KH, Lindemann I, Keppler P. Flexible intramedullary nailing in paediatric lower limb fractures. *J Paediatr Orthop* 2006; 26(4):505-9.
14. Heybeli M, Muratli HH, Celebi L. The results of intramedullary fixation with titanium elastic nails in children with femoral fractures. *Acta Orthop Traumatol Turc* 2004; 38(3):178-87.
15. Mann DC, Weddington J, Davenport K. Closed Ender nailing of femoral shaft fractures in adolescents. *J Paediatr Orthop* 1986; 6(6):651-5.
16. Bar-On E, Sagiv S, Porat S. External fixation or flexible intramedullary nailing for femoral shaft fracture in children. *J Bone Joint Surg Br* 1997; 79(6):975-8.
17. Ann Ho C, Skaggs DL, Tang CW. Use of flexible intramedullary nails in paediatric femur fractures. *J Paediatr Orthop* 2006; 26(4):497-504.
18. Herndon WA, Mahnken RF, Yngve DA. Management of femoral shaft fractures in the adolescent. *J Paediatr Orthop* 1989; 9(1):29-32.
19. Cramer KE, Tornetta P 3rd, Spero CR. Ender rod fixation of femoral shaft fractures in children. *Clin Orthop Relat Res* 2000 ; (376):119-23.
20. Luhmann SJ, Schootman M, Schoenecker P. Complications of titanium elastic nails for paediatric femoral shaft fractures. *J Paediatr Orthop* 2003; 23(4):443-7.
21. Houshian S, Gothgen CB, Pedersen NW. Femoral shaft fractures in children: elastic stable intramedullary nailing in 31 cases. *Acta Orthop Scand* 2004; 75(3):249-51.
22. Reeves RB, Ballard RI, Hughes JL. Internal fixation versus traction and casting of adolescent femoral shaft fractures. *J Paediatr Orthop* 1990; 10(5):592-5.
23. Hughes BF, Sponseller PD, Thompson JD. Paediatric femur fractures: effect of spica cast treatment on family and community. *J Paediatr Orthop* 1995; 15(4):457-60.
24. Miner T, Carroll KL. Outcomes of external fixation of pediatric femoral shaft fractures. *J Pediatr Orthop.* 2000; 20(3):405-10.
25. Hedin H, Hjorth K, Rehnberg L, Larsson S. External fixation of displaced femoral shaft fractures in children: a consecutive study of 98 fractures. *J Orthop Trauma.* 2003; 17(4):250-6.