

Surgical Outcome and Complication of Penile Fracture

SHAHEER AHMAD KHAN¹, MUHAMMAD SHOAB KHAN², ZESHAN AHMAD³, IQBAL SHAHZAD⁴, ABDULLAH⁵, MUHAMMAD MOHSIN AYZAZ⁶

¹Senior Registrar, DHQ Teaching Hospital, KDA, Kohat

²Consultant Surgeon, General Surgery Department, DHQ Hospital Batkhela

³Senior Registrar Urology, Lahore General Hospital, Lahore, PMDC 54056-P

⁴Assistant Professor and Consultant Urologist, Department of Urology, Liaquat National Hospital Karachi, Sind

⁵Assistant Professor Urology, Urology Department, P.O.F Hospital Wah Cant

⁶Medical Officer, DHQ Karak, KPK

Corresponding author: Muhammad Shoaib Khan, Email: shoaib061@gmail.com

ABSTRACT

Objective: The aim of current study is to determine the causes, symptoms of penile fracture and post-operative outcomes.

Study Design: Prospective study

Place and Duration: This study was conducted at multi centers at DHQ Teaching Hospital, KDA, Kohat and DHQ Hospital Batkhela during the period from February, 2022 to July, 2022.

Methods: Total 30 patients had penile fracture were presented in this study. Included cases were aged between 20-50 years. After receiving informed written permission, detailed demographic information about the enrolled patients was compiled, including age, body mass index, place of residence, and marriage status. Causes and clinical features of fracture were assessed. Patients were underwent for surgery and success rate was observed. Post-treatment rate of complications among enrolled cases were also calculated. We used SPSS 22.0 version to analyze complete data

Results: Included patients had mean age 35.7 ± 12.32 years with mean BMI 24.7 ± 4.31 kg/m². Majority of the cases were married 26 (86.7%) and rest were unmarried 4 (13.3%). 12 (40%) patients had urban residency and majority were had rural 18 (60%). Most common cause of fracture was coital 20 (66.7%), followed by masturbation in 6 (20%) and 4 (13.3%) patients had manipulation during sleep. Deformity, swelling, detumescence and crackling sound was the most common symptoms. Right corpus was the most common tunical tear 24 (80%) and most common site was proximal 22 (73.3%). Success rate was found among 26 (86.7%) cases. Post-operatively complications were found among 5 (16.7%) cases in which plaques/ nodules, curvature, erectile dysfunction, pain and swelling were included.

Conclusion: For the purposes of this study, we found the penis fracture to be a rather simple condition to diagnose. Cavernosography may be used to confirm a diagnosis if necessary. Penile fractures may be successfully treated with immediate primary surgical repair, resulting in normal erection without substantial sequelae. Short hospital stays and fast restoration of sexual function are common outcomes of this procedure.

Keywords: Surgical Outcomes, Penile Fracture, Complications, Causes

INTRODUCTION

One in every 175,000 [1] people will present with a penile fracture, making it a rare presentation to Urology departments. When the penis touches the perineum during sexual contact, the tunica albuginea in the corpora cavernosum is ruptured. Masturbation and intercourse are the most prevalent causes of tunica albuginea rupture. Some of the other reasons include turning over in bed on the erect penis, forceful bending to induce detumescence, and external physical trauma [2]. However, no systematic research has been conducted to support the generally held belief that women who sit in the 'woman on top' posture are at the highest risk of penile fracture. [3] According to an examination of the literature, it seems that the cause of penile fracture varies according to geographic location [3]. Many of the documented occurrences in several Middle Eastern nations are the result of patients 'kneading and snapping' the erect penis in order to achieve quick detumescence in inappropriate conditions [2, 4, 5]. One Iranian research found that 269 of 352 individuals (76 percent) developed a penile fracture as a result of this practise (also known as 'Taqaadan') [5]. This is the most common example of this practise (also known as Taqaadan).

Tunica thins from 2mm to 0.25mm when the spine is in the upright position, making it more susceptible to trauma-induced rip. In the case of a penile fracture, urethral damage is rather rare. [6] Injury to the erect penis during coitus, masturbation and unintentional nocturnal penile manipulations or turning over in bed are the most typical causes. [7,8] On inspection, there is a popping or cracking sound, as well as substantial pain and quick detumescence. There is also swelling and bruising, as well as a lateral deformity and hematoma, which are all suggestive of a traumatic injury. An accompanying urethral injury is indicated by urethral haemorrhage. It is clinically determined that the patient has tunical tear, and probing of a localised clot over the location of the tear is pathognomic for the diagnosis. [7,10] There have also

been situations when cavernosography and penile ultrasonography have been employed, as well as magnetic resonance imaging (MRI). [7,11] In spite of the controversy, rapid surgical exploration and repair is universally acknowledged as the treatment of choice in penile fractures and is considered preferable to non-operative treatment in almost all cases. [1,8,12]

The observation that the frequency of cases of penile fracture is increasing led us to investigate the clinical presentation, diagnosis, and surgical approach used in patients with penile fracture in our setting, as well as the intra-operative findings and post-operative complications that may arise.

MATERIAL AND METHODS

This prospective study was conducted at DHQ Teaching Hospital, KDA, Kohat and DHQ Hospital Batkhela during the period from February, 2022 to July, 2022 and comprised of 30 patients had penile fracture. After receiving informed written permission, detailed demographic information about the enrolled patients was compiled, including age, body mass index, place of residence, and marriage status. Patients had history of surgery and those did not give written consent were not included in this study.

Included cases were aged between 20-50 years. Patients were subjected to a full assessment, which included obtaining a medical history and physical, as well as RGU (retrograde urethrography) for suspected urethral damage and cavernosography if there was any question. To ensure consistency in patient care, all patients were treated with the same standard operative technique, which included thorough examination of all three corpora and the urethra through a subcoronal degloving incision, thorough wound toilet, and corporal and tunical repair with interrupted inverted nonabsorbable sutures. The catheterization technique developed by Foley was used on all of the patients. It was removed on the second postoperative day after the surgery. The postoperative problems such as wound-related issues, penile

curvature, and nodule as well as voiding and sexual function status were assessed in all patients at 1, 3, 6, and 12 months after the surgery was performed. We used SPSS 22.0 version to analyze complete data.

RESULTS

Included patients had mean age 35.7±12.32 years with mean BMI 24.7±4.31 kg/m². Majority of the cases were married 26 (86.7%) and rest were unmarried 4 (13.3%). 12 (40%) patients had urban residency and majority were had rural 18 (60%).(table 1)

Table 1: Baseline characteristics of enrolled cases

Variables	Frequency	Percentage
Mean age (years)	35.7±12.32	
Mean BMI (kg/m ²)	24.7±4.31	
Married		
Yes	26	86.7
No	4	13.3
Living Place		
Urban	12	40
Rural	18	60

Most common cause of fracture was coital 20 (66.7%), followed by masturbation in 6 (20%) and 4 (13.3%) patients had manipulation during sleep.(fig 1)

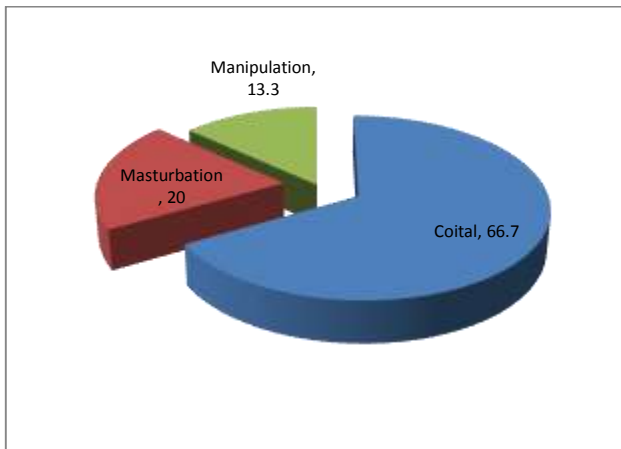


Figure 1: Causes of penile fracture

Deformity, swelling, detumescence and crackling sound was the most common symptoms.(table 2)

Table 2: Clinical features of enrolled cases

Variables	Frequency	Percentage
Deformity	24	80
Detumescence	22	73.3
Swelling	17	56.7
Crackling Sound	14	46.7

Right corpus was the most common tunical tear 24 (80%) and most common site was proximal 22 (73.3%).(table 3)

Table 3: Operative findings among enrolled cases

Variables	Frequency	Percentage
Tunica tear		
Right corpus	24	80
Left corpus	4	13.3
Bilateral	2	6.7
Site		
Proximal	22	73.3
Mid Shaft	5	16.7
Distal	3	10

Success rate was found among 26 (86.7%) cases.(fig 2)

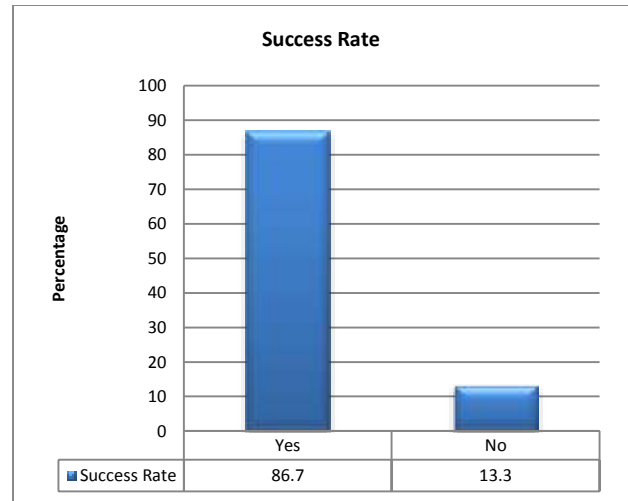


Figure 2: Post surgery success rate among cases

Post-operatively complications were found among 5 (16.7%) cases in which plaques/ nodules, curvature, erectile dysfunction, pain and swelling were included.(table 4)

Table 4: Association of complications among cases

Complications	Frequency	Percentage
pain and swelling	2	6.7
erectile dysfunction	1	3.3
curvature	1	3.3
plaques/ nodules	1	3.3
Total	5	16.7

DISCUSSION

Although penile fractures are rare, they may have catastrophic physical, functional, psychological, and social effects. For the first time, a comprehensive examination of the aetiology, signs and symptoms, and treatment options for this unusual urological emergency is being conducted using a meta-analysis. Doctors have traditionally preferred conservative treatment, however research provided shows that early surgical repair results in much better outcomes than conservative treatment or delaying surgery.

In this prospective study 30 cases of penile fracture with ages 20-50 years were included. Mean age was 35.7±12.32 years with mean BMI 24.7±4.31 kg/m². Majority of the cases were married 26 (86.7%) and rest were unmarried 4 (13.3%). 12 (40%) patients had urban residency and majority were had rural 18 (60%). Our findings showed resemblance to the previous researches.[13,14] According to Kumar et al., 45 percent of the patients were between the ages of 30 and 40. In a research by Mahapatra et al., 40% of penile fracture patients were between the ages of 21 and 30. [16] Half of the patients were between the ages of 31 and 40 in our research as well.

Most common cause of fracture was coital 20 (66.7%), followed by masturbation in 6 (20%) and 4 (13.3%) patients had manipulation during sleep.[13-16] Kochakarn W et al, reported 83% cases of penile fractures during intercourse and coital trauma to erect penis was the most common cause of fracture in other studies also.[17] Others reported manipulation of erect penis to achieve detumescence as the common mechanism for penile fracture.[18]Deformity, swelling, detumescence and crackling sound was the most common symptoms.[19,20] Right corpus was the most common tunical tear 24 (80%) and most common site was proximal 22 (73.3%). In current study success rate was found among 26 (86.7%) cases. In addition, Yapanoglu et al.[21] and Gamal et al.[22] showed that urgent surgical repair was preferable to conservative care in terms of favourable results. Nearly 90% of individuals in Kumar et al study 's who had favourable outcomes were investigated promptly. [15] Patients in Mahapatra et al. were

treated surgically in 95% of the cases, and they all recovered satisfactorily. [16]

Post-operatively complications were found among 5 (16.7%) cases in which plaques/ nodules, curvature, erectile dysfunction, pain and swelling were included.[13] This study's findings suggest that surgery may save hospitals money because of the shorter length of stay. In this study, several incisions, sutures, and approximation methods have been discovered. An inverted continuous 3/0 non-absorbable nylon suture was used in one research [23] and just one problem, a painless nodule, was observed in the 116 surgically treated patients. The subcoronal circumferential degloving incision is the most frequent. As a result, it seems that this method is preferred since it provides access to all three corpora [24].

CONCLUSION

For the purposes of this study, we found the penis fracture to be a rather simple condition to diagnose. Cavernosography may be used to confirm a diagnosis if necessary. Penile fractures may be successfully treated with immediate primary surgical repair, resulting in normal erection without substantial sequelae. Short hospital stays and fast restoration of sexual function are common outcomes of this procedure.

REFERENCES

- 1 Koifman L, Barros R, Júnior RA, Cavalcanti AG, Favorito LA: Penile fracture: diagnosis, treatment and outcomes of 150 patients. *Urology* 2010;76:1488–1492.
- 2 Ateyah A, Mostafa T, Nasser TA, Shaeer O, Hadi AA, Al-Gabbar MA: Penile fracture: surgical repair and late effects on erectile function. *J Sex Med* 2008;5:1496–1502.
- 3 Reis LO, Cartapatti M, Marmiroli R, de Oliveira Júnior EJ, Saade RD, Fregonesi A: Mechanisms predisposing penile fracture and long-term outcomes on erectile and voiding functions. *Adv Urol* 2014;2014:768158.
- 4 Jack GS, Garraway I, Reznichek R, Rajfer J: Current treatment options for penile fractures. *Rev Urol* 2004;6:114–120.
- 5 Zargooshi J: Sexual function and tunica albuginea wound healing following penile fracture: an 18-year follow-up study of 352 patients from Kermanshah, Iran. *J Sex Med* 2009;6:1141–1150.
- 6 Heng CT, Brooks AJ: Penile fracture with complete urethral rupture. *Asian J Surg* 2003; 26(2): 126-7.
- 7 Aman Z, Qayyum A, et al. Early surgical intervention in penile fracture. *J Postgrad Med Inst* 2004; 18(3): 432-8.
- 8 Gondal KM, Ali AA, Ranjani MA, et al. Management of penile trauma. *Ann KE Med Coll* 2001; 7(1): 47-9.
- 9 Kochakarn W, Viseshsindh V, Muangman V. Penile fracture: Long-term outcome of treatment. *J Med Assoc Thai* 2002; 85(2): 179-82.
- 10 Morris SB, Miller MA, Anson K. Management of penile fracture. *J Roy Soc Med* 1998; 91(8): 427-8.
- 11 Mydlo JH, Hayyeri M, Macchia RJ. Urothorgraphy and cavernosography imaging in a small series of penile fractures: a comparison with surgical findings. *Urology* 1998; 51(4): 616-9.
- 12 Muentener M, Suter S, Hauri D, Sulser T. Longterm experience with surgical and conservative treatment of penile fracture. *J Urol* 2004; 172(2): 576-9.
- 13 Shimpi, Rajendra K.; Patel, Pranay J.; Bhondave, Suraj T. Penile fracture, *Urology Annals: Oct–Dec 2021 - Volume 13 - Issue 4 - p 351-355*
- 14 Kulovac B, Aganović D, Junuzović D, et al. Surgical treatment and complications of penile fractures. *Bosn J Basic Med Sci.* 2007;7(1):37-39. doi:10.17305/bjbm.2007.3087
- 15 Kumar L, Tiwari R, Arya MC, Sandhu A, Vasudeo V, Baid M. A tertiary center experience of fracture penis: Early surgical management with a clinical diagnosis *Urol Sci.* 2018;29:298–302
- 16 Mahapatra RK, Ray RP, Mishra S, Pal DK. Urethrocuteaneous fistula following fracture penis *Urol Ann.* 2014;6:392–4
- 17 Kochakarn W, Viseshsindh V, Muangman V. Penile fracture: Long-term outcome of treatment. *J Med Assoc Thai* 2002; 85(2): 179-82
- 18 Blair BM, Vilson F, Kocher NJ, Kloniecke E, Clark JY. Longitudinal Rupture of Distal Corpus Cavernosum With Concomitant Urethral Injury: An Uncommon Result of a Common Mechanism. *Urology.* 2018 Aug 1; 118: e5-6.
- 19 Zargooshi J. Penile fracture in Kermanshah, Iran: report of 172 cases. *J Urol* 2000; 164(2): 364-6.
- 20 Chung CH, Szeto YK, Lai KK: 'Fracture' of the penis: a case series. *Hong Kong Med J* 2006; 12:197–200.
- 21 Yapanoglu T, Aksoy T, Adanur S, Kabadayi B, Ozturk G, Ozbey I. Seventeen years experience of penile fracture: Conservative vs. surgical treatment *J Sex Med.* 2009;6:2058–63
- 22 Gamal WM, Osman MM, Hammady A, Aldahshoury MZ, Hussein MM, Saleem M, et al Penile fracture: Long-term results of surgical and conservative management *J Trauma.* 2011;71:491–3
- 23 Ahmadnia H, Younesi Rostami M, Kamalati A, Imani MM: Penile fracture and its treatment: is retrograde urethrography necessary for management of penile fracture? *Chin J Traumatol* 2014;17:338–340.
- 24 Tijani KH, Ogo CN, Ojewola RW, Akanmu NO: Increase in fracture of the penis in southwest Nigeria. *Arab J Urol* 2012;10:440–444.