

First Molecular Identification of *Sarcocystis Buffalonis* in Goats Worldwide in Misan Governorate, Iraq

RAWAA G. MOHAMMED¹, MAYTHAM A. DRAGH², HASAN, M. H³

¹College of Education, University of Al-Hamdaniya, Iraq.

²Department of Microbiology, College of Veterinary Med, University of Mosul, Iraq.

³Department of Biology, College of Life Sciences, University of Misan, Iraq.

Correspondence to: Rawaa G. Mohammed, Email: rawaaghanim1978@gmail.com

ABSTRACT

The current study was conducted in Misan Governorate to detect the parasite *Sarcocystis* spp. by both conventional and molecular methods and to identify the species of this genus in goats as intermediate hosts for multiple species of this parasite. Regarding to the traditional study, the rates of infection with the macroscopic type of *Sarcocystis* spp. were low and recorded 2% in esophageal samples only in goats. The sizes of macroscopic parasite cysts ranged between 1-10 mm in length and 2-6 mm in width. Infection with the microscopic type of parasite recorded high rates. When comparing the efficiency of the traditional methods used in our study to diagnose the infection of the microscopic type in all of the examined organs isolated from goats, which included the methods of digestion with pepsin, squeezing, trichinoscopy. It was found that the method of digestion with pepsin was the most efficient traditional method for diagnosing the microscopic type of parasite, followed by the trichinoscopy. While the squeezing method recorded the least efficient traditional method for diagnosing *Sarcocystis* spp. microscopically.

The molecular study of *Sarcocystis* spp. included molecular diagnosis of the parasite's identity at the species level through gene amplification using polymerase chain reaction (PCR) of the target segment of DNA extracted from the parasite samples of goats for 18S rRNA gene by 120 microscopic samples and 4 macroscopic samples.

87.9% of goat samples, showed positive infection with the 18S rRNA gene; In which 100% of the macroscopic and microscopic samples of the esophagus were recorded, and both animals had a positive infection, while the infection rates for the diaphragm, tongue and heart samples were recorded as 90%, 86.7 and 80%, respectively.

The results obtained from sequence analysis of 18S rRNA gene for six samples showed that four microscopic samples of goats (OP474017.1, OP474018.1, OP476699.1 and OP474036.1) were closely related to the Malaysian species; *S. capracanis* with accession number (KR155191.1) with identity score percentages as 99.50%, 99.01%, 99.76% and 99.13%, respectively. Finally, the two macroscopic samples of goats (OP474061.1 and OP474062.1) were identical with the Egyptian species; *S. buffalonis*, with accession numbers (KU247913.1) and (KU247913.1) respectively, with a matching percentage of 84.39% and 85.64% respectively. *S. buffalonis* has identified in goats at the first time globally in present study.

Keywords: *Sarcocystis buffalonis*, Goats, OP474061.1, OP474062.1.

INTRODUCTION

Sarcocystis parasite is a heteroxenous parasite has an obligatory two host's life cycle one host being an intermediate is usually herbivores which the parasite will have its merogony stage and results in formation of cyst inside the skeletal muscles of these hosts which are commonly referred to tissue sarcocysts. (1). The other host is definitive host which usually be a carnivores host where parasite undergoes its sporogony and gamogony stages of development (2). There are three common spp. *Sarcocystis* in goats *Sarcocystis hircanicus*, *Sarcocystis capracanis*; that produce microscopic cysts that are transmitted by canids, while *Sarcocystis moulei* (*S. caprifelis*) produces macroscopic cysts transmitted by felids (Dubey et al., 2016. *Sarcocystis* spp. that are transmitted via canids are more pathogenic than those transmitted by felids. (Al-Waely and Abd AL-Amery, 2020)

The traditional microscopic examination in diagnosing the types of *sarcocystis* spp depends in most of the studies on the light microscope using the Trichinoscopy method, which is a quick method, but it is less accurate than the method of squeezing and digestion method with pepsin and histological study. However, all these traditional methods of diagnosis are considered incapable of distinguishing between the species of the genus because it is not possible to distinguish between the species based on the differences between the shapes and sizes of the cysts of the different species of the genus (Parkas et al. 2018) Molecular techniques are a reliable method confirm spp. identification and differentiation, using appropriate markers has become an essential tool for accurate identification way to confirm spp. identification of *Sarcocystis* spp. and for research regarding the phylogenetic relationships of these species. These markers include 18S rRNA, 28S rRNA, mitochondrial cytochrome C oxidase subunit 1 gene (COX1) and ITS-1 region (Blazejewski et al. 2015; Hu et al. 2017;). The variability of 18S rRNA gene among the members of the *Sarcocystidae* is sufficient to distinguish most of the species, and among the individuals of the same *Sarcocystis* spp.

The present study aimed to detection of *Sarcocystis* spp. morphologically and analyze the genes encoding 18S rRNA in *Sarcocystis* spp. isolated from naturally infected goats for the first time in Misan Governorate /Iraq.

MATERIALS & METHODS

Samples Collection: For the period from January 2020 to June 2021 fresh tissue samples from 200 of each one of (esophagus, diaphragm, heart, tongue) organs of slaughtered goats were collected from slaughterhouse in Misan governorate. each of these samples was placed in a sealed and sterile plastic bags, labelled with number and date of its collection. The collected sample bags were placed in refrigerated punnet and transferred to the Microbiology Laboratory at the College of Pharmacy/ University of Misan.

Morphological Study

Macroscopic examinations: The examination relied on visual observation of the organs under study (esophagus, diaphragm, heart, tongue) in each animal to see the macroscopic cyst, according (Salam and Salih Mustafa, 2021). The samples were examined with the naked eye examining of the surface layer of each of the organs by making longitudinal and transverse incisions in organs, the cyst were separated and carefully extracted from the muscle tissue of the organ completely and placed in clean and sterile Petri dishes. The lengths of the cyst were measured using a graduated ruler, then kept in 2 ml Eppendorf tubes containing 70% ethanol for DNA analysis. (Portella et al., 2021).

Microscopic Examination: The microscopic study for microscopic *sarcocystis* performed using different conventional method. pepsin digestion method done by collecting of 10 g from fresh organs meat of four organs of goat, fat was removed from them and then cut into small pieces with a sterile scalpel. After that they were put in 50 ml test tubes, then 25 ml of the digester solution (1.5% HCL acid and 0.5% pepsin) was inserted into them. The mixture was incubated at a temperature of 40° C for 20 minutes, then the

digested material was passed through layers of medical gauze. The filtrate was then placed in a centrifuge at a speed of 2000 rpm for 5 min. the supernatant fluid was discarded and sediment was stained with Giemsa and examined microscopically for detecting bradyzoites of Sarcocystis. (Pestechian et al., 2021).

The other method was trichinoscopy method which done by cutting fresh muscle to small pieces, then compressed between two cleaned slides, then examined under light microscope for examination using 4x and 10x magnification to detect the tissue cyst (Claveria et al.,2000).

Squeezing method also done by crushing the pieces of organs meat by garlic presser, solution drop produced from crushed pieces, transferred to the slide then covered with cover slide to be examined under light microscope using 100x.

All the positive tissue samples for Sarcocystis spp. resulted from the three above methods were stored in 70% ethanol for subsequent PCR studies.

Molecular Study

DNA Extraction: Extraction and isolation of DNA from the tissues of organs under study (heart, esophagus, tongue and diaphragm) as well as from the macroscopic cysts of the parasite was done using QIAamp DNA Stool Mini Kit supplied by Qiagen/ Germany. The procedure steps followed according to provider's protocol. Extracted DNA of all sample have been qualified using Qubit dsDNA HS Assay Kit according to manufacturer's protocol.

PCR Amplification: The PCR primer used to detect Sarcocystis spp. in goats was based on 18S rRNA gene. The lyophilized primer was used in present study purchased from (Macrogen/ Korea), which almost amplify at 800 bp. Table 1. (Bittencourt et al., 2016).

Table 1: 18S rRNA primer used in the study according to its reference.

Primer	Direction	Sequence	Reference
18s rRNA Gene	Sense	1L (5'-CCATGCATGTCTAAGTATAAGC-3')	Bittencourt et al., 2016
	Anti-sense	3H (5'-GGCAAAATGCTTTCGCAGTAG-3')	

PCR reaction was done by assembling the reaction components in the PCR tubes prepared for this purpose and placed in the ice and mixed with a vortex device for 10 seconds to collect the components at the bottom of the tube and transferred as quickly as possible to the thermocycler to start the reaction. Table 2. The program of amplification was started with initial denaturation of at 94°C. for 5. minutes, 30 cycles of denaturation at 94°C for 30 seconds annealing at 55°C for 45 second and extension at 72°C for 30 seconds then. Ending program by final extension at 72°C for 7 minutes. The amplification reactions were carried out in PCR thermocycler (Bioneer /Korea), electrophoresed on 1.5% agarose gel, stained with red safe stain. U.V transilluminator and photographed using to examination.

Table 2: PCR reaction components for 18S rRNA gene primer amplification.

PCR Master mix	Volume (µl)
gene Forward primer (10 µmol)	0.5
gene Reverses primer(10 µmol)	0.5
DNA template	6.5
OneTaq 2X Master Mix with Standard Buffer	12.5
Molecular grade water	5
Total volume	25µl

DNA Sequencing and genotyping of the Sarcocystis spp.

Isolates: Nucleotide sequence of the PCR amplified portions of the 18S rRNA gene was performed to identify Sarcocystis spp. at the species level. The test was done on six goats' samples distributed in the form of four microscopic and two macroscopic samples.

The following was followed: A- The products of the polymerase chain reaction were sent for each of the above samples after purification at a rate of 20 µl to the Korean Macrogen Company for

the purpose of sequencing them using the Sanger Sequencing Technique and for the single strand (Forward DNA strand).

B- After obtaining the sequencing results, the process of analyzing the obtained sequences for each sample was carried out for the purpose of profiling the parasite at the species level by comparing the resulting local sequences with similar source sequences found in the GenBank using the available Basic Local Alignment Search Tool (BLAST) program. At the National Center for Biotechnology Information (NCBI) website

C- Observing and defining the Phylogenetic Tree between the resulting sequences of these samples using the Molecular Evolutionary Genetic Analysis Version 7 (Mega 7) program.

D- Sending the specific sequences of the parasite species diagnosed in this study to the NCBI Genbank in order to obtain a Genbank Accession Number for each diagnosed species.

Statistical Analysis: The statistical analysis program SPSS, calculating the mean and standard error, and using chi-square χ^2 were used in order to determine the significant differences between the different groups at the level of significance ($P < 0.05$). 2012). (SAS).

RESULTS AND DISCUSSION

The results of the macroscopic examination of 200 goats' samples collected in the period from January 2020 to December 2020 showed that the total infection rate in goats recorded (2.0%) which was in the esophagus only.

The isolated macroscopic cyst appeared in the esophagus muscles of goats as oval or cylindrical shapes, white or milky, with a smooth and thick walls, with rounded ends that were distributed along the length of the esophagus. figure 1. The sizes ranged between 1-10 mm in length and 2-6 mm in width Figure 2.



Figure 1: macroscopic cysts distributed on the wall of the esophagus in the goats.



Figure 2: Sizes of macroscopic Sarcocysts isolated from the esophagus in the goats.

Microscopic Examination: The results of the current study indicated a high percentage of microscopic infection in goats, recorded about 90% and distributed according to the organs examined in goats. The highest percentage of infection was in the esophageal samples 90.5%, followed by diaphragm 85%, then in tongue samples 78.5%, and finally in the heart 45%. Statistical analysis showed a significant difference in infection rates between organs at $p < 0.05$. Figures 3.

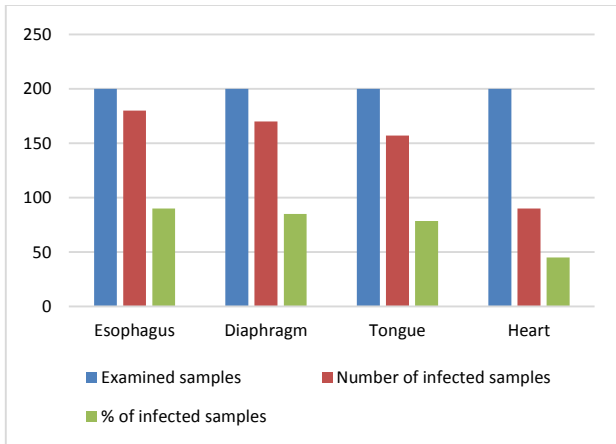


Figure 3: Microscopic infection rates in goats according to infected organs under study.

According to different traditional methods used for detection of *Sarcocystis* spp. in tested goats' organs pepsin digestion method recorded higher infection rates in all examined organs, it was 90.5% in the esophagus, 85% in the diaphragm, 78.5% in the tongue, and 45% in the heart. Trichinoscopy method observed second infection rates, it reached to 89.5% in the esophagus, 82.5% in the diaphragm, 76% in the tongue, and 43.5% in the heart. Whereas, the parasite has been recorded in lower rates with the squeezing method which appeared less sensitive for diagnosis of parasites in the organs examined that recorded 87.5% in the esophagus, 80% in the diaphragm, 74.5% in the tongue and 42% in the heart. Statistically there is no significant differences among these three methods at ($P < 0.05$). Table 3.

Table 3: Efficacy of the diagnostic methods used to detect the microscopic cysts of parasite in the examined organs in goats.

Organ	Pepsin digestion method	Trichinoscopy method	Squeezing method
Esophagus	(200/180) 90	(200 /179) 89.5	(200 /175) 87.5
Diaphragm	(200 /170) 85	(200 /165) 82.5	(200 /160) 80
Tongue	(200 /157) 78.5	(200 /152) 76	(200 /149) 74.5
Heart	(200 /90) 45	(200 /87) 43.5	(200 /84) 42

Figure 4 shows microcysts of *Sarcocystis* spp. under light microscope detected by trichinoscopy method. They look as oval, elliptical and conical form, divided into compartments with various sized and numerous intercostal.



Figure 4: A microscopic cyst in the diaphragm using a Trichinoscopy method in goats (10X).

As shown in table 4 microcysts appeared as larger as in the esophagus at a rate of $133.3 \times 37.4 \mu\text{m}$ while lowest size was in the heart, with an average of $87.8 \times 18 \mu\text{m}$.

When these cysts were stained with Giemsa stain they appeared in a dark blue color that could be easily distinguished from muscle fibers and more clear than undyed cysts, which

appeared less clear and difficult to distinguish from muscle fibers in the organs examined. Figure 5.

Table 4: Measurements of microscopic cysts by organs in goats (n = 30).

Organ	Length (μm)	Width (μm)	Mean= length*Width (μm) \pm SE
Esophagus	180-120	45-32	133.3×37.4 $\pm 0.7814 \times 3.567$
Diaphragm	140-120	35-29	126.9×30.7 $\pm 0.3228 \times 1.407$
Heart	120-80	30-15	87.8×18 $\pm 0.7428 \times 1.867$
Tongue	133-90.4	30-17	97.9×20.5 $\pm 0.7727 \times 2.604$




Figure 5: Microscopic cyst stained with Giemsa stain in goat's esophagus. (10X).

Using peptic digestion method, the bradyzoites were seen by examining one drop of the sediment of the digested muscle fluid Bradyzoites appeared as banana form, with a pointed end of front and rounded rear end, nucleus seem as slightly clear lying near the rear end, measurements $6.3-11$ and $0.9-3 \mu\text{m}$ in length and width, respectively. Figure 6.

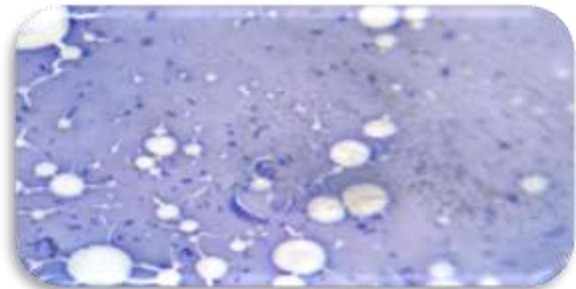


Figure 6: Microscopic cysts of goats stained with Giemsa. (10X).

Molecular Analysis: One hundred twenty-four samples of goats were selected for molecular study. These samples were previously examined for *Sarcocystis* spp. by using digestion method, the result showed that 87.9% of samples were infected with *Sarcocystis* parasites. The PCR of 18S rRNA gene in positive samples amplified showed bands of DNA with a size of approximately 800 bp. Table 5 and figure 7.

Table 5: Types and numbers of samples from which DNA was extracted.

Type of infections	Organ	No	Total
Macroscopic samples	Esophagus	4	4
Microscopic samples	Esophagus	30	120
	Diaphragm	30	
	Tongue	30	
	Heart	30	

All tested goat esophageal samples, macroscopic and microscopic, showed an absolute percentage of molecular infection resulted from amplification of the 18S rRNA gene. While

the rest of the three organs under study have recorded 90%, 83.3% and 80% for each of the diaphragm, tongue and heart, respectively. Table 6.



Figure 7: Agarose gel electrophoresis of PCR products of the 18S rRNA Gene for samples of the four organ samples under study in goats. where path M= (100 bp Marker). Routes (21-32) are samples of positive (appearing at 800 bp) and negative (not showing at 800 bp) DNA strands.

Table 6: Molecular infection rates in the examined samples from the four organs of goats resulting from the amplification of the 18S rRNA Gene.

Type of infections	Organs	No. of tested organs	No. of infected organs	% of infection
Macroscopic samples	Esophagus	4	4	100
	Diaphragm	30	27	90
Microscopic samples	Tongue	30	26	86.7
	Heart	30	24	80

six (6) pure single bands of the 18S rRNA gene appeared on the agarose gel were selected for PCR, which are amplified fragments of this gene with sizes close to (800 bp) based on the specific primer used in this study. Each of these bands belongs to a single and independent sample of six goat samples distributed in the form of four microscopic and two macroscopic samples.

Table 7 shows the analysis of the resulted sequence for each of the six samples that have been selected and sent for the purpose of typing the parasite at the species level by alignment the resulted local sequences with the similar sequences found in the Genbank by the Basic Local Alignment Search Tool (BLAST) available at the National Center for Biotechnology Information (NCBI) website. Each one resulted sequences have recorded in the GenBank and has given a distinctive accession number. The results obtained from sequence analysis of 18S rRNA gene for these six samples showed that four microscopic samples of goats (OP474017.1, OP474018.1, OP476699.1 and OP474036.1) were closely related to the Malaysian species; *S. capracanis* with accession number (KR155191.1) with identity score percentages as 99.50%, 99.01%, 99.76% and 99.13%, respectively. Finally, the two macroscopic samples of goats (OP474061.1 and OP474062.1) were identical with the Egyptian species; *S. buffalonis*, with accession numbers (KU247913.1) and (KU247913.1) respectively, with a matching percentage of 84.39% and 85.64% respectively.

Table 7:

Samples		NCBI-BLAST Homology Sequence identity (%)			
Types	GenBank accession Number	Identical Sarcocystis spp.	GenBank accession Number	Country	Identity
microscopic	OP474017.1	<i>Sarcocystis capracanis</i>	KR155191.1	Malaysia	99.50
microscopic	OP474018.1	<i>Sarcocystis capracanis</i>	KR155191.1	Malaysia	99.01
microscopic	OP476699.1	<i>Sarcocystis capracanis</i>	KR155191.1	Malaysia	98.76
microscopic	OP474036.1	<i>Sarcocystis capracanis</i>	KR155191.1	Malaysia	99.13
macroscopic	OP474061.1	<i>Sarcocystis buffalonis</i>	KU247913.1	Egypt	84.39
macroscopic	OP474062.1	<i>Sarcocystis buffalonis</i>	KU247910.1	Egypt	85.64

DISCUSSION

The current study's findings, which included the first examination of this parasite in goats in Misan Governorate, indicated significant injury rates of the microscopic type of 90% in goats, respectively. This suggests that the disease is one that spreads throughout Misan Governorate/Iraq. However, the disease's nature does not have obvious symptoms, and the parasite's presence as cysts inside the muscle tissue makes it difficult for veterinarians and animal breeders to diagnose the illness with a biopsy since they are unaware of the parasite's life cycle and the disease's nature.

The recording of the high rate of infection is consistent with what the researchers recorded. Whereas, Zangana and Hussein (2017) in Duhok recorded a high rate of infection in goats, reaching 100%. In Egypt, Mahran (2009) recorded an infection rate of 80.32% in goats. It agreed with the results of Amairia et al (2018) in Tunisia, which found a high incidence of infection in goats. Bittencourt et al (2016) reported that the total infection rate of the microscopic pineal sac parasite reached 91% in goats in Brazil. Salehi et al (2022) also indicated that a 100% infection rate was recorded in goats in Iran.

Our study found a low infection rate of the macroscopic type in goats, equivalent to 2%. This finding is in agreement with researches from other countries, like Iraq, which also found low infection rates with this parasite in other hosts, Dakhil (2016) examined 904 samples of skeletal muscles and esophagus from buffaloes in Misan Governorate, and found a total incidence of macroscopic type amounting to 2.77%. This finding is comparable to that of Al-Saadi (2019) in Karbala, where a percentage of 6% was found in the muscles of the esophagus in sheep, and Muhammad and Kazim (2010) who recorded infection rate in goats as extremely low, reached to 0.93% in the Diyala Governorate, and the percentage recorded in our study is less than what was recorded in Erbil governorate, where Swar and Shnawa (2020) recorded an infection rate of 9% in isolated esophageal samples of sheep and goats, and Abo-Shehada recorded (1996) a rate of 11.7% in goats in Jordan. The rate of infection recorded by Al-Hoot et al (2005) in goats was 11.3% in Saudi Arabia.

Due to the final hosts of the macroscopic type, which are cats, having less contact and friction in the fields and farms of field animal breeding, cats produce a smaller number of cysts, which it takes a long time to be able to infect, as the life cycle of the parasite of the macroscopic spp., recording high rates of infection with the microscopic type compared to those recorded with the macroscopic type, which were low (Dubey et al., 1989), While dogs that are the microscopic type's final hosts are more likely to come into contact with the intermediate hosts in grazing areas and areas used for animal husbandry, as well as inside homes in villages, where they share food and water that can become contaminated with cysts, the primary cause of infection. In addition, dogs are more likely than cats to come into contact with the carcasses of deceased animals, which increases their risk of contracting the parasite. (El-Dakhly and El-Neser, 2011).

The difference in infection rates among members in our study and other studies may be due to the nature of nutrition in animals, health status, immunity and the extent of contamination of pastures with cysts (Rahdar and Salehi, 2011).

The esophagus was found to have the highest infection severity in the study's examination of the organs, followed by the diaphragm, tongue, and heart in goats. This finding is similar to that of Dayashank and Bhatia (1993), who found the esophagus and diaphragm to have the highest infection severity. According to Mitchell (1988), dogs, cats, and monkeys experimentally infected with the parasite by being fed beef tainted with two different types of tissue cysts of the parasite did not exhibit any signs of illness. Low cyst concentrations were found in the meat, however pigs with 40 or more cysts of the parasite displayed clinical signs, such as flank weakness, muscle stiffness, and transient posterior paralysis

The macroscopic type was found in our study in goats only in the esophagus at rates of 2%, which agree with what was found by (El-Mishmishy, 2017) in sheep and (Ahmed et al, 2016) in cows

and agree with what was mentioned (Dubey et al (1989) that macroscopic cysts are commonly found in the muscles of the esophagus. The results of Kamil and Faraj, (2020) agree, where they note that the incidence of the macroscopic type is high in the esophagus compared to the diaphragm, and this may be due to the nature of the parasite in choosing the esophagus as a suitable organ to invade it, as The esophagus is one of the active organs, so the chance of parasite access to it is higher than the rest of the organs.

When contrasting the usual techniques—pepsin digestion, trichinoscopy, and pressing—used to identify microscopic type infections in goats in all the studied and isolated organs of and goats The findings demonstrated that the pepsin digestion method was more effective than the conventional techniques for diagnosing the microscopic type. This finding is consistent with that of Dehkordi et al (2017) and what was mentioned by Ferreira et al (2018) that this method is an ideal one for identifying sarcocystis disease because it relies on the release of sarcocysts after the microscopic cyst is destroyed and described (Rahdar and Salehi, 2011) as a rapid, easy, and accurate way to identify parasites in meat. This method has a high degree of accuracy and sensitivity, but because the parasite is only identified generally, it cannot be trusted to identify the specific type of parasite.

After using the pepsin digestion method to analyze all the organs, the trichinoscopy method demonstrated its effectiveness in detecting the microscopic kind of the parasite in sheep and goats. It is one of the quick and effective ways to identify the parasite. The biggest number of infected sheep and goats, according to (Metwally et al. (2019) in his study, were found using this simple and effective procedure. It is consistent with what (Maktoof and Abu Tabeek, 2015) discovered in Basra, where they identified isolated samples of buffaloes' esophagus, heart, diaphragm, and skeletal muscles had infection rates of 77.5% and 72.2%, respectively, utilizing Trichinoscopy endoscope extracts. Our research was different from that of Mohammad (2012), who found that this method's efficiency in cows was 66.5% as opposed to 70% for histological testing.

The Trichinoscopy method and pepsin digestion both reported higher infection rates than the squeezing method, which was lower in all affected organs in sheep and goats. (Mirzaei and Rezaei, 2014) used a rapid and easy method (squeezing method) to record the infection rate in all organs investigated in cows. It is advised to employ this technique in survey studies since it is regarded one of the straightforward and affordable approaches because it uses a garlic press machine to split the bag and release the pods without the need of any chemicals or other equipment.

When the trichinoscopy method was used to determine the microscopic kind of sarcocystis in the goat organs under examination, the cysts took on various shapes, including oval and cylindrical ones that were divided into rooms by septa. The cyst's shape varies depending on the organ in which it is found; for example, it has a spindle-like shape in skeletal muscle due to the length of its fibers and their parallel arrangement, which aids in the cyst's growth into a cylindrical shape, while it has an oval or circular shape in the heart due to the shortness of the muscle fibers (Savini et al., 1992). The esophagus of goats had the largest cysts, measuring 133.3 x 37.4 micrometers, while the heart muscles had the smallest cysts, measuring 87.8 micrometers. The cyst sizes varied depending on the organ. The age of the cyst, its maturity, the length of time it survived in the intermediate host, the sampling procedure, and the type of tissue could all be contributing factors to the discrepancy between the prior research and ours. In small ruminants, the size of the microscopic cyst does not appear to be a factor in the diagnosis of the various species of pineal sac parasites. (Bittencourt et al., 2016).

Regarding the molecular diagnosis and detection of the sarcocystis parasite in goats, our work is the first of its kind in the Misan Governorate of Iraq. As at the local level, there aren't many studies that dealt with the molecular diagnosis of the sarcocystis parasite in a number of Iraqi cities, including the studies (Dakhil,

2016) that dealt with the parasite in water buffalo in the city of Al-Amarah and (Whaeeb et al. (2016), which dealt with the parasite in sheep in the city of Baghdad. and the study (Al-Saadi, 2019), which focused on the molecular diagnosis of the parasite in sheep in the city of Karbala; the study (Kamil and Faraj, 2020), which addressed the molecular diagnosis of the parasite in beef and imported meat in the city of Baghdad; the study (Alwaely, 2020), which identified the parasite molecularly in goats in the city of Wasit; The research by Salam (2021) and Swar and Shnawa (2021), which focused on the molecular diagnosis of the parasite in sheep and goats in the cities of Sulaymaniyah and Erbil, respectively, were the final two studies.

The findings of our investigation demonstrated that the parasite had a high molecular infection rate, reaching 90.41% using 18S rRNA Gene in these 120 microscopic samples and 2 macroscopic samples from goats. All samples taken from the esophagus, in goats, showed a molecular infection of 100% and for 18S rRNA genes studied. Followed by the incidence rates of the diaphragm, tongue and heart,

Numerous studies, both local and international, have documented the sarcocystis parasite's molecular infestation of various organs in the two types of small ruminants (sheep and goats) in varying amounts. One such study was conducted in Erbil by the researchers (Swar and Shnawa, 2021), which was restricted to the molecular diagnosis of macroscopic infection using the 18S rRNA Gene in the esophagus of sheep and goats. We also discover that the rate of molecular infection in goats in the Wasit city study (Alwaely, 2020) utilizing the (ITS1-rRNA gene) was 89%, the percentage of esophageal injury was 92%, and the rate of infection to the diaphragm was recorded at 86%, which is similar to the rates found in our study. In 120 microscopic samples taken from the esophagus, heart, and tongue of sheep and goats, respectively, and using 18S rRNA Gene, the study did not detect any specific infection in either animal, infection rates with the parasite reached 95.8% and 91.6%, respectively.

The study employed the 18S rRNA gene with the source sequences in the GenBank using (NCBI-BLAST) to diagnose sarcocystis parasite at the species level after examining the consistency of the nucleotide sequences of the 6 samples. The microscopic goat samples contained only *S. capracanis*. Additionally, *S. buffalonis* was discovered in two goat macroscopic samples in our investigation for the first time ever in both Iraq and the rest of the world. There have only been two local studies that have identified the parasite species *S. capracanis* in microscopic samples of goat tissue: Alwaely's study in Wasit city in 2020 and Swar and Shnawa's study in Erbil city in 2021. Numerous international studies from various continents have found this species in microscopic samples from goats, including those from Egypt (Morsy et al., 2011), Malaysia (Kutty et al., 2015), Brazil (Bittencourt et al., 2016), Tunisia (Amairia et al., 2017), and Saudi Arabia (Metwally et al., 2019). Finally, prior to penning these lines just for our study, *S. buffalonis* had not been recorded anywhere in the world. As a result, we can affirm that our study is the first of its kind to report goats being infected with *S. buffalonis* globally.

REFERENCES

- Odening, K. (1998) The present state of species-systematics in Sarcocystis Lankester, 1882 (Protista, Sporozoa, Coccidia). Syst. Parasitol., 41: 209 – 233.
- Morsy, k.; Saleh, A.; Al-Ghamedi, A.; Abdel-Ghaffar, F.; Al-Rasheid, K.; Bashtar, A. R.; Al Quraishy, S. and Mehlhorn, H. (2011). Prevalence pattern and biology of Sarcocystis capracanis infection in Egyptian goats: a light and Itrastructural study. Vet. Parasitol., 182: 75 – 82.
- Dubey, J. P.; Moré, G.; Van Wilpe, E.; Calero-Bernal, R.; Verma, S. K. and Schares, G. (2016). Sarcocystis rommeli. sp.(Apicomplexa: Sarcocystidae) from cattle (*Bos taurus*) and its differentiation from Sarcocystis hominis. Journal of Eukaryotic Microbiology. 63 (1): 62-68.
- Al-Waely, T.N. and Abd AL-Amery, A.M. (2020). Prevalence of Sarcocystosis in Goats (*Capra hircus*) at Wasit Province, Iraq. Plant Archives, 20(2), pp.8939-8944.

- 5 Blazejewski, T.; Nursimulu, N.; Pszenny, V.; Dangoudoubiyam, S.; Namasivayam, S.; Chiasson, M.A.; Chessman, K.; Tonkin, M.; Swapna, L.S.; Hung, S.S. and Bridgers, J.(2015). Systems-based analysis of the *Sarcocystis neurona* genome identifies pathways that contribute to a heteroxenous life cycle. *MBio*.6(1):2445-14.
- 6 Hu, J.J.; Huang, S.; Wen, T.; Esch, G.W.; Liang, Y. and Li, H.L. (2017). *Sarcocystis* spp. in domestic sheep in Kunming City, China: prevalence, morphology, and molecular characteristics. *Parasite*, 24 (30):1-8
- 7 Prakas, P.; Butkauskas, D.; Švažas, S.; Juozaitytė-Ngugu, E. and Stanevičius, V. (2018). Morphologic and genetic identification of *Sarcocystis fulicae* n. sp. (apicomplexa: Sarcocystidae) from the Eurasian coot (*Fulica atra*). *Journal of wildlife diseases*,54:765–771.
- 8 Portella, L.P.; Fernandes, F.D.; Rodrigues, F.D.; Minuzzi, C.E.; Sangioni, L.A.; Flores, M.M. and Vogel, F.S.(2021). Macroscopic, histological, and molecular aspects of *Sarcocystis* spp. infection in tissues of cattle and sheep. *Revista Brasileira de Parasitologia Veterinária*. 30(3):1-6. <https://doi.org/10.1590/S1984-29612021050>.
- 9 Pestechian, N.; Yousefi, H.A.; Kalantari, R.; Jafari, R.; Khamesipour, F.; Keshkar, M. and Esmailifallah, M.(2021). Molecular and Microscopic Investigation of *Sarcocystis* Species Isolated from Sheep Muscles in Iran. *Journal of Food Quality*. 2021:1-6.
- 10 Castro-Forero, S. P.; Bulla-Castañeda, H.; López, A. D. A.; Buitrago and L. M. De Carvalho (2020). *Sarcocystis* Spp. A Parasite with Zoonotic Potential. *Advanced. Animl. and Veterinary. Science. Journal*. 3(9): 473-477.
- 11 Bittencourt, M. V.; Meneses, I. D. S.; Ribeiro-Andrade, M.; de Jesus, R. F.; de Araújo, F. R. and Gondim, L. F. P. (2016). *Sarcocystis* spp. in sheep and goats: frequency of infection and species identification by morphological, ultrastructural, and molecular tests in Bahia, Brazil. *Parasitology research*.115(4): 1683-1689.
- 12 Dakhil, H.G., Abdallah, B.H. and Abdallah, F.A. (2017). Molecular identification of *Sarcocystis fusiformis* and *S. moulei* infecting water buffaloes (*Bubalus bubalis*) in southern Iraq. *World Journal of Pharmaceutical Research*, 6(3), pp.215-229.
- 13 Zangana, I.K. and Hussein, S.N. (2017). Prevalence of *Sarcocystis* Species (*Sarcocystis ovis* and *Sarcocystis capricanis*) in Tongue Muscle of Sheep and Goats in Duhok Province, Kurdistan Region, North Iraq. *Aro-The Scientific Journal of Koya University*. 5(1): 36-40.
- 14 Mahran, O.M. (2009). *Sarcocystis* infection in sheep and goats slaughtered in Shalatin Abattoir, Red Sea Governorate, Egypt. *Assiut Veterinary Medical Journal*, 55(121): 341- 355.
- 15 Amairia, S.; Amdouni, Y.; Rouatbi, M.; Rjeibi, M. R.; Awadi, S. and Gharbi, M. (2018). First detection and molecular identification of *Sarcocystis* spp. in small ruminants in North-West Tunisia. *Transboundary and emerging diseases*. 65(2): 441-446.
- 16 Bittencourt, M. V.; Meneses, I. D. S.; Ribeiro-Andrade, M.; de Jesus, R. F.; de Araújo, F. R. and Gondim, L. F. P. (2016). *Sarcocystis* spp. in sheep and goats: frequency of infection and species identification by morphological, ultrastructural, and molecular tests in Bahia, Brazil. *Parasitology research*.115(4): 1683-1689.
- 17 Salehi, M.; Spotin, A.; Rostamian, M. and Adami, M. (2022). Prevalence and molecular assessment of *Sarcocystis* infection in livestock in northeast Iran. *Comparative Immunology, Microbiology and Infectious Diseases*.80: 101738.
- 18 Al-Saadi, S.A.; Al-Mussawi, K.A. and Muhammed H.A. (2020). Molecular Identification of *Sarcocystis* Species Infection in Sheep in Karbala Governorate–Iraq. *Medico Legal Update journal*.20(1): 889-895.
- 19 Swar, S.O. and Shnawa, B.H. (2020). Ultrastructural and Molecular Characterization of *Sarcocystis* Species Derived from Macroscopic Sarcocysts of Domestic Sheep and Goats in Soran City, Erbil, Iraq. *World*. 10(4):540-550.
- 20 Abo-Shehada, M. N. (1996). Age variations in the prevalence of *Sarcocystosis* in sheep and goats from northern and central Jordan. *Preventive Veterinary Medicine*.27(3-4): 135-140.
- 21 Dubey, J. P.; Peer, C. A. and Fayer, R. (1989). *Sarcocystosis* of Animals and Man. CRC Press Inc., Boca Raton, Florida.
- 22 Rahdar, M. and Salehi, M. (2011). The prevalence of *Sarcocystis* infection in meat production by using digestion method in Ahvaz, Iran. *Jundishapur J. Microbiol*. 4(4):295-299.
- 23 Mitchell, M. (1988). The prevalence of macroscopic sarcocysts in New Zealand cattle at slaughter. *New Zealand veterinary journal*.36:35–38
- 24 Dayashank, A.R. and Bhatia, B.B. (1993): *Sarcocystis* infection in goats in Uttar Pradesh. *Indian journal. of animal Science*. 63 (3): 248-287.
- 25 El-Mishmishy, B.M.M. (2017). Molecular characterization of *Sarcocystis* species in sheep. Ph. D Thesis. Faculty of Veterinary Medicine. Department of Parasitology-Mansoura University. in partial fulfillment of the requirements the degree of Doctor of Philosophy Doctor of Veterinary Medical Science (Ph. D). pp:1-116.
- 26 Ahmed, A.M.; Elshraway, N.T. and Youssef, A. (2016). Survey on *Sarcocystis* in bovine carcasses slaughtered at the municipal abattoir of El-Kharga, Egypt, *Veterinary World*, 9(12): 1461-1465.
- 27 Kamil, J.K. and Faraj, A.A. (2020). Molecular detection of *Sarcocystis* cruzi in slaughtered cattle at Baghdad city in Iraq. *Plant Arch*. 20:1833-1846.
- 28 Metwally, D. M.; Al-Damigh, M. A.; Al-Turaiki, I. M. and El-Khadragy, M. F. (2019). Molecular Characterization of *Sarcocystis* Species Isolated from Sheep and Goats in Riyadh, Saudi Arabia. *Animals*. 9 (5): 256.
- 29 Savini, G.; Dunsmore, J.D.; Robertson, I.D. and Seneviratna, P. (1992). The epidemiology of *Sarcocystis* spp. in cattle of Western Australia. *Epidemiology & Infection*. 108: 107-113.
- 30 Whaeeb, S.T; Faraj, A.A. and Khalaf, I.A. (2016). Molecular Study of Four Species of *Sarcocystis* isolated from sheep esophagus and inter skeleton muscle in. *World Journal of Pharmaceutical Research*. 5(8):158-165.
- 31 Salam, S.M. and Salih Mustafa, B.H. (2021). Identification of *Sarcocystis* Species "Macrocytis. *Journal of Animal and Poultry Production*, 12(10),:331-337
- 32 Alwaely, T.N.A.(2020). Traditional and Molecular Diagnostic Study for *Sarcocystosis* in Goat's (*Capra hircus*) at Wasit province, Iraq. *MSC Thesis*. University of Baghdad/College of Veterinary Medicine. in partial fulfillment of the requirements for the Degree of Master of Science in Veterinary Medicine/ Parasitology. pp:1-120.
- 33 Kutty, M.K.; Latif, B.; Muslim, A.; Hussaini, J.; Daher, A.M.; Heo, C.C. and Abdullah, S. (2015). Detection of sarcocystosis in goats in Malaysia by light microscopy, histology, and PCR. *Tropical animal health and production*. 47(4):751-756.
- 34 Metwally, D. M.; Al-Damigh, M. A.; Al-Turaiki, I. M. and El-Khadragy, M. F. (2019). Molecular Characterization of *Sarcocystis* Species Isolated from Sheep and Goats in Riyadh, Saudi Arabia. *Animals*. 9 (5): 256.
- 35 Mirzaei, M. and Rezaei, H. (2014). A survey on *Sarcocystis* spp. infection in cattle of Tabriz city, Iran. *Journal of Parasitic Diseases* 40(3):648-51. doi: 10.1007/s12639-014-0551-2.
- 36 Maktoof, A.R. and Abu Tabeekh, M.A.S. (2015). *Sarcocystosis* infection of buffalo Carcasses in Basra Governorate- Iraq. *International Journal of Development Research*.5(11): 6025-6028.
- 37 Dehkordi, Z.S.; Yalameha, B. and Sari, A.A. (2017). Prevalence of *Sarcocystis* infection in processed meat products by using digestion and impression smear methods in Hamedan, Iran. *Comparative clinical pathology*. 26(5): 1023-1026. doi: 10.1177/104063871002200222.