

CASE REPORT**A Rare Case of Herlyn Werner Wunderlich Syndrome (HWWS) with Urethrovaginal Fistula**MEHER-UN-NISA¹, MARIA MAQSOOD², ALEENA SARWAR³, TAYYABA IQBAL⁴, AYESHA SIDDIQA⁵, AYESHA SABRINA ASLAM⁶¹Head of Department of Obstetrics & Gynecology Lady Aitchison Hospital, King Edward Medical University Lahore Pakistan^{2,3,4}Senior registrars Lady Aitchison Hospital KEMU Lahore⁵Post graduate trainee Lady Aitchison Hospital Lahore⁶Student final year MBBS, Lahore Medical & Dental College, LahoreCorrespondence to Prof. Dr. Meher-un-nisa, Email: drmehersajawal@gmail.com, Mobile; 0300-5334413**SUMMARY**

Herlyn Werner Wunderlich Syndrome (HWW) is a rare congenital malformation of female urogenital tracts. We report our first case of HWWS with urethrovaginal fistula in Lady Aitchison Hospital Lahore. A 27 years old lady presented with hematuria and urinary retention having single opening at vulva with menstrual blood and urine draining through it. Examination under anesthesia showed urethral opening in anterior wall of lower 1/3 of vagina. MRI showed uterus didelphus with two cervixes and vagina (atresia of lower 2/3 on left side) and absent left kidney. Surgical treatment by creating a separate opening of neourethra was made by Urology Department of Mayo Hospital.

Keywords: Herlyn Werner Wunderlich syndrome, urethrovaginal fistula, urogenital tract

INTRODUCTION

Herlyn Werner Wunderlich Syndrome is a rare congenital anomaly of female urogenital tract characterized by unilateral complete or incomplete agenesis of hemivagina, uterus didelphus and ipsilateral renal agenesis¹. It is also called OHVIRA (Obstructed hemivagina and ipsilateral renal Syndrome). Its incidence is reported to be 0.1.-3.8%². It is usually diagnosed after puberty and may present with pelvic pain, dysmenorrhea, abdomino pelvic mass or renal pain but it may present later in life. Diagnosis is made on the basis of history, physical examination and confirmed on ultrasound and MRI³. Treatment may be conservative or surgical based on patient symptoms^{4,5}.

CASE REPORT

[Patient Miss XYZ, 27 years old achieved menarche at 13 years with regular periods, resident of Lahore presented in Gyne OPD Lady Aitchison Hospital Lahore on 22/8/2022 with complain of: cyclical hematuria since menarche. She also complained of burning micturition with off and on episode of urinary retention for 3 years, Suprapubic pain on and off for 1 year and pelvic pain from 6 months.

On Examination: A young healthy looking female lying comfortably on bed, well oriented in time and space and vitally stable with no significant finding on General physical examination.

On perineal examination, there is single opening of vagina and urethra, a slight tubercle with a central groove on the anterior surface of this opening was noted. Foleys catheter was passed through the opening in the anterior wall of vagina 1.5 cm above vagina introitus. Clear urine drained. Fresh blood seen coming through the opening (menstruating).

EUA; Single opening seen at vulva with blood draining through it (menstruating)

Urethral opening was found in anterior vaginal wall, 1.5 cm above the introitus. Foleys seen coming out through the same opening draining clear urine. Vaginal length 6-8 cm with adequate space, pin point cervix with menstrual blood draining through it. Fullness on left fornix.

In our case the findings both clinical, ultrasound and MRI correspond to type 2.2 (Figure 3)⁶ or type D (Figure 4)⁷. There was absence of Left kidney, uterus didelphus, two cervixes (on USG and MRI) but only one cervix on EUA, single vagina (septum between two vagina in upper 1/3) and urethral opening found in lower third of vagina 1.5 cm above vaginal ring (Urethrovaginal fistula).

Received on 02-09-2022

Accepted on 07-10-2022

Figure 1: Single opening with both vagina and urethra opening. Foley's catheter seen inside urethra

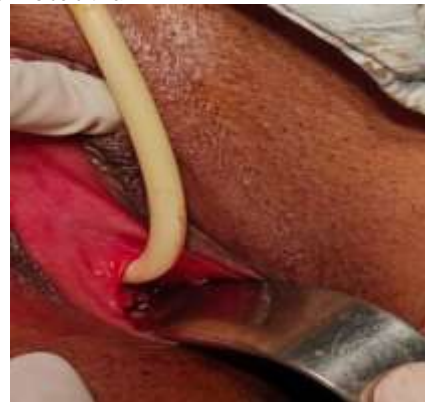

Figure 2: Single vagina and cervix seen on EUA

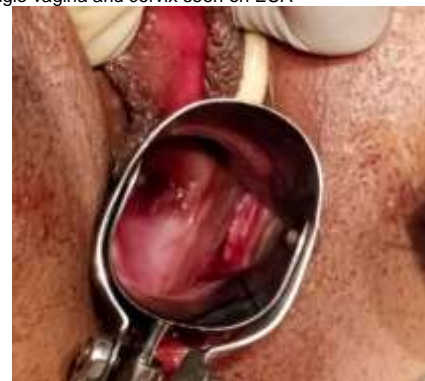

Figure 3: Classification of HWW Syndrome⁶

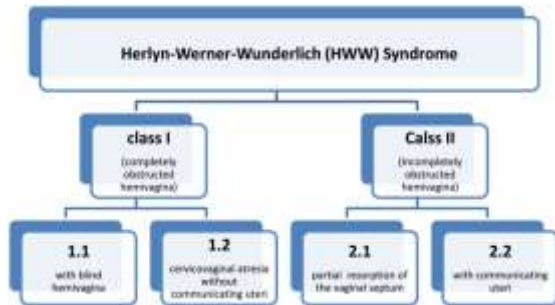
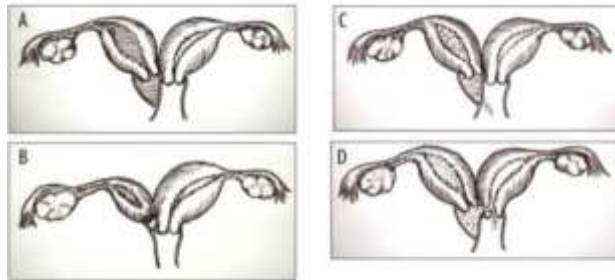


Figure 4; Classification of HWW Syndrome (Pictorial)⁷



A-Atresia of ipsilateral vagina with hematocolpos and hematometra
 B-Atresia of ipsilateral cervix and complete obliteration of vagina with hematometra
 C-Atresia of ipsilateral vagina with a small communication between two hemivagina
 D-Atresia of ipsilateral hemivagina with communication between two cervixes

Investigations: HerHb was 11.3gm/dl.TLC 10.9 000/cmm, platelets 232000/cmm, S/creatinine 0.8mmol/l, urea 26mg/dl, LFTs and Urine examination were normal

Ultrasound: Congenital left small kidney and bicornuate uterus. No evidence of obstruction (hematocolpos, hematometra, hematosalpinx) seen.

CT scan: congenital left hypoplastic kidney with compensatory hypertrophy o rightkidney. Uterine Didelphys, two cervixes and atresia of left hemivagina.

Cystogram was normal.

MRI: both uterus with separate cervix, hypoplastic Left side hemivagina and absent left kidney.

DISCUSSION

Our patient presented late (27 years) with atypical symptoms of HWW Syndrome i.e. cyclical hematuria and off and on urinary retention after menarche for the last 14years. She has no such complaints before menarche. Findings of only one opening at vulva suggested that both urine and menstrual blood were draining through the same opening. Occasional cyclical retention of urine indicates blockage of urethral opening by menstrual blood during menstruation. There was no history of any abdominao pelvic discomfort or feeling of mass which are expected if there is any blockage to menstrual flow at any level with resultant hematocolpos, hematocervix, hematometra and hematosalpinx. Our examination under anesthesia confirmed findings of urethra vaginal fistula, single vagina and single cervix with fresh blood draining through the cervix (Patient menstruating) were noted.

The findings of investigations like ultrasound and MRI showed absent Left kidney.HWW Syndrome is a congenital abnormality of mesonephric duct induced Mullarean duct anomalies(MDA).⁸ In 30% cases associated renal anomalies are found with MDA like renal agenesis⁹. In HWW Syndrome, there is typically absence of ipsilateral renal agenesis, uterus didelphus and ipsilateral vaginal atresia on the same side^{10,11,12}. In our case it was on the left side that both renal and vaginal atresia were

noted.The other anomaly found was urethra vaginal fistula which is also very rare⁵.

Management depends upon type of anomaly and symptoms. In our patient, there were no symptoms of obstruction to the menstrual flow, no hemato colpos or hemtometra noted on USG and MRI.Presence of one vagina and one cervix shows that our case falls in D type of classification (Figure 4)⁷ of HWW Syndrome in which there are two cervixes on ultrasound and MRI but one on EUA due to presence of complete septum between two hemivagina and communication between two cervixes, sothat the blood from left horn of uterus didelphus drains through the opening between two cervixes into right cervix which is visible on EUA.

As patient problem was haematuria and occasional cyclical retention of urine, patient was discussed with urologist, radiologist and plastic surgeon. It was decided to create a separate opening for urethra by creating a neourethra by urologist. So patient was referred to urologist.

CONCLUSION

HWW Syndrome is a rare congenital anomaly. Diagnosis is difficult especially if patient presents with atypical symptoms. Early diagnosis and management in collaboration with gynecologist, radiologist, urologist and plastic surgeon is essential to prevent complications.

Conflict of interest: There is no conflict of interest.

REFERENCES

1. Mabuchi S, Hayashida H, Kubo C, Takemura M, Kamiura S. Herlyn-Werner-Wunderlich syndrome (HWWs)-associated gynecological malignancies: A case report and literature review. *Gynecologic Oncology Reports*. 2022 Oct 1; 43:101051.
2. Obstructive Müllerian anomalies: Case report, diagnosis, and management. *Am. J. Obstet. Gynecol* 2001;185 (2) :338-344.
3. Candiani M, Vercellini P, Ferrero-Caroggio C, Fedele F, Salvatore S, Fedele L. Conservative treatment of Herlyn-Werner-Wunderlich syndrome: Analysis and long-term follow-up of 51 cases. *European Journal of Obstetrics & Gynecology and Reproductive Biology*. 2022 Aug 1; 275:84-90.
4. Begum T, Begum F, Islam N, Alam S. Herlyn Werner Wunderlich Syndrome: A Very Rare Presentation in a Teenage Girl. *Sch J Med Case Rep*. 2022 Oct ;10:1034-9.
5. Adi K, Noegroho BS, Septrina R, Sasotya RS, Drajat K D, Saputra D. Herlyn-Werner-Wunderlich syndrome with urethrovaginal fistula: A rare case report. *Urol Case Rep*. 2021 Oct 25; 40:101911.doi: 10.1016/j.eucr.2021.101911. PMID: 34745901; PMCID: PMC8556507.
6. L Zhu, N Chen, JL Tong, *et al*. New classification of Herlyn-Werner-Wunderlich syndrome. *Chin Med J*, 128 (2015), pp. 222-225, 10.4103/0366-6999.149208
7. Pangastuti N, Rahman MN, Setyawan N. Surgical therapy for herlyn-werner-wunderlich (HWW) syndrome cases. *Int J FamCommun Med*. 2021;5(5):152-156. DOI: 10.15406/ijfcm.2021.05.00238
8. Hayat AM, Yousaf KR, Chaudhary S, Amjad S. The Herlyn-Werner-Wunderlich (HWW) syndrome–A case report with radiological review. *Radiology Case Reports*. 2022 May 1;17 (5):1435-9.
9. Liang HI, Fu SC, Yin CH, Chang CC. Herlyn–Werner–Wunderlich syndrome: An unusual case with presentation of menorrhagia. *Taiwanese Journal of Obstetrics and Gynecology*. 2020 Nov 1;59(6):948-51. <https://doi.org/10.1016/j.tjog.2020.09.026>
10. Rusda M, Umara A, Rambe AY. Herlyn Werner Wunderlich syndrome with hematocolpos symptom. *Open access Macedonian journal of medical sciences*. 2019 Aug 8;7(16):2679. doi: 10.3889/oamjms.2019.406
11. Nishu DS, Uddin M, Akter K, Akter S, Sarmin M, Begum S. Herlyn-Werner-Wunderlich syndrome presenting with dysmenorrhea: a case report. *Journal of medical case reports*. 2019 Dec;13(1):1-6. <https://doi.org/10.1186/s13256-019-2258-6>
12. Ilyas M, Khan I, Saldanha CL. Herlyn-Werner-Wunderlich syndrome– a rare genitourinary anomaly in females: a series of four cases. *Polish journal of radiology*. 2018 Jun 20;83:306-10. DOI: <https://doi.org/10.5114/pjr.2018.77026>