

Comparison of Hemiarthroplasty and Total Hip Arthroplasty in Elderly Patients with Displaced Femoral Neck Fractures

MUHAMMAD KAMRAN SHAFI¹, MUHAMMAD IQBAL BUZDAR², SHAHID MAHMOOD³, MUJTABA AFZAL KHAN⁴, FAISAL MUBEEN⁵

¹Assistant Professor Orthopaedic, QAMC/BVH, Bahawalpur

²Senior Registrar, Bahawal Victoria Hospital (BVH), Bahawalpur

³Senior Registrar, Bahawal Victoria Hospital (BVH), Bahawalpur

^{4,5}Consultant Orthopaedic, Surgeon, Bahawal Victoria Hospital (BVH), Bahawalpur

Corresponding author: Muhammad Kamran Shafi, Email: kamranshafi35@gmail.com

ABSTRACT

Background and Aim: Hemiarthroplasty (HA) and total hip arthroplasty (THA) are the two alternate surgical interventions required for displaced femoral neck fractures in elderly patients. Though THA is superior in certain aspects such as hip pain, reoperation rate and function but had higher dislocation rate compared to HA. The present study aimed to compare the hemiarthroplasty and total hip arthroplasty in elderly patients with displaced femoral neck fractures.

Patients and Methodology: This retrospective cohort study was conducted on 20 displaced femoral neck fractures patients in the Department of Orthopedic QAMC/ BVH Bahawalpur from January 2021 to August 2022. Prior to start of study, ethical approval was taken from the institute research and ethical committee. Written informed consent was obtained from each individual. Patients aged >60 years and had femoral neck fractures were enrolled. Rheumatoid arthritis in fracture hip patients, non-ambulatory patients, and pathological fracture patients were excluded. Patients were categorized into two groups; group-I patients undergoing hemiarthroplasty and group-II patients undergoing total hip arthroplasty. Post-operative complications such as fracture, medical issues, dislocation, surgical site infection, and mortality (1 year) were assessed in both groups. Harris Hip Score (HHS) was used for the assessment of function outcome at one month, three months, six months, and twelve months. SPSS version 25 was used for data analysis.

Results: Of the total 20 femoral neck fractures patients, 10 patients underwent hemiarthroplasty and 10 underwent total hip arthroplasty. The overall mean age was 69.44±7.91 years. Demographic details or baseline features were almost similar in both groups. During follow-ups, patients who underwent total hip arthroplasty (group-II) had higher Harris hip score than group-I patients. The mean HHS score in group-I patients were 61.53, 68.24, 70.81, and 76.16 at follow-up visit after one month, three months, six months, and twelve months respectively while in group-II, the mean HHS score were 66.23, 69.82, 73.25, and 78.92 respectively.

Conclusion: Our study concluded that total hip arthroplasty in elder patients with femoral neck fractures provided better hip functional outcome and lower morbidity and mortality as compared to hemiarthroplasty group. THA could be considered as priority based treatment modality for femoral neck fractures patients than HA due to higher Harris hip scores and lesser complications.

Keywords: Femoral neck fractures, Hemiarthroplasty, Total hip arthroplasty

INTRODUCTION

Displaced femoral neck fracture is the most common fracture which leads to higher morbidity and mortality among elderly population. Arthroplasty is considered as the standard treatment for displaced femoral neck fractures allowing patient's early mobilization [1, 2]. Total hip arthroplasty (THA) and hemiarthroplasty (HA) are widely used arthroplasty for treating femoral neck fractures. Though THA is superior in certain aspects such as hip pain, reoperation rate and function but had higher dislocation rate compared to HA. The hemiarthroplasty usually had less complication after surgery, lower initial cost, lesser blood loss [3, 4]. Hip fractures are posing as an epidemic problem due to the rising incidence of hip fractures with an increasing population of elderly people [5]. Femoral neck fracture occurs mostly in minor falling or twisting injuries among elderly population [6]. Osteoporosis, diseases of multiple comorbidities, decrease physical activity, and malnutrition are different predisposing factors for femoral fractures in elder patients [7, 8].

Hip fractures patients are more susceptible to significant risk for major health complications, mortality, and reduced life's quality [9]. Irrespective of higher frequency of injury, the surgical management of femoral neck fractures in elderly patients remains tentative. The two alternate treatment options include hemiarthroplasty involves femoral head replacement with prosthesis and total hip arthroplasty involves acetabulum and femoral head both replaced with prosthesis [10]. The main purpose of the treatment should be to regain the patient's pre-morbid functional status which could be achieved through replacement, with either total hip arthroplasty or hemiarthroplasty. The present study aimed to compare the hemiarthroplasty and total hip arthroplasty in elderly patients with displaced femoral neck fractures.

METHODOLOGY

This retrospective cohort study was conducted on 20 displaced femoral neck fractures patients in the Department of Orthopedic, QAMC/BVH Bahawalpur from January 2021 to August 2022. Prior to study conduction, ethical approval was taken from the institute research and ethical committee. Written informed consent was obtained from each individual. Patients aged >60 years and had femoral neck fractures were enrolled. Rheumatoid arthritis in fracture hip patients, non-ambulatory patients, and pathological fracture patients were excluded. Patients were categorized into two groups; group-I patients undergoing hemiarthroplasty and group-II patients undergoing total hip arthroplasty. Full assessment of each patient included clinical, biochemistry, radiological, and standard primary care. Post-operative complications such as fracture, medical issues, dislocation, surgical site infection, and mortality (1 year) were assessed in both groups. Harris Hip Score (HHS) was used for the assessment of function outcome at one month, three months, six months, and twelve months.

All the patients admitted for surgery were given skin traction applied to lower limb in order to have pain relief and shortening prevention. Anteroposterior view and Pelvic radiograph of bilateral hips were taken from each patient. Prior to surgery, patients were declared fit by anesthesia department. All the patients were administered with 1.5 g cefuroxime, intravenous antibiotic prophylaxis 30 minutes before skin incision. Moore's posterior approach was used for operating the hips. As per standard protocol, deep venous thrombosis was prevented with Prophylactic dose of LMWH 12 hours before surgery. Both groups had similar rehabilitation. Average discharge time was five to seven days. Full weight bearing and active exercises were started within three days of surgery. Harris Hip score was used for the assessment of

functional outcome. Regular follow-ups were maintained for all the patients after one month, three months, six months, and twelve months.

SPSS version 25 was used for data analysis. All the quantitative variables were expressed as mean and standard deviation. Continuous or qualitative variables were described as frequency and percentage. Chi-square test was used for comparing the categorical variables between two groups. Continuous variables were compared using unpaired t-test. Paired t-test was used for comparing the mean changes in Harris Hip scores. All the descriptive statistics were done using 95% confidence interval and 5% level of significance.

RESULTS

Of the total 20 femoral neck fractures patients, 10 patients underwent hemiarthroplasty and 10 underwent total hip arthroplasty. The overall mean age was 69.44±7.91 years. Demographic details or baseline features were almost similar in both groups. During follow-ups, patients who underwent total hip arthroplasty (group-II) had higher Harris hip score than group-I patients. The mean HHS score in group-I patients were 61.53, 68.24, 70.81, and 76.16 at follow-up visit after one month, three months, six months, and twelve months respectively while In group-II, the mean HHS score were 66.23, 69.82, 73.25, and 78.92 respectively. Demographic details of all the patients are shown in Table-I. Gender's distribution is represented in Figure-1. Harris Hip scores for both groups were compared in Table-II. Post-operative outcomes is illustrated in Figure-2.

Table-1: Demographic details of all the participants

Variables	Hemiarthroplasty (N=10)	Total Hip arthroplasty (N=10)	P-value
Age (years)	69.32 ± 8.23	69.56±7.57	0.51
Gender			0.49
Male	3 (15)	4 (20)	
Females	7 (35)	6 (30)	
Duration of surgery (minutes)	58.27 ± 6.29	129.25 ± 19.42	<0.001
Blood loss (ml)	329.82 ± 35.73	561.91 ± 46.11	<0.001
Hospital stay (days)	6.8 ± 3.6	5.9 ± 2.5	0.09
Follow-up (months)	19.5 ± 5.7	18.8 ± 4.9	0.31
Pre-op HHS	69.6 ± 9.5	71.6 ± 5.8	0.11
Post-op HSS	67.78 ± 9.6	75.35 ± 6.3	0.01

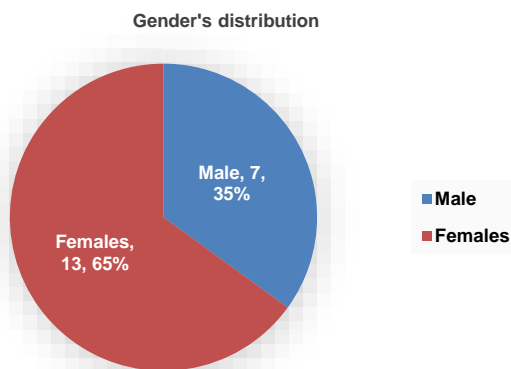


Figure-1: Gender's distribution (n=20)

Table-2: Comparison of Harris Hip Score in both groups

Time Period (months)	Hemiarthroplasty HHS	Total hip arthroplasty HSS	P-value
One	61.53	66.23	0.19
Three	68.24	69.82	0.32
Six	70.81	73.25	0.38
Twelve	76.16	78.92	0.47

Table-3: Post-operative outcomes measured in both groups

Outcomes	Hemiarthroplasty (N=10) HHS N (%)	Total hip arthroplasty (N=10) HSS N (%)
Surgical site infection	2 (20)	1 (10)
Pulmonary Embolism	1 (10)	1 (10)
Acute Kidney Injury	2 (20)	2 (20)
Dislocation		
Myocardial Infarction	2 (20)	1 (10)
No complications	2 (20)	5 (50)
Mortality	1 (10)	0 (0)

DISCUSSION

The present study mainly focused on comparing the two alternate arthroplasty namely hemiarthroplasty and total hip arthroplasty in terms of surgical site infection, pulmonary embolism, myocardial infarction, blood loss, and surgery duration among 20 elderly patients. It has been found that total hip arthroplasty in older patients with femoral neck fractures provided better hip functional outcome and lower morbidity and mortality as compared to hemiarthroplasty group. Similarly, a previous study reported that hemiarthroplasty is a preferred modality for femoral fractures due to low functional demand and limited life expectancy [11]. Total hip arthroplasty requires more time and precision, and can provide better results in younger patients having more functional demand and higher life expectancy [12, 13]. In our study, demographic details and baseline characteristics were similar in both HA and THA groups. Female's dominance was seen in both groups, however, based on gender comparability, there were no statistical significance.

In the present study, factors such as blood transfusion amount, surgery duration, and blood loss were significantly lower in hemiarthroplasty than total hip arthroplasty. Surgery duration and amount of blood loss is significantly associated with treatment outcomes in elderly patients. These findings are consistent with the findings of previous studies conducted in the Indian and Western population [14, 15]. Displaced femoral neck fracture patients are more susceptible to infections due to the huge amount of blood loss and increased surgical duration. Though, blood loss and surgery duration was significantly increased in THA group but higher complications were reported in HA group. Similar findings were seen in a study conducted by Ofa et al [16] and Craig et al [17]. The total duration of hospitalization in both groups were inconsistent, therefore, was considered unreliable as similar observations were made by Wang et al [18].

In our study, functional outcomes were compared by Harris hip score. In the total hip arthroplasty group, the HHS was significantly higher than the hemiarthroplasty group. Harris hip score generally ranges from 0 to 100 points. Subdomains such as function, pain, motion range, and deformity are included in HSS. In the current investigation, function and pain scores were better in total hip arthroplasty group patients. Similarly, In THA group, the HSS at the end of a month, three months, six months, and twelve months were higher than HA group.

Femoral neck fracture is associated with different complications that could be managed by arthroplasty as described in various studies [19, 20]. These complications involve deep vein thrombosis, infection, and mobilization delay. All these complications are immediate after surgery. However, late complications are dislocation, implant loosening, implant failure, and periprosthetic fractures. Mode of arthroplasty is significantly associated with certain complications [21, 22]. Complications of both types (immediate or late) were observed in the present study. Surgical site infections were the most prevalent complication in both groups. M.C Tol et al. [23] conducted their study on arthroplasty for femoral neck fracture and found that implant impingement causing pain, acetabular wear, femoral head protrusion into the acetabulum were prevalent in HA group. In the total hip arthroplasty group, the dislocation risk was more prevalent. No dislocation has been reported in either group. In

comparison of HA to THA, HA is significantly related to the surgery revision due to acetabular erosion [24].

The present study has certain limitations in terms of sample size. Larger sample size is recommended for prospective randomized trials. Function status was better in total hip arthroplasty as compared to the hemiarthroplasty. Many studies reported better outcomes in patients underwent total hip arthroplasty [25, 26].

CONCLUSION

Our study concluded that total hip arthroplasty in elder patients with femoral neck fractures provided better hip functional outcome and lower morbidity and mortality as compared to hemiarthroplasty group. THA would be considered as priority based treatment modality for femoral neck fractures patients than HA due to higher Harris hip scores and lesser complications.

REFERENCES

- Chatterji G, Shukla S, Singhania S, et al. (September 24, 2022) A Prospective Study Comparing the Functional Outcome of Bipolar Hemiarthroplasty Versus Total Hip Replacement in Elderly Patients With Fracture of the Neck of Femur. *Cureus* 14(9): e29529. DOI:10.7759/cureus.29529.
- B. Boukebous, P. Boutroux, R. Zahi, C. Azmy, P. Guillon, Comparison of dual mobility total hip arthroplasty and bipolar arthroplasty for femoral neck fractures: a retrospective case-control study of 199 hips, *Orthop. Traumatol. Surg. Res.* 104 (3) (2018) 369–375.
- Bhandari M, Swiontkowski M. Management of acute hip fracture. *N Engl J Med* 2017;377:2053-62.
- Lewis DP, Wæver D, Thorninger R, Donnelly WJ. Hemiarthroplasty vs total hip arthroplasty for the management of displaced neck of femur fractures: a systematic review and meta-analysis. *J Arthroplasty* 2019;34(8):1837.e2-1843.e2.
- Bhandari M, Devereaux PJ, Einhorn TA, et al. Hip Fracture Evaluation with Alternatives of Total Hip Arthroplasty versus Hemiarthroplasty (HEALTH): protocol for a multicentre randomised trial. *BMJ Open* 2015;5(2):e006263.
- Zhang Y, Alyass A, Vanniyasingam T, et al. A systematic survey of the methods literature on the reporting quality and optimal methods of handling participants with missing outcome data for continuous outcomes in randomized controlled trials. *J Clin Epidemiol* 2017;88:67-80.
- M.G. Grosso, J.R. Danoff, D.E. Padgett, R. Iorio, W.B. Macaulay The cemented unipolar prosthesis for the management of displaced femoral neck fractures in the dependent osteopenic elderly *J Arthroplasty*, 31 (2016), pp. 1040-1046
- L.M. Ko, W. Hozack, The dual mobility cup: what problems does it solve? *Bone Jt. J.* 98 (1_Suppl_A) (2016) 60–63.
- R.A. Agha, M.R. Borrelli, M. Vella-Baldacchino, R. Thavayogan, D.P. Orgill, The STROCSS statement: strengthening the reporting of cohort studies in surgery, *Int. J. Surg.* 46 (2017) 198–202.
- Mukka S, Mellner C, Knutsson B, Sayed-Noor A, Skoldenberg O. Substantially higher prevalence of postoperative peri-prosthetic fractures in octogenarians with hip fractures operated with a cemented, polished tapered stem rather than an anatomic stem. *Acta Orthop.* 2016 Jun;87(3):257-61. Epub 2016 Apr 4.
- Tol MC, van den Bekerom MP, Sierevelt IN, Hilverdink EF, Raaymakers EL, Goslings JC. Hemiarthroplasty or total hip arthroplasty for the treatment of a displaced intracapsular fracture in active elderly patients: 12-year follow-up of randomised trial. *Bone Joint J.* 2017 Feb;99-B(2):250-4.
- Roberts HJ, Barry J, Nguyen K, Vail T, Kandemir U, Rogers S, Ward D. 2021 John Charnley Award: A protocol-based strategy when using hemiarthroplasty or total hip arthroplasty for femoral neck fractures decreases mortality, length of stay, and complications. *The Bone & Joint Journal.* 2021 Jul 1;103(7 Suppl B):3-8.
- Hayden BL, Varady NH, Abdeen R, Lozano-Calderon SA, Chen AF, Ready JE, Antonelli B, Merchan N, Anderson ME, Ali M. No Difference Between Hemiarthroplasty and Total Hip Arthroplasty in the Treatment of Pathologic Femoral Neck Fractures. *The Journal of Arthroplasty.* 2021 Nov 1;36(11):3662-6.
- Stucinskas J, Grigaitis K, Smailys A, Robertsson O, Tarasevicius S. Bipolar hemiarthroplasty versus total hip arthroplasty in femoral neck fracture patients: results from Lithuanian Arthroplasty Register. *HIP International.* 2021 Sep;31(5):691-5.
- Craig J, McDonald J, Cassidy R, McDonald S, Barr J, Diamond O. Clinical Outcomes for Hemiarthroplasty Versus Total Hip Arthroplasty in Patients With Femoral Neck Fracture Who Meet Published National Criteria for Total Hip Arthroplasty. *Journal of Orthopaedic Trauma.* 2022 Jan 1;36(1):17-22.
- Ofa SA, Lupica GM, Lee OC, Sherman WF. Complications following total hip arthroplasty and hemiarthroplasty for femoral neck fractures in patients with a history of lumbar spinal fusion. *Archives of Orthopaedic and Trauma Surgery.* 2021 Sep 30:1-11.
- Craig J, McDonald J, Cassidy R, McDonald S, Barr J, Diamond O. Clinical Outcomes for Hemiarthroplasty Versus Total Hip Arthroplasty in Patients With Femoral Neck Fracture Who Meet Published National Criteria for Total Hip Arthroplasty. *Journal of Orthopaedic Trauma.* 2022 Jan 1;36(1):17-22.
- Wang F, Zhang H, Zhang Z, Ma C, Feng X: Comparison of bipolar hemiarthroplasty and total hip arthroplasty for displaced femoral neck fractures in the healthy elderly: a meta-analysis. *BMC Musculoskelet Disord.* 2015, 16:229. 10.1186/s12891-015-0696
- Z. Jia, F. Ding, Y. Wu, W. Li, H. Li, D. Wang, et al. Unipolar versus bipolar hemiarthroplasty for displaced femoral neck fractures: a systematic review and meta-analysis of randomized controlled trials *J Orthop Surg Res*, 24 (2015), pp. 10-18
- M.J. Grosso, J.R. Danoff, T.S. Murtaugh, D.P. Trofa, A.N. Sawires, W.B. Macaulay Hemiarthroplasty for displaced femoral neck fractures in the elderly has a low conversion rate *J Arthroplasty*, 32 (2017), pp. 150-154.
- W.W. Schairer, J.M. Lane, D.A. Halsey, R. Iorio, D.E. Padgett, A.S. McLawhorn Total hip arthroplasty for femoral neck fracture is not a typical DRG 470: a propensity-matched cohort study *Clin Orthop Relat Res*, 475 (2017), pp. 353-360.
- A. Terrier, A. Latypova, M. Guillemin, V. Parvex, O. Guyen Dual mobility cups provide biomechanical advantages in situations at risk for dislocation: a finite element analysis *Int Orthop*, 41 (2017), pp. 551-556.
- M.C. Tol, M.P. van den Bekerom, I.N. Sierevelt, E.F. Hilverdink, E.L. Raaymakers, J.C. Goslings Hemiarthroplasty or total hip arthroplasty for the treatment of a displaced intracapsular fracture in active elderly patients: a 12-year follow-up of randomised trial *Bone Joint J*, 99 (2017), pp. 250-254.
- S. Svenøy, M. Westberg, W. Figved, H. Valland, O.C. Brun, H. Wangen, et al. Posterior versus lateral approach for hemiarthroplasty after femoral neck fracture: early complications in a prospective cohort of 583 patients *Injury*, 48 (2017), pp. 1565-1569.
- C. Rogmark, O. Leonardsson Hip arthroplasty for the treatment of displaced fractures of the femoral neck in elderly patients *Bone Joint J*, 98 (2016), pp. 291-297
- B.J. Miller, J.J. Callaghan, P. Cram, M. Karam, J.L. Marsh, N.O. Noiseux Changing trends in the treatment of femoral neck fractures: a review of the American Board of Orthopaedic surgery database *J Bone Joint Surg Am*, 96 (2014), p. e149