

Utility of Panoramic Radiograph for Assessment of Mandibular Asymmetry as Compared with Posteroanterior Cephalogram

MUHAMMAD AFRASIAB KHAN¹, ASIF HAIDER², MUHAMMAD NOMAN³, FAIZA⁴, SARAH SABIR⁵, ABID ALI⁶, NOMAN ALI⁷

¹Centre of Forensic and Legal Medicine and Dentistry, University of Dundee, Dundee, Scotland.

²Demonstrator, Department of Operative Dentistry and Endodontics, Shifa College of Dentistry, Islamabad.

³Department of Orthodontics, Sharif Medical and Dental College, Lahore.

⁴Department of Dental Materials, Riphah International University, Islamabad.

⁵Khyber College of Dentistry, Peshawar.

⁶Centre of Forensic and Legal Medicine and Dentistry, University of Dundee, Dundee, Scotland.

⁷Department Operative Dentistry and Endodontics, Fatima Memorial Dental Hospital, Lahore.

Corresponding author: Asif Haider, Email: haiderasif803@gmail.com

ABSTRACT

Objective: Was to assess the mandibular asymmetry on panoramic radiograph (OPG) as compared to PA (posterior anterior) cephalogram.

Materials and method: A total of 15 participant's records with age above 12 years; both genders; Pakistani nationals; clear OPG and PA cephalogram available; and full biodata available were included. Radiographs of participants with unerupted or missing teeth in anterior or posterior region were excluded. Three linear measurements (condylar, ramus, and body length) and one angular measurement (gonial angle) were performed on both OPG and PA cephalograms. Paired t test and Pearson correlation test were applied between OPG and PA cephalogram for condylar, ramus, and body length and gonial angle to see the relationship.

Results: The females were 6(40%) and males were 9(60%). The mean condylar length measured on OPG was 8.44 ± 2.96 mm and on PA cephalogram was 9.98 ± 2.73 mm with mean difference of 1.5mm and no statistical difference ($p=0.1007$). Similarly the ramus length ($p=0.706$), corpus length ($p=0.066$) and gonial angle ($p=0.333$) were not statistically different measured on OPG and PA cephalogram. Very high correlation was found for measurements on OPG and PA cephalogram for condylar length ($r=0.97$), ramus length ($r=0.96$), body length ($r=0.93$) and was very highly statistically significant ($p<0.001$). But the correlation for gonial angle was moderate and not statistically significant ($p=0.035$).

Conclusion: The panoramic radiograph can be used for initial diagnosis of mandibular asymmetry.

Keywords: Mandibular asymmetry, panoramic radiograph, posterior-anterior cephalogram

INTRODUCTION

Orthodontic care is provided to the patients for achieving a well balanced and harmonious facial appearance.¹ Some mild asymmetry in facial area is very common and acceptable. The range of asymmetry varies from unnoticeable to gross asymmetry.²

The etiology of asymmetry in mandibular region are: traumatic insults; developmental malformation; muscular problems like torticollis; syndromes like Treacher Collins; occlusal prematurities; and pathologies of joint like rheumatoid arthritis.^{3,4}

Asymmetry of mandible is not rare condition and usually diagnosed using a combination of diagnostic aids like clinical assessment, analysis of patient's photographs, lateral cephalogram, panoramic radiograph (OPG), posteroanterior (PA) cephalogram, computed tomography, stereometry, and Technitium-99 scintigraphy etc.⁵⁻⁷ The disadvantages of the additional radiographs are increased radiation hazard, extra expenses and ultimately lack of feasibility for patients.⁸

Panoramic radiograph (OPG) is readily available in routine practice allowing bilateral view of mandibular horizontal and vertical measurements. Literature showed that horizontal measurement cannot be reliably recorded on OPG due to image distortion⁹ but vertical measurements are reliable.¹⁰

Previous study conducted on 10 patients reported that no significant difference exist between OPG and PA cephalogram for length of condyle, ramus, mandibular body and gonial angle.¹¹

There is lack of research in our population. OPG is readily available tool in orthodontic patients. The diagnosis of mandibular asymmetry had great impact on orthodontic treatment. This study can provide the knowledge about reliability of OPG in diagnosis of mandibular asymmetry.

The objective of this study was to assess mandibular asymmetry on OPG as compared to PA cephalogram.

MATERIALS AND METHOD

This cross sectional analytical study was conducted on 15 patient's records available in department of orthodontics, Khyber College of Dentistry, Peshawar. An ethical approval was taken from ethical committee of the hospital before the inception of data collection.

The inclusion criteria were patients with mandibular asymmetry; age above 12 years; both genders; Pakistani nationals; clear OPG and PA cephalogram; and full biodata available. Radiographs of participants with unerupted or missing teeth in anterior or posterior region were excluded (Missing and unerupted teeth can affect vertical growth of jaws).

Age and gender were recorded from record files of the patients. Both PA cephalograms and OPGs were traced manually using lead pencil and acetate paper on illuminator. Three linear measurements (condylar, ramus, and body length) and one angular measurement (gonial angle) were performed on both OPG and PA cephalograms. The condylar length was measured from condyliion (Co) to sigmoid notch. The length of ramus was measured from Co to gonion (Go). The mandibular body length was measured from Go to menton (Me). The gonial angle was traced and measured between Co-Go and Go-Me planes.

Data analysis was done in SPSS 22. Descriptive statistics were computed in the form mean and SD for continuous data and percentages for qualitative variable. Paired t test and Pearson correlation test were applied between OPG and PA cephalogram for condylar, ramus, body length and gonial angle to see the relationship. The level of significance for paired t test was $p \leq 0.05$ and Pearson correlation test was $p \leq 0.01$.

RESULTS

The females were 6(40%) and males were 9(60%). The most common age group was 16-30 years ($n=9$, 60%) followed by 31-45 years ($n=6$, 40%). (**Table 1**) The mean condylar length measured on OPG was 8.44 ± 2.96 mm and on PA cephalogram was 9.98 ± 2.73 mm with mean difference of 1.5mm and no statistical difference ($p=0.1007$). Similarly the ramus length ($p=0.706$), corpus length ($p=0.066$) and gonial angle ($p=0.333$) were not statistically different measured on OPG and PA cephalogram. (**Table 2**)

Very high correlation was found for measurements on OPG and PA cephalogram for condylar length($r=0.97$), ramus length ($r=0.96$) and body length ($r=0.93$) and these were very highly statistically significant ($p<0.001$). But the correlation for gonial

angle was moderate and not statistically significant ($p=0.035$). **(Table 3)** Fig 1 shows the correlation of condylar length measured on both OPG and PA cephalogram. The coefficient of determination is very high ($r^2=0.94$).

Table 1: Frequency of gender and age of the participants

Variable	Characteristic	n(%)
Gender	Female	6(40.00)
	Male	9(60.00)
Age group (years)	16-30	9 (60.00)
	31-45	6 (40.00)

Table 2: Comparison of condylar, ramus, corpus length and gonial angle measured on OPG and PA cephalograms

Characteristic (mm)	OPG, n = 15 ¹	PA ceph, n = 15 ¹	Difference ²	95% CI ^{2,3}	p-value ²
Length condyle	8.44 ± 2.96	9.98 ± 2.73	-1.5	-3.7, 0.30	0.1007
Length ramus	47 ± 7	48 ± 7	-1	-6.1, 4.06	0.706
Length corpus	71 ± 9	82 ± 16	-10	-21, 1.84	0.066
Gonial angle	132 ± 25	142 ± 26	-9.6	-29, 9.5	0.333

¹Paired t test

Table 3: Correlation of linear and angular measurement on OPG and PA cephalogram

Measurement	Pearson correlation coefficient (r)	P-value
Condylar length	0.97	<0.001
Ramus length	0.96	<0.001
Body length	0.93	<0.001
Gonial angle	0.54	0.035

¹Significant level, $p<0.01$

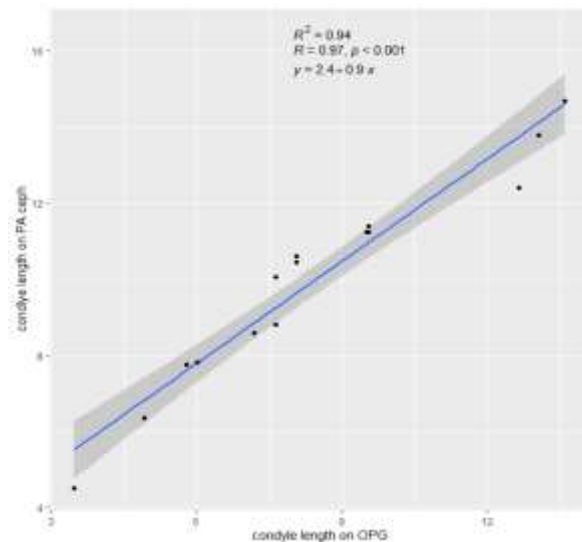


Fig 1: Correlation of condylar length measured on both OPG and PA cephalogram.

DISCUSSION

This study was aimed to assess the mandibular asymmetry on OPG as compared to PA cephalogram. Our results revealed that both linear and angular measurements were not different measured on both OPG and PA cephalograms. Our findings also revealed that very high correlation for linear measurements between OPG and PA cephalogram but not significant and moderate correlation for gonial angle.

While diagnosing mandibular asymmetry the difference between left and right side are calculated for ramus, condylar and body length and gonial angle. Mandibular asymmetry is one of the challenging malocclusion to treat.³ It can be due to functional prematurity, dental malrelations, skeletal and pathological causes.⁶ Most important and initial step in the management of mandibular asymmetry is the proper diagnosis. The ideal diagnostic tool should be: readily available; not harmful to clinician and patients; should quantify the mandibular asymmetry with accuracy; and cheaper. Many diagnostic aids are available to diagnose mandibular asymmetry like PA cephalogram, cone beam computed tomography, CT, and stereophotogrammetry.^{12, 13} PA

cephalogram is commonly used in practice for evaluation of mandibular asymmetry but this radiograph is associated with extra radiation hazard to the patients.

Panoramic radiograph is readily available in all orthodontic patients' diagnostic records. Our findings showed that OPG can be used reliably for diagnosis of mandibular asymmetry. Previous study conducted on 10 patients reported that no significant difference exist between OPG and PA cephalogram for length of condyle, ramus, mandibular body and gonial angle. Their results also showed that correlation for all measurements on OPG and PA cephalogram was also higher.¹¹ These results are in consistent with our findings. Other studies also reported that OPG can be used for diagnosis for mandibular asymmetry with reliability.^{10, 14, 15}

This study has some limitations: first, this is small sample size; second, single centered; and third, this is of retrospective design.

CONCLUSION

Within limitation of this study it can be concluded that the panoramic radiograph can be used for initial diagnosis of mandibular asymmetry. However, clinicians should use best of their ability and modern diagnostic aid while providing care to patients with mandibular asymmetry.

REFERENCES

- Vale F, Nunes C, Guimarães A, Paula AB, Francisco I. Surgical-Orthodontic Diagnosis and Treatment Planning in an Asymmetric Skeletal Class III Patient—A Case Report. *Symmetry*. 2021;13(7):1150.
- Primožic J, Perinetti G, Zhurov A, Richmond S, Ovsenik M. Assessment of facial asymmetry in growing subjects with a three-dimensional laser scanning system. *Orthod Craniofac Res*. 2012;15(4):237-44.
- López DF, Botero JR, Muñoz JM, Cárdenas-Perilla R, Moreno M. Are there mandibular morphological differences in the various facial asymmetry etiologies? A tomographic three-dimensional reconstruction study. *J Oral Maxillofac Surg*. 2019;77(11):2324-38.
- Chia MS, Naini FB, Gill DS. The aetiology, diagnosis and management of mandibular asymmetry. *Orthod Update*. 2008;1(2):44-52.
- Chan B, Leung Y. SPECT bone scintigraphy for the assessment of condylar growth activity in mandibular asymmetry: is it accurate? *Int J Oral Maxillofac Surg*. 2018;47(4):470-9.
- Solem RC, Ruellas A, Miller A, Kelly K, Ricks-Oddie JL, Cevidanis L. Congenital and acquired mandibular asymmetry: Mapping growth and remodeling in 3 dimensions. *Am J Orthod Dentofacial Orthop*. 2016;150(2):238-51.
- Bajaj K, Rathee P, Jain P, Panwar VR. Comparison of the reliability of anatomic landmarks based on PA cephalometric radiographs and 3D CT scans in patients with facial asymmetry. *Int J Clin Pediatr Dent*. 2011;4(3):213.
- Lee J-Y, Han S-H, Ryu H-S, Lee H-M, Kim S-C. Cone-beam computed tomography analysis of transverse dental compensation in patients with skeletal Class III malocclusion and facial asymmetry. *Korean J Orthod*. 2018;48(6):357-66.
- Gupta S, Jain S. Orthopantomographic analysis for assessment of mandibular asymmetry. *J Indian Orthod Soc*. 2012;46(1):33-7.

10. Akcam MO, Altioek T, Ozdiler E. Panoramic radiographs: A tool for investigating skeletal pattern. *Am J Orthod Dentofacial Orthop* 2003;123:175-8.
11. Agrawal A, Bagga D, Agrawal P, Bhutani R. An evaluation of panoramic radiograph to assess mandibular asymmetry as compared to posteroanterior cephalogram. *APOS Trends Orthod*. 2015;5(5):197-201.
12. Ng WH, Goh BT, Lim AAT, Tan MH. Mandibular asymmetry: Is there a difference in the bone and soft tissue thickness between both sides? *Oral Surg Oral Med Oral Pathol Oral Rad*. 2022;1:23-30.
13. AlHadidi A, Cevidanes L, Mol A, Ludlow J, Styner M. Comparison of two methods for quantitative assessment of mandibular asymmetry using cone beam computed tomography image volumes. *Dentomaxillofac Radiol*. 2011;40(6):351-7.
14. Saglam AM. The condylar asymmetry measurements in different skeletal patterns. *J Oral Rehabil* 2003;30:738-42.
15. Liukkonen M, Sillanmaki L, Peltomaki T. Mandibular asymmetry in healthy children. *Acta Odontol Scand* 2005;63:168-72.