

# Protective Effect of *Ocimum Gratissimum* Against Lead Induced Histological Changes in Rabbit Liver

FATIMA QAISER<sup>1</sup>, SHAKEELA NAZIR<sup>2</sup>, ASHIQ HUSSAIN<sup>3</sup>, ASMA KAZI<sup>4</sup>, AISHA AZIZ<sup>5</sup>, MAHEEN RANA<sup>6</sup>

<sup>1</sup>Professor of anatomy Rashid Latif medical college Lahore

<sup>2</sup>Professor of anatomy Rashid Latif medical college Lahore

<sup>3</sup>Associate professor of Anatomy Sahiwal Medical College, Sahiwal

<sup>4</sup>Associate Professor Department Medicine Rashid Latif Medical College Lahore

<sup>5</sup>Assistant Professor Medicine Department Rashid Latif Medical College Lahore

<sup>6</sup>Assistant Professor Pathology Department Rashid Latif Medical College Lahore

Correspondence to: Fatima Qaiser

## ABSTRACT

**Background:** Since it is well-established that lead exposure can have negative effects on hematological, biochemical, and hepatic parameters, a significant number of research efforts have been focused on antioxidants that are capable of treating as well as preventing these alterations.

**Objective:** The purpose of this study was to explore the influence of *Ocimum Gratissimum* (OG) extract on the hemato-biochemical parameters of the livers of adult Wistar rats and the lead-induced toxicity of the livers.

**Method:** For the aim of this investigation, a total of 70 adult Wistar rats were separated into seven groups, with each group containing 10 rats. Group A acted as the control group, Group B received 120 mg/kg of lead, and Group C received 375 mg/kg of OG. Group A was the only group that received no treatment. The role of the control group was played by Group A. Before administering the OG dosages of 375 and 750 mg/kg to Group D and Group E, respectively, a lead dose of 120 mg/kg was administered to both groups. In Group F, participants received 375 mg/kg of OG extract followed by 120 mg/kg of lead, whereas in Group G, participants received 120 mg/kg of lead followed by 1,190 mg/kg of ascorbic acid. After the conclusion of each oral treatment, which lasted a total of 21 days, the animals were slaughtered and their blood and liver tissues were collected for subsequent histological and biochemical testing. The results of these tests will be shown in the following paragraphs.

**Results:** The research led to the discovery that the Control group had a rise in their average body weight, but the B group experienced a fall in their weight. The findings of the biochemical tests revealed that when compared to the Control group and the other treatment groups, the levels of liver enzymes such as ALT, AST, GGT, and ALP in Group B were considerably higher than in the other treatment groups ( $p < 0.05$ ). The results of the histological analysis of the liver tissues revealed degenerative alterations, such as localized necrosis and aggregated inflammatory cells in Group B. These findings were found in the liver tissues of the group B patients. In contrast, the liver tissue in Groups D, E, F, and G that had been treated with the extract exhibited ameliorative alterations. These results may be seen in the table below.

## INTRODUCTION

The manipulation of lead for the objectives stated above has polluted the surrounding area. Lead is a heavy metal that is present in a variety of compounds, both organic and inorganic, that are utilized in the production of goods. These compounds can be found in a variety of places. These compounds can be found in things like explosives, rodenticide, coatings used to prevent rust in iron and steel, batteries, X-ray equipment, eye cosmetics, gasoline, electric cables, water pipes, and storage tanks, to name a few examples. It is possible for lead to accumulate in the body's nerve tissues, kidneys, and liver, which can eventually result in lead poisoning, commonly known as painter's colic. According to research carried out by Kim et al. (2015), lead is one of the variables that might contribute to the development of anemia. This is due to the fact that lead inhibits the action of three key enzymes that are involved in the process of producing hem. According to Wu (2006), the maximum level of lead that should be present in the blood of a normal adult should be approximately 25 g/dL or lower, and the threshold for lead exposure in children should be 10 g/dL; however, this threshold was recently lowered to 5 g/dL or less based on a report from the Center for Disease Control. According to Wu (2006), the maximum level of lead that should be present in the blood of a normal adult should be approximately 25 g/dL or (2012). Blood lead levels for adults should be decreased to below 10 g/dL, and the threshold for occupational lead exposure in random blood tests should not be higher than 30 g/dL. It has been established that the tissues of the liver contain roughly 33% of lead, which places it in the position of having the largest repository among soft tissues. This places the liver in the position of being the most toxic organ in the human body. Exposure to lead causes harm to a wide variety of tissues and interferes with the normal metabolic processes that occur in the body. Lead is harmful because it produces an increase in the development of reactive oxygen species and oxidative stress, both of which, in the long run, lead to modifications in the DNA. Another way that lead is harmful

is because it causes an increase in the formation of lead. *Ocimum gratissimum* is a species of plant native to tropical climates that contains antioxidant action. Natural plant remedies, such as *Ocimum gratissimum*, have been utilized to alleviate the harmful effects caused to the tissue. This is mostly owing to the antioxidant capabilities of these plants, which have been used to treat the condition.

The savanna and coastal regions of Nigeria are where the most bulk of this plant's habitat may be found. *Ocimum gratissimum* has a long history of use in the traditional medicine of many different countries, in addition to its use in the culinary and condiment sectors and in the process of preparing meals. The ability of dietary antioxidants to perform the role of therapeutic agents and their applications in the prevention of a wide range of diseases have garnered a significant amount of interest among researchers. These research have led to the identification of a variety of bioactive components of plants, including flavonoids, phenolics, limonoids, carotenoids, coumarins, and phytosterols, all of which have a variety of beneficial effects on medical treatment and overall well-being. In the current study, we wanted to determine how much of an effect an extract of *Ocimum gratissimum* leaves had on the modifications that lead exposure had on the hepatobiochemical parameters of adult Wistar rats. Specifically, we wanted to know how much of an effect the extract had.

**Animal grouping:** The experiment was conducted with a total of 70 mature Wistar rats, and the mean weight of these rats was (80 + 40) g. These rats were divided up into seven groups, with a maximum of ten animals in each group. Two weeks were spent at the animal shelter getting the animals acquainted to their new surroundings and helping them adjust. During the course of the experiment, the rats were divided up into seven groups, each consisting of five individuals, and provided with a standard diet as well as unrestricted access to a supply of water.

**Experimental protocol:** The suitable quantity of the extract was determined by applying the LD50 value, which was found to be 1,250 milligrams per kilogram of body weight. To prepare the stock solution, 700 grams of the extract were dissolved in one thousand milliliters of distilled water. It was determined that 60% of the LD50 should be used for the high dose (750 mg/kg body weight), whereas only 30% should be used for the low dose (375 mg/kg body weight). Throughout the entirety of the trial, Group 1 functioned as the control and received nothing except food and drink. When compared to Group 3, which received just 375 mg of OG per kilogram, Group 2 was only given a total of 120 mg of lead per kilogram of body weight. In the case of Group 4, a lead dose of 120 mg/kg and an OG extract dose of 375 mg/kg were administered, whereas in the case of Group 5, a lead dose of 120 mg/kg and an OG extract dose of 750 mg/kg were administered. Following the protocols of Okechukwu et al., the rats in Group 6 were first given 375 mg/kg of OG extract for a period of two weeks, and then they were given 120 mg/kg of lead for a period of one week. This was done in accordance with the procedures. In Group 7, the rats received 120 mg/kg of lead in addition to 1190 mg/kg of ascorbic acid (Vitamin C). This combination was administered to them (2019)

**RESULTS**

The findings that were presented demonstrated that there was a statistically significant increase ( $p < 0.005$ ) in the mean weight of the animals and organs in Groups B and E when compared with Group A (Control), but there was no statistically significant difference when Groups C and F were considered. These findings were presented.

The findings revealed that Group B had a significantly larger white blood cell count when contrasted with Groups A, C, D, E, and F. ( $p < 0.005$ ). When compared to Groups A and E, the amounts of hemoglobin that were discovered in Group B did not demonstrate a statistically significant difference when analyzed using the data presented. On the other hand, when contrasted with Groups C, D, F, and G, the result demonstrated a statistically significant decrease ( $p < 0.005$ ).

The findings of the differential white blood cell count revealed that Group B had a considerably lower number of monocytes and neutrophils than Group A ( $p < 0.005$ ), although Groups C and D did not differ from one another in a statistically significant way. When compared to Groups A, C, D, E, and F, as shown in Table 1, there was a significant increase in the number of lymphocytes and eosinophil in Group B; however, there was not a significant decrease when compared with Group F. The findings of this comparison are significant from a statistical point of view. The findings of the liver function test showed that Group B had significantly greater levels of ALT, ALP, and GGT than the other groups, including Groups A, C, D, and G. In addition, Group B had significantly lower levels of GGT than the other groups ( $p < 0.005$ ). According to the findings, Group B had a considerably lower red blood cell count and packed cell volume than Groups A, C, D, E, and F ( $p < 0.005$ ), as can be shown in Table 1. Additionally, Group B had a significantly higher white blood cell count than Group G.

Groups	ALP (IU/L)	ALT (IU/L)	AST (IU/L)	GGT (IU/L)
A	126.3 ± 7.43	82.21 ± 1.34	125.2 ± 6.82	12.98 ± 0.99
B	160.1 ± 3.11	74.15 ± 1.99	157.15 ± 8.12	11.98 ± 0.04
C	159.0 ± 6.78	66.352 ± 1.95	131.88 ± 3.34	11.67 ± 0.99
D	149.2 ± 4.56	69.42 ± 1.04	140.2 ± 5.21	11.32 ± 0.07
E	141.8 ± 4.06	64.39 ± 4.54	126.14 ± 1.38	10.32 ± 0.04
F	144.12 ± 6.82	70.23 ± 2.01	137.71 ± 3.00	10.48 ± 0.20
G	140.04 ± 7.88	67.42 ± 3.69	130.13 ± 2.99	10.19 ± 0.88

Table 1: The liver function test in the Rats.

**Histological studies:** The results of the histological investigations showed that the participants who were assigned to Group A (Control) had normal hepatic structures within their livers. These structures included hepatocytes, central veins, and sinusoids among other organ components (as seen in Figure 1). As can be

observed in Figure 2, the liver tissues of the rats that were only ever exposed to lead (Group B) showed considerable deformation along with focal aggregation of inflammatory cells. On the other hand, the liver tissues of the rats in the other group showed neither of these effects. As can be observed in Figure 3, the liver tissues of Group C had normal hepatic anatomy with a Central Vein (CV) and hepatocytes (H) that were comparable to those of the Control group. This was in contrast to the liver tissues of the Control group, which showed abnormal hepatic morphology. As can be observed in Figure 4, the liver tissues of the rats that were assigned to Group D had a level of congestion of the central vein that was considered to be moderate.

The histological structure of the liver tissues of the animals in Groups E and F, which are depicted in Figures 5 and Figure 6, respectively, was normal when contrasted with the livers of the animals in Group 2, which are shown in Figure 2. The histological structure of the liver tissues of the animals in Group G, which is depicted in Figure 7, was likewise normal. This can be seen in the image.

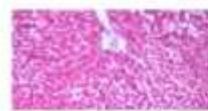


Fig 1: A section of the liver of Group A (Control) animals showing normal hepatic structure with Central Vein, Hepatocytes and Sinusoids

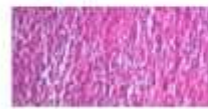

Fig 2: A section of the liver of Group B animals induced with only lead showing distortion of hepatic structure



Fig 3: A section of the liver of Group C animals administered with *Ocimum gratissimum* only showing normal hepatic structure.



Fig 4: A Section of the liver of Group D animals administered with 375 mg/kg *Ocimum gratissimum* and 120 mg/kg lead acetate



Fig 5: A section of the liver of Group E animals administered with 750 mg/kg of *Ocimum gratissimum* and 120 mg/kg of lead acetate

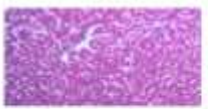

Fig 6: A Section of the liver of Group F animals administered with 375 mg/kg of *Ocimum gratissimum* for two weeks and then 120 mg/kg of lead acetate.

**DISCUSSION**

The present study showed progressive increase in the body weight of experimental animal models throughout the period. However, no weight loss was observed throughout the week of experiment which could be as a result of ad libitum method of feeding. The

result was in agreement with the reports of Rabelo et al., (2003) and Rossi (2008) . The increase in body weight of the animals could be due to the active components found in the extract which are good for the body . We observed a reduced physical activities and increase rate of respiration which might be attributed to reduction in energy generation due to hypoxia caused by met hemoglobin formation which agrees with that of Philip and Gerson (1994); and Yu et al., (2004) . Furthermore, the results showed a significant increase in the liver weight of rats treated with *Ocimum gratissimum* when compared to the Control Group which was not in agreement with Rossi (2008) as increase in the liver of animals have been shown to be a sign of hepatotoxicity. Balance in the activities of serum enzyme markers such as AST, ALT, GGT and ALP is used to mark the functionality of a normal liver. If the liver produces very high level of AST and ALT and releases such into the blood stream, it signifies danger called hepatocellular necrosis. Increased level of ALT presents a sign of liver injury because it represents 90% of whole body total enzymes . The activities of ALP relate to the liver cells functioning and it has been shown that increase in its activity as a result of increased production in the presence of increased biliary pressure . In analyzing the liver enzymes, we noticed a significant increase in ALT, AST, ALP and GGT in Group B when compared to control. The histological examination revealed the toxic effects of lead on the liver such as distortion, focal necrosis and aggregation of inflammatory cells in Figure 2 while sections of liver treated with extract of OG revealed that the extract has ameliorating effects on. Also Group F when compared with Group G showed normal hepatic architecture with central vein, hepatocytes and sinusoids. The apparent decrease in the mean body weight when Group B were compared with Group A might have resulted from the hypoglycemic and the diuretic effect of the extract. There was a significant reduction in the weight of the animals that received only lead compared to the control during the experimental period, and this decrease may be due to the reduction in food intake [24- 25]. Generally, weight loss may be the attribute of low food intake, hormonal balance disturbances or direct cytotoxic effect of lead. In analyzing our hematological parameters, we recorded a decrease in PCV, RBC and Hb concentration in the given lead alone which may be as a result of anemia as a consequence of the toxic effect of lead on bone marrow, spleen and liver. Imaizumi et al., (1980) and Wu (2006) had reported that this reduction might be due to lead administration, which was accompanied by a remarkable increase of met hemoglobin level but increase in white blood cell

concentration was also recorded . There was also a significant decrease in monocytes and neutrophils and an increase concentration of lymphocytes.

## REFERENCES

1. Jaishankar, M., Tseten, T., Anbalagan, N., Mathew, B. B. & Beeregowda, K. N. Toxicity, mechanism and health effects of some heavy metals. *Interdiscip. Toxicol.* 7, 60–72 (2014).
2. Kim, J. H. & Kang, J. C. The lead accumulation and hematological findings in juvenile rock fish *Sebastes schlegelii* exposed to the dietary lead (II) concentrations. *Ecotoxicol. Environ. Saf.* 115, 33–39 (2015).
3. Bradberry, S. M. Metals (cobalt, copper, lead, mercury). *Medicine(United Kingdom)* 44, 182–184 (2016)
4. Wani, A. L., Ara, A. & Usmani, J. A. Lead toxicity: A review. *Interdiscip. Toxicol.* 8, 55–64 (2015).
5. Haridy, M., Al-Amgad, Z., Sakai, H. & Mohi-Eldin, M. Ameliorating effects of garlic, calcium, and vitamin C on chronic lead toxicity in albino rats. *Comp. Clin. Pathol.* 23, 1215–1223 (2014).
6. Baselt RC. Disposition of toxic drugs and chemicals in man. 9th ed. Foster City, California: Biomedical Publications. 2011.
7. National Institute for Occupational Safety and Health (NIOSH). Adult Blood Lead Epidemiology & Surveillance. 2015. Accessed 20 October, 2019.
8. Mudipalli A. Lead hepatotoxicity and potential health effects. *Indian J Med Res.* 2007;126:518-527.
9. Haouas Z, Sallem A, Zidi I, Hichri H, Mzali I, Mehdi M. Hepatotoxic effects of lead acetate in Rats: histopathological and cytotoxic studies. *J Cytol Histol.* 2014;5:256.
10. Sivaprasad R, Nagaraj M, Varalakshmi P. Combined efficacies of lipoic acid and 2,3-dimercaptosuccinic acid against lead-induced lipid peroxidation in rat liver. *J Nutr Biochem.* 2004;15:18-23.
11. Zhang J, Wang XF, Lu ZB, Liu NQ, Zhao BL. The effects of meso2,3-dimercaptosuccinic acid and oligomeric procyanidins on acute lead neurotoxicity in rat hippocampus. *Free Radic Biol Med.* 2004;37:1037- 1050.
12. Jurczuk M, Brzóska MM, Moniuszko Jakoniuk J. Hepatic and renal concentrations of vitamins E and C in lead and ethanol-exposed rats. An assessment of their involvement in the mechanisms of peroxidative damage. *Food Chem Toxicol.* 2007;45:1478-1486.
13. Xu J, Lian LJ, Wu C, Wang XF, Fu WY. Lead induces oxidative stress, DNA damage and alteration of p53, Bax and Bcl-2 expressions in mice. *Food Chem Toxicol.* 2008; 46:1488-1494.
14. Dawang ND. Phytochemical constituents and toxicological study of *Vitex doniana* leaf. *J Pharma Biol Sci.* 2015;10:23-27. 20. Hajieva P, Behl C. Antioxidants as a potential therapy against agerelated neurodegenerative diseases: amyloid Beta toxicity and Alzheimer's disease. *Curr Pharm Des.* 2006;12:699-704.