

To Evaluate the Management of Epididymo-Orchitis at Tertiary Care Hospital

ALTAF HUSSAIN GHUMRO¹, INAYAT ALI ZARDARI², SADIA AYOUB³, MASHOOQ ALI KHOWAJA⁴, AIJAZ HUSSAIN MEMON⁵, ZULFIQAR ALI IMTIAZ MEMON⁶

¹Assistant Professor Surgical Unit 1 People's University Of Medical And Health Sciences Nawabshah

²Assistant Professor, Surgical Unit 1 People's University Of Medical And Health Sciences Nawabshah

³Senior Registrar, Surgical Unit 1 People's University Of Medical And Health Sciences Nawabshah

⁴Associate Professor, Surgical Unit 1 People's University Of Medical And Health Sciences Nawabshah

⁵Assistant Professor Urology People's University Of Medical And Health Sciences Nawabshah

⁶Assistant Professor , Surgical Unit 1 People's University Of Medical And Health Sciences Nawabshah

Corresponding author: Altaf Hussain Ghumro, Email altafkhadim@yahoo.com, Cell: 03337560170

ABSTRACT

Introduction: Epididymo-orchitis is common condition in scrotum found in surgical practice. It is commonly seen in young males. It can occur at any age. The common age is between 2nd to 4th decades of life. Its duration of illness is 6 weeks in acute condition and 12 weeks in chronic conditions. It mostly occurs associated with sexually transmitted diseases. Chlamydia trachomatis and Neisseria gonorrhoea are the common causative organisms. After age 40, the common organisms causing this disease are Escherichia Coli and Coliform bacteria found on G.I.T. There are also other causes of this disease. It is mostly managed conservatively but it can be operated if the condition develops complications. Even Orchidectomy is also done in some conditions.

Objective: To evaluate the management options in epididymo-orchitis .

Material methods: This is a cross sectional study done at surgical Unit 1 of Peoples Medical Hospital (PMCH) Nawabshah. The duration of study was one year from 10th August 2019 to 9th July 2020. All the patients were admitted through Surgical out Patient Department (SOPD) and emergency department of Peoples Medical College Hospital (PMCH) Nawabshah. Approval of study was taken from Ethical committee. Detailed history and thorough clinical examination was done. Routine investigations were done apart from viral markers including HIV. Urine DR and Culture ,Ultrasound of Scrotum and CT Scan were done. Management was planned accordingly.

Results: Total 65 patients were included in this study. Of them, 20 (31%) had left sided pathology, 40 (61%) had right sided and 5(8%) had bilateral. Testicular abscess formation was seen in 8 (12.3%) patients. In 2 (3.07%) patients, testicular infarction was noted. 1 (1.5%) patient became infertile due to bilateral involvement. 3 (4.6%) patients had developed psychosis.

Conclusion: It is concluded that most of the patients were treated conservatively and in a few patients, incision drainage and orchidectomy was performed.

Keywords: Epididymo-orchitis, Neisseria Gonorrhoea, E.Coli, Incision Drainage, Orchidectomy.

INTRODUCTION

Epididymitis is simply defined as inflammation of epididymis. Because of its proximity to testis, epididymitis spread to testis and the condition is called epididymo-orchitis. It is the most common cause of scrotal pain in adults. In United States, more than 600,000 men are affected in a year.¹ Epididymitis occur at any age but mostly the disease occurs at the age between 20-40 years. Acute epididymitis lasts less than 6 weeks where as chronic condition is more than 12 weeks. It is mostly associated with sexually transmitted diseases. Chlamydia trachomatis and Neisseria gonorrhoea are the common causative organisms and 50% of cases are caused by these organisms below the age of 40 years. After age 40, the common organisms causing this disease are Escherichia Coli and Coliform bacteria found on G.I.T. Prior to sexual maturity, this disease is also caused by bacteria.² Chemical epididymitis, though rarely occurred, is the result of having sexual intercourse with full bladder resulting in retrograde flow of urine. Some drugs named "Amiodarone" also are also responsible for causing this disease. Viral infections like "Mumps" are also involved as causative agents. It also occurs as a result of trauma or repetitive activities such as sports.^{3,4}

Scrotal pain and swelling are the most common symptoms. These develop over the course of several days. There is often a recent history of dysuria or urethral discharge. Fever is also noted in all patients. In chronic disease, painful point tenderness is present and regular/irregular epididymis on palpation.⁵ If untreated, the major complications of epididymitis are abscess formation and testicular infarction. Chronic disease causes permanent damage to epididymis and testicle which eventually results in infertility or hypogonadism and there are chances of spread of this infection to other organs of the body.^{6,7}

For diagnosis, urinalysis is done to detect the presence/absence of red blood cells/ white blood cells. Urine culture is also done to determine the micro-organism responsible

for the disease. Urethral swab is also indicated where the sexually transmitted disease is suspected.⁸ Radio logically, ultrasonography especially Doppler one is very imperative to know the anatomy and vascular flow to testicle. Computed tomography is also indicated in cases having history of ureterolithiasis. It is significant to differentiate it from testicular torsion.⁹

Treatment of epididymitis either acute illness or chronic one is done by antibiotics but according to the causative agents. Though the treatment is started keeping in view the common organisms causing this disease like C.Trachomatis, N. gonorrhoea, and E.coli. The treatment of choice is azithromycin and cefixime to cover both gonorrhoea and Chlamydia. Fluoroquinolones are no longer recommended due to resistance of gonorrhoea to this class. For sexually transmitted diseases, Ceftriaxone along with doxycycline is recommended. Azithromycin is also alternative drug.¹⁰ Fluoroquinolones may be used in older patients where enteric organism is suspected. In chronic epididymitis, four to six weeks course of antibiotics are prescribed to ensure complete eradication of any bacterial cause. Oxifloxacin or levofloxacin are recommended in cases caused by enteric organisms such E.Coli. Household remedies such as elevation of scrotum and cold compresses applied regularly to scrotum have dramatic results of relieving pain and swelling. Painkillers or anti-inflammatory drugs are often used to treat acute or chronic conditions. Hospitalization is recommended in severe cases. Surgical removal of epididymis (epididymectomy) is rarely indicated. In cases with unrelenting testicular pain, orchidectomy is done.¹¹

Rationale of Study: The rationale of study is to dig out the outcome of management of epididymitis so that patients may be treated early and be saved from developing complications particularly infertility that might have enormous psychological trauma to patients.

MATERIAL AND METHODS

This is a cross sectional study done at surgical Unit 1 of Peoples Medical Hospital (PMCH) Nawabshah. The duration of study was one year from 10th August 2019 to 9th July 2020. All the patients were admitted through Surgical out Patient Department (SOPD) and emergency department of Peoples Medical College Hospital (PMCH) Nawabshah. Approval of study was taken from Ethical committee. All patients presented with painful scrotum and swelling that was gradual in onset rather than acute. Some patients had also complained of urinary symptoms such as dysuria, urgency, frequency, and also urinary incontinence. History of trauma was also taken. Past medical history of urinary tract infection, prostatitis or any surgery. On physical examination, tenderness was positive. Swelling was hyperthermic and indurated. In some patients, inguinal lymph adenopathy was noted. Examination of penis demonstrated urethral discharge in some patients. On digital rectal examination, tenderness was seen due to prostatitis. Cardiac fitness and anesthesia fitness was taken of the patients who had developed complications like testicular abscess and those who had non-viable testis. Routine investigations were done apart from viral markers including HIV. Urine DR and Culture was done to get information of bacteria involved. Ultrasound of Scrotum was obtained and in few patients Doppler Ultrasound was done to rule out any ischemia or venous congestion. Computed Tomography was also done in Some Patients. antibiotic therapy was started immediately such as Third generation cephalosporins and Doxycycline was added to cover Chlamydia Trachomatis. Anti-inflammatory drugs were also given along with analgesics. Those patients having developed complications were prepared for surgery accordingly. Cardiac and anesthesia fitness were obtained. Patients were undergone orchidectomy who has diagnosis of non viable/necrotic testis.

RESULTS

Total 65 patients were included in this study. Of them, 20 (31%) had left sided pathology, 40 (61%) had right sided and 5(8%) had bilateral (Chart No.1). Of total, 55 (84.6%) had acute epididymo-orchitis and Chronic epididymitis was noted to be present in 10 (15.3 %) (Chart No.2).

Age of patients was also differed. Epididymitis was found to be present in patients aged between 20 to 65 years. Average age was 32 years. 25(38.4%) patients age was between 20 to 30 years. 25(38.4%) patients aged between 31-40 years. Only 10 (15.3%) patients age was between 41-50 years. 5 (7.6%) patients age was 51-65 years (Table No.1).

All 65(100%) patients developed scrotal pain. Swelling was seen in 40(61.5%) patients. Fever was noted in 45(69.2%) patients. Painful point tenderness was in all 65(100%) patients. Testicular abscess formation was seen in 8 (12.3%) patients. In 2 (3.07%) patients, testicular infarction was noted. 1 (1.5%) patient became infertile due to bilateral involvement. 3 (4.6%) patients had developed psychosis (Table No.1).

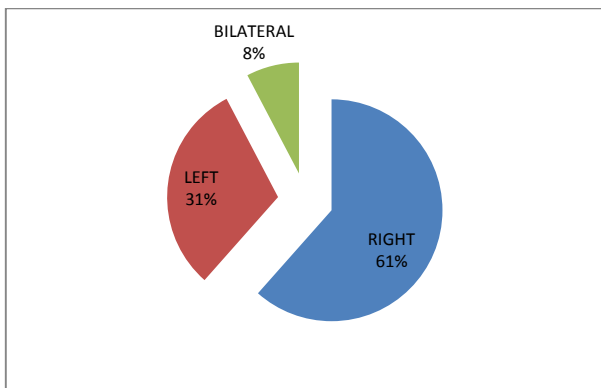


Chart 1: Site of Pathology

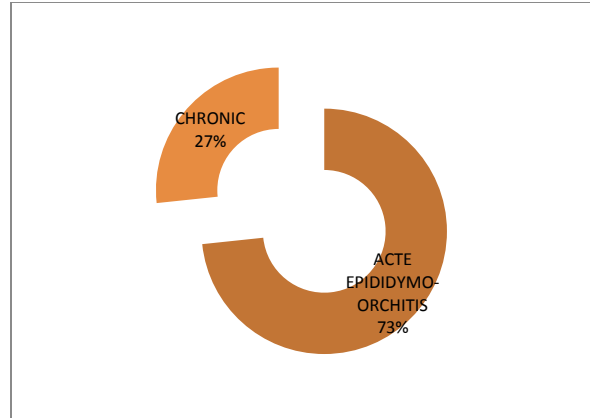


Chart 2: Doughnut Showing Status of Disease

Table-1: Descriptive Statistics (n=65)

Variable	Frequency (n)	Percentage (%)
AGE (Years)		
• 20-30 years	25	38.4 %
• 31-40 years	25	38.4 %
• 41-50 years	10	15.3%
• 51-65 years	5	7.6%
Clinical features		
• Scrotal pain	65	100%
• Swelling	40	61.5%
• Fever	45	69.2%
• Painfulpoint tenderness	65	100%
• Regular/irregular epididymis	30	46.1%
Complications of Epididymo-Orchitis		
• Testicular Abscess	8	12.3%
• Testicular infarction	2	3.07%
• Testicular atrophy	1	1.5%
• Infertility	1	1.5%
• Psychology trauma	3	4.6%
Management of Complications of Epididymo Orchitis		
• Conservative	54	83%
• Incision Drainage	8	12.3%
• Orchidectomy	3	4.6%

DISCUSSION

Epididymo-orchitis is the common condition presenting in acute or chronic forms. Acute condition is represented by pain and inflammation whereas chronic condition only has pain. It could be infectious or non-infectious. Bacterial entry through the uro-genital tract is the common cause in acute condition. Recent studies have concluded that sexually active patients should be screened for sexually transmitted diseases. Most of the bacteria respond to third generation cephalosporins. Mostly these conditions are treated conservatively unless the complications occur and rarely intervention is required.¹²

Structural urologic abnormalities are commonly seen in Children and old age patients. Siegal al el found that 47% of pre-pubertal boys with this condition had associated uro-genital abnormalities.¹³

Acute condition is most common in men of age group between 20-59 years, it is 43% in men aged between 20-39 years and 29% of age between 40-59 years. In our study, the age of patients was between 20-65 years. The condition most commonly present was of age group 20-30 and 31-40 with proportion of 38.4% and 38.4% respectively. In a study done in Spain, acute epididymo-orchitis (EO) presented 28.4% in acute form. In our study, the acute condition was found to be present in 73% of patients.^{14,15}

Mostly, the patients recover on conservative therapy and complications are very rare but some studies showed slightly increased complication rate. The complications of this condition

are very dangerous. Sometimes, patients undergo excision of the organ such as orchidectomy. The pathogenesis of testicular infarct is poorly understood. Inflammatory infiltration, thromboses and bacterial exotoxins are thought to play role. In acute conditions, hyperaemia and vascular congestion are associated with an acute inflammatory process.¹⁶ Desai et al studied 33 men with EO and concluded that 39% patients had developed complications including suppurative necrosis, late atrophy and infarction. Mittermeyer et al study showed scrotal abscess formation in 3-5% patients. In our study, total complication rate is 22.97%. Testicular abscess was seen in 12.3% and testicular infarction in 3.07%. Testicular atrophy was found in 1.5%. Infertility was reported in 1.5% because of bilateral involvement of testis. Psychological trauma was also noted in 4.6% patients in our study

CONCLUSION

It is concluded that most of the patients responded to conservative treatment but a few were undergone for surgical option.

REFERENCES

1. Fehily SR, Trubiano JA, McLean C, Teoh BW, Grummet JP, Cherry CL, et al. . Testicular loss following bacterial epididymo-orchitis: case report and literature review. *Can Urol Assoc J* 2015;9:148–151.
2. Adrian Rudd, Masood Mughal, Gareth Reid. Epididymo-orchitis causing testicular infarction: a serious complication of a common disorder. *J SurgCase Rep* 2017;23:213-217.
3. Liu W, Li YY, Shang XJ. [Mycoplasma genitalium and male urogenital diseases: An update]. *Zhonghua Nan Ke Xue*. 2018 Jul;24(7):645-650.
4. Louette A, Krahn J, Caine V, Ha S, Lau TTY, Singh AE. Treatment of Acute Epididymitis: A Systematic Review and Discussion of the Implications for Treatment Based on Etiology. *Sex Transm Dis*. 2018 Dec;45(12):104-108.
5. Shigemura K, Kitagawa K, Nomi M, Yanagiuchi A, Sengoku A, Fujisawa M. Risk factors for febrile genito-urinary infection in the catheterized patients by with spinal cord injury-associated chronic neurogenic lower urinary tract dysfunction evaluated by urodynamic study and cystography: a retrospective study. *World J Urol*. 2020 ;38(3):733-740.
6. Fernández-Pérez GC, Tardáguila FM, Velasco M, Rivas C, Dos Santos J, Cambronero J, et al. . Radiologic findings of segmental testicular infarction. *Am J Roentgenol* 2005;184:1587–93.
7. Chorba T, Scholes D, Bluespruce J, Operskalski BH, Irwin K. Sexually transmitted diseases and managed care: an inquiry and review of issues affecting service delivery. *Am J Med Qual* 2004;19:145–56.
8. Agrawal V, Ranjan R. Scrotal abscess consequent on syphilitic epididymo-orchitis. *Trop Doct*. 2019 Jan;49(1):45-47.
9. Agrawal V, Jha AK, Dahiya D. Clinical, radiological, cytological, and microbiological assessment of painful extratesticular lesions. *Urol Ann*. 2018 ;10(2):181-184.
10. Bandarkar AN, Blask AR. Testicular torsion with preserved flow: key sonographic features and value-added approach to diagnosis. *Pediatr Radiol*. 2018 ;48(5):735-744.
11. Ryan L, Daly P, Cullen I, Doyle M. Epididymo-orchitis caused by enteric organisms in men >35 years old: beyond fluoroquinolones. *Eur J Clin Microbiol Infect Dis*. 2018;37(6):1001-1008.
12. Tan WP, Levine LA. What Can We Do for Chronic Scrotal Content Pain? *World J Mens Health*. 2017 ;35(3):146-155.
13. Fonseca EKUN, Tomazoni D, Enge Júnior DJ, do Amaral E Castro A. Inferno sign in epididymo-orchitis. *Abdom Radiol (NY)*. 2017 ;42(12):2955-2956.
14. Bodie M, Gale-Rowe M, Alexandre S, Auguste U, Tomas K, Martin I. Addressing the rising rates of gonorrhoea and drug-resistant gonorrhoea: There is no time like the present. *Can Commun Dis Rep*. 2019 ;45(2-3):54-62.
15. Yamamichi F, Shigemura K, Arakawa S, Fujisawa M. What are the differences between older and younger patients with epididymitis? *Investig Clin Urol*. 2017 ;58(3):205-209.
16. Janier M, Dupin N, Derancourt C, Caumes E, Timsit FJ, Méria P., la section MST de la SFD. [Epididymo-orchitis]. *Ann Dermatol Venereol*. 2016 ;143(11):765-766.
17. Lampejo T, Abdulcadir M, Day S. Retrospective review of the management of epididymo-orchitis in a London-based level 3 sexual health clinic: an audit of clinical practice. *Int J STD AIDS*. 2017 ;28(10):1038-1040.