

Role of Magnetic Resonance Imaging Findings in Adults Presenting with New-Onset Seizures

NAILA TAMKEEN¹, GHAZALA WAHID², HADIA GUL³, NEELUM ANWAAR⁴, MARIA MUSAMMAR⁵, RABEEA EHTESHAM⁶

^{1,2}Assistant Professor Radiology, HMC, Peshawar

³Consultant Radiologist, Peshawar Institute of Cardiology, Peshawar

⁴Consultant Radiologist, Islamabad Diagnostic Centre

⁵Post Graduate Resident, Radiology Department, HMC Peshawar

⁶Post Graduate Resident, Radiology Department, HMC Peshawar

Corresponding author: Ghazala Wahid, Email: ghazalawahid3@gmail.com

ABSTRACT

Background: New-onset seizure can be potential life threatening condition. It raises the suspicion of intracranial abnormality or a primary epilepsy. These are mostly diagnosed and differentiated clinically, however diagnostic imaging has important role in evaluating the cause of seizure. Previously studies done on neuroimaging in seizures have mostly focused on assessment of seizures in children or adults in acute emergency however this study focused on new onset seizures in adults. Magnetic Resonance Imaging (MRI) is readily available in tertiary care hospitals these days and is important diagnostic modality for evaluating the causes of new-onset seizure in adults.

Aims and Objectives:

The purpose of this study was to discuss the magnetic resonance imaging finding in adult patients presenting with new-onset seizure and if the MRI established the cause for the patient's new onset seizure

Methods:

This was prospective cross sectional study done in 330 adult patients above age of 18 year who presented with new-onset seizures from May 2020 to April 2021. These patients were referred to Radiology department Hayatabad Medical Complex to evaluate intracranial abnormality and to find out the cause of seizure. MRI brain was performed on 1.5T machine and images were independently reviewed by two consultant Radiologists. The findings were summarized and categorized into a study database.

Results: In our study 330 adults presenting with new onset seizures underwent MRI within 48 hours of seizure. The mean age was 47 yrs. MRI determined the cause of new-onset seizure in 139 (42.1%) patients while 191(57.9%) studies were normal. The most common findings were encephalomalacia with gliosis related to previous trauma, chronic infarcts and surgery (38.1%), primary/metastatic brain tumour (24.4%), infectious encephalitis and meningitis (15.8%), venous sinus thrombosis (8.6%), while and PRESS (7.2%) and vascular malformation (5.7%) were less common findings. Patients with focal seizures had a higher proportion of potentially epileptogenic lesions (64.7%) compared with those with seizures of generalized onset (10.8%) or uncertain type (24.6%)

Conclusion: This study emphasizes the importance of magnetic resonance imaging in adults presenting with acute seizures and its usefulness in determining the epileptogenic lesions and helps in planning the treatment strategy.

Keywords: Seizures, Magnetic resonance imaging, Intracranial abnormality.

INTRODUCTION

A seizure is a event represented by signs and symptoms due to uncontrolled, abnormal excessive electrical activity in the brain¹. The prevalence of new onset seizures are more common in developing countries as compared to developed countries, the reason being high incidence of infections, lack of health facilities and awareness and other factors². True seizures should be differentiated from seizure mimics, like migraine, syncope, and psychogenic non epileptic seizure³. Seizures can be focal or generalized depending upon the causative factor, however focal seizures are more common in adults. Causative lesions are more commonly found on imaging in focal seizures. Seizures can be either provoked or unprovoked. Provoked seizures (acute symptomatic seizures) occur due to acquired lesions like electrolyte imbalance, toxins, trauma to head, tumors, infective/inflammatory etiology, vascular insults and many other causes⁴. The history and neurologic examination, are crucial to assess the patient who presented with first seizure^{5,6}. The presence of a focal neurologic deficit in such patients on clinical examination is commonly associated with intracranial pathology at neuroimaging^{7,8}.

Neuroimaging plays fundamental role to find out the cause of seizures, predict the prognosis and improve treatment plan as well as monitoring of the lesion whether it is progressive or static⁹. Computed tomography (CT) scan is readily available and comparatively cheap tool for neuroimaging, however it is less sensitive to detect lesion in focal seizures¹⁰. MR imaging of patients with new onset seizures has increased sensitivity and enables the radiologists to determine underlying causative intracranial abnormalities¹¹. In infective etiologies, MRI is helpful in identifying the probable infective/inflammatory agent and

planning effective adequate microbial care^{12,13}. Neuroimaging should be done with epilepsy protocol including thin slice T1-weighted acquisitions in axial and coronal planes obtained, as high resolution has higher yield than standard protocol¹⁴. Post gadolinium contrast-enhanced sequences are also very useful for assessment of seizures in adults to exclude neoplastic causes. Susceptibility-weighted sequences helps to determine vascular insults like cavernomas and micro hemorrhages¹⁵. Most of the time epilepsy protocol MRI can identify the causative lesion of seizures however some of the important causative lesions cannot be diagnosed by it. Also sometimes there is no detectable lesion of seizures on MRI which is indicator of poor prognosis and poor treatment response^{16,17}. So the limitations of MRI in assessment of seizures should be considered and use of further advanced MRI techniques and sequences, clinical data and EEG findings should be incorporated to improve the yield of MRI and treatment strategy¹⁸. Higher field strength imaging like 3 T MRI or even 7T magnets, use of phased array surface coils will improve the identifying of small lesions^{19,20}. However these advanced MRI equipment and technique will benefit those patients whose initial traditional MRI studies is inconclusive¹⁸.

MATERIAL AND METHODS

This was prospective cross sectional study done in which 330 adult patients who presented with new-onset seizures. The duration of study was from May 2020 to April 2021. These patients were referred to Radiology departments Hayatabad Medical Complex to evaluate intracranial abnormality and to find out the cause of seizure. Approval from ethical committee of HMC was taken.

Both male and female patients with age 18 yrs and above who presented within 48 hrs of witnessed new onset seizure were

included in the study. Patients with already diagnosed epilepsy, recurrent episodes of seizures, non witnessed seizures, patients in whom MRI is contraindicated and patients younger than 18 years were excluded from the study. Those patients who presented with new onset seizures after 48 hrs were also excluded from the study.

MRI brain was performed on 1.5T MRI machine (Philips) and Epilepsy protocol was used. Multiplanar and multisequential Images were taken without and with intravenous injection of contrast. Images were independently reviewed by two consultant Radiologists. Both normal and abnormal MRI findings with presence of epileptogenic were recorded. Data was also stratified by clinical and demographic characteristics like age, gender and EEG record. The findings were summarized and categorized into a study database

RESULTS

In our study 330 adults underwent MRI within 48 hours of new onset seizure. Among 330 patients that underwent MRI, 139 (42.1%) patients had abnormal MRI findings while 191(57.9%) studies were normal. The most common findings were encephalomalacia with gliosis related to previous trauma, chronic infarcts and surgery 38.1% (n=53), primary/metastatic brain tumour 24.4% (n=34), infectious/inflammatory encephalitis and meningitis 15.8% (n=22), venous sinus thrombosis 8.6% (n=12), while PRESS 7.2% (n=10) and vascular malformation 5.7% (n=8) were less common findings.

Patients with focal seizures had a higher proportion of potentially epileptogenic lesions (64.7%) compared with those with seizures of generalized onset (10.8%) or uncertain type (24.5%). Age range of patients was from 18-88 years with mean age of 45 yrs. It was found that Epileptogenic lesion were more common in age group of 41-60 yrs accounting for 45.3% (n=63). Epileptogenic lesion were more common in males as compared to females.

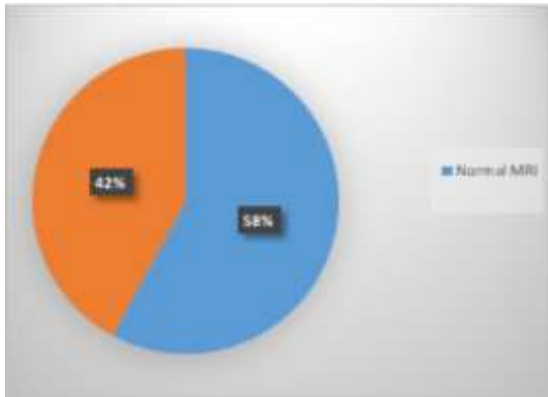


Figure 1: Frequency of abnormal MRI vs Normal MRI in seizures

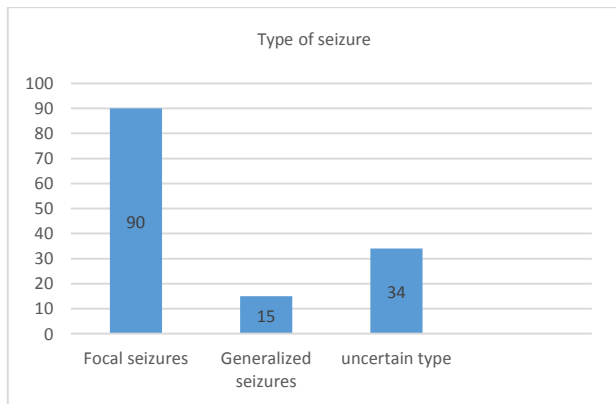


Figure 2: Type of Seizures

Table 1: Causative lesions of seizures on MRI

S.No	MRI Findings	No. of Patients (n=139)	Percentage (%)
1.	Encephalomalacia with Gliosis	53	38.1
2	Primary/Metastatic brain tumours	34	24.4
3	Infectious encephalitis/meningitis	22	15.8
4	Venous sinus thrombosis	12	8.6
5	Posterior reversible encephalopathy syndrome	10	7.2
6	Vascular malformation	8	5.7

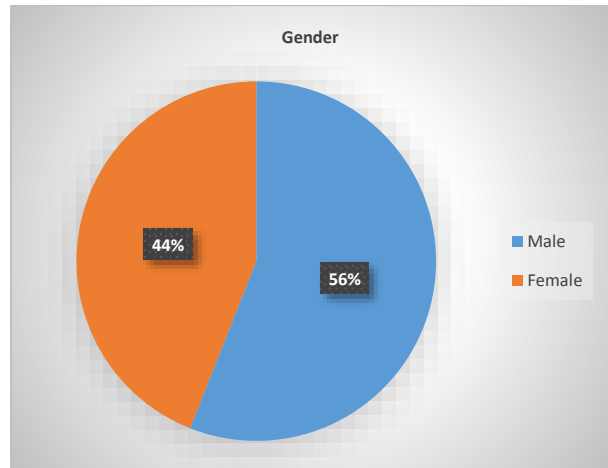


Figure 3: Gender distribution in patients with abnormal MRI findings.

Table 2: Age distribution in patients with abnormal MRI findings

S.No	Age group in Years	Number of patients(n=139)	Percentage (%)
1	18-40 yrs	32	23
2	41-60 yrs	63	45.3
3	61-80 yrs	30	21.6
4	Above 80 years	16	11.5

DISCUSSION

Seizure disorder is commonly presented in adults and has different causes which need to be identified timely²¹. It is agreed that All the adults presenting with new onset seizure should be investigated thoroughly and should undergo neuroimaging either with CT scan or MRI²². Neuro imaging play important role to identify intracranial cause of the seizure and for prognostic counselling²³. MRI has fundamental role to evaluate the new onset seizures²⁴. MRI is more relevant than CT for the evaluating new onset seizure as it has high sensitivity, particularly in non emergency situation²³.

In our study MRI detected the cause of new-onset seizure in 42.1% patients which is comparable to the study done by Olszewska and Costello et al²⁵ 2014 who found that MRI identified the epileptogenic lesion in 44% patients. However in contrast to our study, Arabi et al²⁶ 2018 found that MRI identified epileptogenic cause in 67% cases in his study. This is probably due to fact that patient above age of 60 year were only enrolled in the study and so the age factor influenced the results. Secondly patients underwent MRI on 3 T machine which has high spatial resolution and sensitivity to detect the abnormality.

The most common cause of seizure in our study was encephalomalacia with gliosis which is comparable to the study done by Hakami et al²⁷ 2013 in which the most common cause of seizure in adults was encephalomalacia. The second most common cause of seizures in our study was brain tumors which is comparable to the study done by Arabi et al²⁶ 2018 who also found that prior vascular insults and tumors as important causes of seizures in adults.

It was also revealed in our study that epileptogenic lesion are more common in patients resenting with focal seizures then those with generalized or non specific seizures. A study done by Guanzhong et al²⁸ 2020 indicated that abnormal MRI finding were more common in patients having focal seizures. This finding is also comparable to the study done by Hakami et al²⁷ 2013 in which it was found that adult patients presenting with focal seizures has high chance of intracranial abnormality.

There are many studies conducted in past about usefulness of MRI in seizures, however these studies were mostly retrospective and done on children .Secondly most of studies were based on CT findings in seizures in acute emergency. Our study is prospective and take in account the causes of new onset seizure in adult patients. The results of this study can be very helpful to clinician as it emphasizes on the importance of MRI in seizures and early management of patient can be done. Also the causes of seizures can be identified from the study.

There are some limitation in this study .The sample size was inadequate and data collected from one hospital only .Also the patient resenting with seizures in emergency setting and outpatients were not considered in this study. Further studies should be done with large sample size, multicenter data and patient with acute seizures in emergency setting should be considered to address these limitations..

CONCLUSION

MRI has very important role in evaluation of adult patients presenting with first seizure as MRI can determine the lesion and timely management of potential epilptogenic lesion can be done .MRI is also very useful in patients presenting acutely for whom the initial Computed tomography is inconclusive and for those presenting with new-onset seizure in the non acute setting.

REFERENCES

- Ahnliide JA, Rosen I, Linden-Mickelsson Tech P, et al. Does SISCOM contribute to favorable seizure outcome after epilepsy surgery? *Epilepsia*. 2007;48:579–588.
- Sander JW . The epidemiology of epilepsy revisited . *Curr. Opin. Neurol*. 2006; 16 (2): 165 – 170.
- Widdess-WP, Diehl B, Najm I . Neuroimaging of focal cortical dysplasia . *J. Neuroimag*.2006;16 (3):185 – 196.
- Huff JS, Fountain NB. Pathophysiology and definitions of seizures and status epilepticus. *Emerg Med Clin North Am*. 2011 Feb;29(1):1-13.
- Gavvala JR, Schuele SU. New-onset seizure in adults and adolescents: a review. *JAMA* 2016; 316:2657–68
- Nowacki TA, Jirsch JD. Evaluation of the first seizure patient: key points in the history and physical examination. *Seizure* 2017; 49:54–63
- Tardy B, Lafond P, Convers P, et al. Adult first generalized seizure: etiology, biological tests, EEG, CT scan, in an ED. *Am J Emerg Med*. 1995;13:1–5.
- Kotisaari K, Virtanen P, Forss N, Strbian D, Scheperjans F. Emergency computed tomography in patients with first seizure. *Seizure* 2017; 48:89–93
- Simon RP. Physiologic consequences of status epilepticus. *Epilepsia*. 1985;26(1):58-66.
- Chen JW, Wasterlain CG. Status epilepticus: pathophysiology and management in adults. *Lancet Neurol*. 2006 ;5(3):246-56.
- Urbach H . Imaging of the epilepsies . *Eur. Radiol*.2005;15 (3):494 – 500.
- Ogbole GI, Adeyomoye AO, Badu-Peprah A, Mensah Y, Nzeh DA. Survey of magnetic resonance imaging availability in West Africa. *Pan Afr Med J*.2018; 30:1–9.
- Gaillard WD, Chiron C, Helen Cross J, Simon Harvey A, Kuzniecky R, Hertz-Pannier L, et al. Guidelines for imaging infants and children with recent-onset epilepsy. *Epilepsia*. 2009; 50:2147–53.
- Wiesmann UC . Clinical application of neuroimaging in epilepsy . *J. Neurol. Neurosurg. Psychiatry* 2003;74 (4):466 – 470.
- Salmenpera TM, Duncan JS . Imaging in epilepsy . *J. Neurol. Neurosurg. Psychiatry* 2005; 76 (3): 2 – 10.
- Wang ZI, Alexopoulos AV, Jones SE, Jaisani Z, Najm IM, Prayson RA . The pathology of magnetic-resonance-imaging-negative epilepsy . *Mod. Pathol*.2013; 26 (8):1051 – 58.
- Bien CG, Szinay M, Wagner J, Clusmann H, Becker AJ, Urbach H . Characteristics and surgical outcomes of patients with refractory magnetic resonance imaging-negative epilepsies . *Arch. Neurol*. 2009;66 (12):1491 –99 .
- Degnan JA, Samtani R, Paudel K, Levy LM. Neuroimaging of epilepsy: a review of MRI findings in uncommon etiologies and atypical presentations of seizures. *Future Neurology*. 2014; 9:431-48.
- Mellerio C, Labeyrie MA, Chassoux F et al. 3T MRI improves the detection of trans mantle sign in type 2 focal cortical dysplasia . *Epilepsia* 2014; 55 (1):117 – 122.
- Zijlmans M, De Kort GA, Witkamp TD et al. 3T versus 1.5T phased-array MRI in the pre surgical work-up of patients with partial epilepsy of uncertain focus . *J. Magn. Reson. Imaging*. 2009; 30 (2): 256 – 62.
- khandediya OB, Mani SS, Kapoor P, Singh VA. Spectrum of MRI Findings in Paediatric Epilepsy-Medical and Surgical Causes of Epilepsy in children and its' Radiological Correlation ASEAN Journal of Psychiatry. 2021;22:1-6
- Harden CL, Huff JS, Schwartz TH. Reassessment: neuroimaging in the emergency patient presenting with seizure (an evidence-based review) *Neurology*. 2007;69:1772–81.
- Tranvinh E, Lanzman B, Provenzale J, Wintermark M .Imaging Evaluation of the Adult Presenting With New-Onset Seizure. *Am J Roentgenol*. 2019; 212:15-25.
- Ogbole GI, Adeyomoye AO, Badu-Peprah A, Mensah Y, Nzeh DA. Survey of magnetic resonance imaging availability in West Africa. *Pan Afr Med J*. 2018;30:1–9.
- Olszewska DA, Costello DJ. Assessment of the usefulness of magnetic resonance brain imaging in patients presenting with acute seizures. *Ir J Med Sci* 2014; 183:621–624
- Arabi M,Dirani M,Hourani RNasreddine W,Wazne J,Atweh S et al.Frequency and Stratification of epileptogenic lesions in elderly with new onset seizures.*Front.Neurol*.2018;9:995
- Hakami T, McIntosh A, Todaro M, et al. MRI identified pathology in adults with new-onset seizures. *Neurology* 2013; 81:920–927.
- Ni G, Lin W, Cai X, Qin J, Feng L, Zhu S et al. Associations between seizures and MRI in patients with anti-NMDAR encephalitis. *Acta Neurol Scand*. 2020 Nov;142(5):460-465.