

## ORIGINAL ARTICLE

**Topical Vs Pribulbar Anesthesia in Patients Undergoing 23 Guage ,Three Ports Removal of Silicone Oil**MUHAMMAD HAMZA SHAHID<sup>1</sup>, FAISAL RASHID<sup>2</sup>, SABA TAUQEER<sup>3</sup>, RABAB ALI<sup>4</sup>, MUHAMMAD TALHA FAROOQ<sup>5</sup>, NOUMAN ALEEM<sup>6</sup><sup>1</sup>FCPS Senior Registrar, Services Hospital Lahore<sup>2</sup>M.phil Optometrist, SIMS / Services Hospital Lahore<sup>3</sup>MBBS Post graduate trainee Department of Ophthalmology Services Hospital Lahore<sup>4</sup>MBBS Post graduate resident, Services Hospital Lahore<sup>5,6</sup>MBBS Post graduate resident, SIMS / Services Hospital LahoreCorresponding author: Muhammad Hamza Shahid, Email: [drhamzashahid101@gmail.com](mailto:drhamzashahid101@gmail.com), Cell: +92 334 410 1332**ABSTRACT****Objective:** To compare safety as well as efficacy of topical anesthesia against peribulbar anesthesia for patients undergoing three ports pars plana removal of silicone oil .**Background:** Silicone oil is used as a temporizing agent for vitreoretinal procedures and have to be removed according to the duration of temporand required as it is associated with complications like development and acceleration of cataract development , secondary open angle glaucoma and corneal decompensation. It can be removed via three port 23 gauge ROSO procedure both under topical and peribulbar anesthesia.**Patients & Methods:** 40 eyes from 40 patients who underwent three port ROSO with a 23 gauge port system were randomised into two groups of 20 patients each for this study. In group A eyes was operated under topical anesthesia using soaked cotton wisk with 0.5 % proparacaine hydrochloride , placed for five minutes in superior and inferior fornix before the start of surgery and the group B was operated under peri bulbar block with 4 ml of bupivacaine given five minutes before the start of surgical procedure. Pain scoring charts were used by patients to rate their pain after the procedure.**Results:** The patients in this study had a mean age of 58.46 ±3.62 years, with a range of 30-65 years. 40 individuals were treated, with 26 being male and 14 being female. The mean pain score for patients in topical anesthesia group was 3.8+- 0.5 and the mean pain score in peribulbar block group was 2.2+-0.2 with a p value of 0.01.**Conclusion:** Peribulbar block is superior to topical anesthesia in patient comfort for patients undergoing three port ROSO procedures.**Keywords:** ROSO, Silicone oil, peribulbar, Topical anesthesia, Bupicaine, Proparacaine hydrochloride.**INTRODUCTION**

Anesthesia is a main prerequisite for ocular surgery and in case of vitreo retinal procedures we have a range of choices to select our preferred route of anesthesia, these include peribulbar anesthesia, sub tenon anesthesia , topical anesthesia and lastly general anesthesia .<sup>1</sup>Each one of these routes of ocular anesthesia have its own pros and cons but the most commonly used ones for vitreo retinal surgeries including the three ports 23 gauge pars plana removal of silicone oil are peribulbar and topical anesthesia.<sup>2,3,7</sup>The advantages of topical anesthesia over peribulbar anesthesia are many including early visual rehabilitation, no use of a needle as is used for a peribulbar block and less chance of needle related complications including retrolbulbar hemorrhage and accidental injury to orbital structures.<sup>4</sup>

Apart from vitreo retinal procedures , topical anesthesia is also used in routine phacoemulsification procedures and ocular surgeries like trabeculectomy and pterygium excision .<sup>5</sup>Conventional 20-guage, 23-guage, and 25-guage sutureless pars plana vitrectomies have been performed under topical anesthesia in view of their early visual rehabilitation and good analgesic effect for the procedure. Mahajan et al have studied the effect of topical versus peribulbar anesthesia for patients undergoing pars plana vitrectomy for vitreous hemorrhage and found that the pain score between the two groups was almost similar with the only difference that in topical anesthesia group the maximum pain during the procedure is felt at the time of trocar insertion whereas in the peribulbar block it is felt at the time of local anesthesia being given but the topical anesthesia does not cause lie edema and conjunctival chemosis that is seen in routine patients with peribulbar anesthesia.<sup>7,8,6</sup>

The rationale of our study was to determine the safety and efficacy in term of analgesia provided by both topical and peribulbar techniques for the procedure of three ports 23 gauge pars plana removal of silicone oil using visual analogue scale on patient pain perception and to draw conclusion about the safety of both procedures , no such study has been done before in our population .By application of these methods in vitreo retinal procedures like 3 port 23 gauge ROSO we can determine a safe

and efficient route of anesthesia for these patients that can both save time and is less expensive.<sup>11,23</sup>

**MATERIALS AND METHODS**

Our hospital IRB committee gave its clearance to this investigation, and a six-month study period began after that. In Ophthalmology Department, Eye Unit 1 at Services hospital Lahore (SIMS) this study was conducted from April 2021 to September 2021. Forty eyes of forty three patients were carefully chosen having the past of 23 gauge pars plana vitrectomy at least three months back and were now planned for three ports 23 gauge pars plana removal of silicone oil. This study comprised male & female subjects between the ages of 30 and 65. The study excluded participants with uncontrolled hypertension a history of stroke or myocardial infarction, ischemic heart disease, trauma, a history of pars plana vitrectomy, systemic coagulation abnormalities, intraocular foreign bodies and other systemic disorders.

In this study, 40 eyes from 40 patients who had three port ROSO with a 23 gauge port system were randomized at random into two groups of 20 patients each. Group A was operated under topical anesthesia using soaked cotton Wisk with 0.5 % proparacaine hydrochloride , placed for five minutes in superior and inferior fornix before the start of surgery and the group B was operated under peri bulbar block with 4 ml of bupivacaine given five minutes before the start of surgical procedure. Pain scoring charts were used by patients to rate their pain after the procedure. Patients planned for 23 gauge three port removal of silicone oil were explained before the procedure.

All surgeries were done by a single surgeon under standard settings using 23 gauge three ports pars plana approach. An irrigation cannula was attached in inferotemporal location and two ports were made at superonasal and superotemporal quadrants. By using manual suction syringe removal of silicone oil was done along with free flow of irrigation cannula to replace the vitreous cavity volume and sustained pressure of suction was applied to minimize the fluctuation in the vitreous cavity so that the risk of complications can be reduced to minimum , along with the suction syringe a rubber tubing ring was also used at the tip of suction syringe to cover the cannula so that a closed suction system could

generate appropriate negative pressure and could provide a sustained outflow of silicone oil. At the end of procedure the three ports were removed and self sealing suture less incisions were sealed only with pressure from a cotton tip applicator. After the procedure in the recovery room all patients were provided with and explained about visual analogue pain score scale (VAPS).

During this study we collected data by post operative post operative visual analogue pain score on day one , day three and day seven. Grading of the pain perception was done according to the visual analogue pain score scale(VAPS). Data collection was done on a designed Performa.

Statistical analysis of the data gathered during this study was done by using SPSS version 21.0. Qualitative variables like gender and post operative pain score were analyzed as frequencies and percentages whereas mean and standard deviation were calculated for pain score and ages of the patients participating in this study.

## RESULTS

Fourty patients were part of this study and all the patients went under 23 gauge three port pars plana removal of silicone oil surgery. Out of 40 patients, 28(70%) were males and15 (30%) were females. Fig 1. The mean pain score for patients in topical anesthesia group was 3.8+ 0.5 and the mean pain score in peribulbar block group was 2.2+0.2 with a p value of 0.01

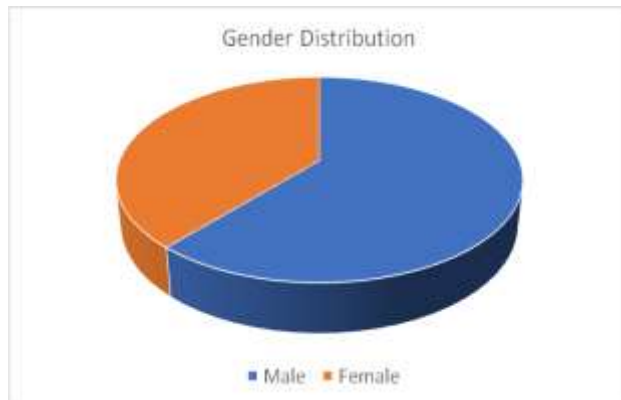


Figure 1: Gender distribution of the participants

The patients in our study had a mean age of 58.46  $\pm$ 3.62 years (range 30-65 years). Silicone oil temponade lasted an average of 6.25 1.52 months in patients (range 5-11 months). There was no pain or discomfort in 62.20 percent (28) of the patients (Pain analogue scale of less than 2), mild discomfort in 20 percent (9) of the patients (Pain analogue scale of 2 to 3), and considerable discomfort in 13.33 percent (6) of the patients (pain analogue scale of more than 3) Table 1.

Table 1: Intra operative hemorrhage

None	Mild	Severe
62.20%	20.0%	13.33%

## DISCUSSION

Recent studies have shown a lot of promise for the use of topical as well as peribulbar anesthesia before 23 gauge three port pars plana vitrectomy in patients having advance diabetic eye disease. There are various varieties of topical anesthesia which include anesthetic drops, gels as well as sponges to be placed in the conjunctival cul de sac ; that are instilled into the conjunctival sac and to prevent its drainage by naso lacrimal duct , gentle pressure is applied at lacrimal sac on medial canthus of the eye .<sup>9</sup> Recent studies have shown that local anesthetics that include lignocaine , amethocaine and bupivacaine are effective in providing topical and local anesthesia for intraocular surgery and Instillation of these local anesthesia decreases intraocular pressure (IOP)

transiently .<sup>12,8,5,13</sup> As the duration of anesthesia and analgesia is very brief by these drugs , it requires repeat instillation of drops in the conjunctival sac after every 30 minutes but long-term use of these topical drugs is associated with ocular surface toxicity as they contain preservatives like benzalkonium chloride

Most of the patients were in their fifth and sixth decade of life when they underwent 23 gauge three port pars removal of silicone oil. The peribulbar technique for local anesthesia is a type of block that has been introduced and developed as ocular and periorcular anesthetic technique for surgical procedures recently.<sup>7,8,4</sup>

The needle for peribulbar block is entered directly and is much shorter in length as compared to the previous technique of retro bulbar block as the later is associated with risk of complications like perforation of the globe and damage to optic nerve. The use of 26G ,25 mm needle for peribulbar block is much safer and this modified technique is the use of 23G needle that is associated with effective block and less rate of complications.<sup>20,19</sup>

Scared conjunctiva or tissue adhesions in the fornix , as a result of previous retinal procedures either sclera buckling or pars plana vitrectomy , were not enrolled for the study as it may require difficult conjunctival manipulation with the needle which may result in bias and for this reason, were excluded from the study. Topical anesthesia along with additional intravenous midazolam and fentanyl citrate for sedation have been used by Yopez et al. for scleral buckling procedures.<sup>22,6,10</sup>

Complete akinesia of the extra ocular muscles is absolutely mandatory for retinal surgery to proceed which is not possible to achieve by topical anesthesia , so the eye does not remain stationary and surgical manipulation per operatively under topical anesthesia is to be learned with experience . Unexpected extra ocular motility per operatively may result in various iatrogenic surgical complications like iatrogenic retinal holes and new retinal breaks formation in the retina, pre-retinal hemorrhage by iatrogenic injury to retinal vessels or accidental retinal incarceration while using hard tip flute as well as 23 gauge vitrectomy cutter or endo illumination light probe and laser probe.<sup>23</sup>

## CONCLUSION

In conclusion of our discussion, patients undergoing 23 gauge pars plana removal of silicone oil under topical anesthesia is as safe and effective as the peribulbar technique of local anesthesia with regards to patient's level of comfort as well as duration of surgery for 23 gauge pars plana removal of silicone oil .

## REFERENCES

- Zhou YL, Tong Y, Wang YX, Zhao PQ, Wang ZY. A prospective, randomised, double-masked comparison of local anaesthetic agents for vitrectomy. *Br J Ophthalmol*. 2017;101:1016–1021. PMID:28174153
- Jaichandran VV, Raman R, Gella L, Sharma T. Local anesthetic agents for vitreoretinal surgery: no advantage to mixing solutions. *Ophthalmology*. 2015;122:1030–1033. PMID:25582785
- Wu RH, Zhang R, Lin Z, Liang QH, Moonasar N. A comparison between topical and retrobulbar anesthesia in 27-gauge vitrectomy for vitreous floaters: a randomized controlled trial. *BMC Ophthalmol*. 2018 Jul 7;18(1):164. doi: 10.1186/s12886-018-0838-7. PMID: 29981573; PMCID: PMC6035792.
- Kumar CM, Seet E, Eke T, Irwin MG, Joshi GP. Peri-operative considerations for sedation-analgesia during cataract surgery: a narrative review. *Anaesthesia*. 2019 Dec;74(12):1601–10.
- Lam DS, Leung HY, Liu S, Radke N, Yuan Y, Lee VY. Two-port pars plana anterior and central core vitrectomy (lam floaterectomy) in combination with phacoemulsification and intraocular lens implantation under topical anesthesia for patients with cataract and significant floaters: results of the first 50 consecutive cases. *Asia Pac J Ophthalmol (Phila)*. 2017 Jan-Feb;6(1):33–6.
- Chaudhary RA, Khaqan HA, Ahmad A, Imtiaz U, Raza H, Shabbir U. Comparison of topical versus peribulbar anesthesia for 23G pars plana vitrectomy. *J Coll Physicians Surg Pak*. 2018 Jun;28(6):452–5.
- Socea SD, Abualhasan H, Magen O, Zayit-Soudry S, Blumenthal EZ, Duvdevan N, et al. Preoperative Anxiety Levels and Pain during

- Cataract Surgery. *Curr Eye Res.* 2019 Sep 18:1–6. [Epub ahead of print] pmid:31509020
8. Fan H, Qian Z, Tzekov R, Lin D, Wang H, Li W. A New Two-Step Anesthesia for 23- or 25-Gauge Vitrectomy Surgery: A Prospective, Randomized Clinical Trial. *Ophthalmic Res.* 2021;64(1):34-42. doi: 10.1159/000508510. Epub 2020 May 8. PMID: 32388512.
  9. Zhou YL, Tong Y, Wang YX, Zhao PQ, Wang ZY. A prospective, randomised, double-masked comparison of local anaesthetic agents for vitrectomy. *Br J Ophthalmol.* 2017 Aug;101(8):1016–21.
  10. Jaichandran VV, Srinivasan S, Raman S, Jagadeesh V, Raman R. A prospective comparison of the efficacy of 0.5% bupivacaine vs 0.75% ropivacaine in peribulbar anesthesia for vitreoretinal surgery. *Indian J Ophthalmol.* 2020;68:153–156. pmid:31856495
  11. Calobrisi, BL, Lebowitz P. *Int Anaesthesiol Clin* 1990; 28:83.
  12. Fujii GY, de Juan E Jr, Humayun MS. A new 25-gauge instrument for transconjunctival sutureless vitrectomy surgery. *Ophthalmology* 2002; 109:1807-12
  13. . Naif Al-Ali, Cheema RA. Randomized controlled trial to evaluate intraocular pressure following sub-Tenon's local anesthesia for cataract surgery: With and without hyaluronidase added to anesthetic solution. *Saudi J Anaesth* 2014; 8(Suppl 1):S63-6.
  14. Mete A, Saygılı O, Kimyon S, Pamukcu C, Çeri S, Güngör K, et al. Comparison of pain experience during 23-G vitreoretinal surgery under topical and retrobulbar anesthesia. *Int Ophthalmol.* 2017 Apr;37(2):349–56.
  15. Soudabeh H, Shideh M, Baharak F. Comparing the effect of topical anesthesia and retrobulbar block with intravenous sedation on hemodynamic changes and satisfaction in patients undergoing cataract surgery. *Anesthesiol Pain Med* 2014; 17: 201-5.
  16. Reichstein DA, Warren CC, Han DP, Wirostko WJ. Local Anesthesia With Blunt Sub-Tenon's Cannula Versus Sharp Retrobulbar Needle for Vitreoretinal Surgery: A Retrospective, Comparative Study. *Ophthalmic Surg Lasers Imaging Retina.* 2016;47:55–59. pmid:26731210
  17. Alexander GC, Kruszewski SP, Webster DW. Rethinking opioid prescribing to protect patient safety and public health. *JAMA* 2012; 308:1865-6.
  18. Young-Zvasara T, Winder J, Wijetilleka S, Wheeler L, Mcpherson R. Efficacy and Safety of a Novel Blunt Cannula Trans-Sub-Tenon's Retrobulbar Block for Vitreoretinal Surgery. *Middle East Afr J Ophthalmol.* 2019;26:163–167. pmid:31619905
  19. Faisal SM, Tahir MA, Cheema AM, Anjum MI. Pars plana vitrectomy in vitreous hemorrhage with or without Intravitreal Bevacizumab a comparative overview. *Pak J Med Sci.* 2018;34(1):221-225. doi:10.12669/pjms.341.12683
  20. Schipper I, Lüthi M. Diplopia after retrobulbar anesthesia in cataract surgery – a case report [in German]. *Klin Monbl Augenheilkd* 1994; 204:176-80.
  21. Hamilton RC. A discourse on the complications of retrobulbar and peribulbar blockade. *Can J Ophthalmol* 2000; 35:363-72
  22. Bahgecioglu H, Ünal M, Artunay O, Rasier R, Sarici A. Posterior vitrectomy under topical anesthesia. *Can J Ophthalmol* 2007; 42:272-7.
  23. Al-Kharashi A, Galbinur T, Mandelcorn ED, Muni RH, Nabavi M, Kertes PJ. The adjunctive use of pre-operative intravitreal bevacizumab in the setting of proliferative diabetic retinopathy. *Saudi Journal of Ophthalmology.* 2016 Oct 1;30(4):217-20.
  24. Trujillo-Sanchez GP, Gonzalez-De La Rosa A, Navarro-Partida J, Haro-Morlett L, Altamirano-Vallejo JC, Santos A. Feasibility and safety of vitrectomy under topical anesthesia in an office-based setting. *Indian J Ophthalmol.* 2018 Aug;66(8):1136–40.