

ORIGINAL ARTICLE

Predominant Lip Print Pattern Found among Female Students and Employees of Peshawar Medical College

IJAZ MEHMOOD¹, MUHAMMAD TARIQ AZEEM², RIZWAN UL HAQ³, IKRAM UL HAQ⁴, RUBINA SALMA YASMIN⁵, AHMED SUBHANI⁶

¹MBBS, M.Phil Forensic Medicine, Senior Demonstrator, Mohtrama Benazir Bhutto Shaheed Medical College, Mirpur AJK

²MBBS, M.Phil Forensic Medicine, Riphah International University, Islamabad

³Professor & HOD of Forensic Medicine and Toxicology, Jinnah Medical College, Peshawar

⁴M.Phil Scholar in Science of Dental Materials, Sardar Begum Dental College, Peshawar

⁵MCPS, M.Phil, Associate Professor of Forensic Medicine and Toxicology, Peshawar Medical College

⁶Final year MBBS Islamabad Medical and Dental College (IMDC), Islamabad

Correspondence to: Dr. Ijaz Mehmood, Email: ijazmehmood26@yahoo.com, Cell: +92 334 9654475

ABSTRACT

Objective: The objective of this study is to determine the predominant lip print pattern found among female students and employees of Peshawar medical college.

Design: It was a cross-sectional study.

Study Settings: This study was conducted at Forensic Medicine Laboratory of Peshawar Medical College from November 2021 to April 2022.

Material and Methods: A total of 107 (74 females, and 33 employees) voluntary participants both students and employees were included in the study. Lip prints were obtained from them using lipstick and cellophane tape, and studied in the presence of lip print expert. The lip print patterns were classified and frequencies determined.

Results: Overall pattern, type V (26.62%) and type III (19.58%) were the most common ones. There was no significant difference between the ethnicity.

Conclusion: It might be said that lip prints are distinctive, and that using them to identify people. The results showed that print of any two lips were not matched exactly. The patterns did not reveal any significant variability with regards to gender or ethnicity.

Keywords: Lip Prints, Classification, Pattern Types, Cheiloscropy

INTRODUCTION

When it comes to human lips, Cheiloscropy is one of the most important fields in forensic dentistry. This approach, which dates back to the 1930s, is used to identify individuals.^{1,2} Lip vermilion furrows are examined for their supposed particular pattern, to be more precise.³ Lip print patterns, ethnic diversity, and sexual dimorphism are all topics of discussion in the real world.⁴ Fingerprint, dental, and genetic analysis are scientifically accepted methods for identifying human beings. According to the authors of cheiloscropy studies, lip prints can aid in the identifying procedure by filtering down prospective victims based on sex. Cheiloscropy has a large and expanding body of research in the scientific community today. Lip prints have the "so-called" advantage that no two people will have the same pattern of furrows, which is supposedly true. Lip prints can also be seen on cigarette butts, napkins, and glasses, according to authors.^{5,6,7}

There are clear-cut furrows that run partially or entirely across the lips, but most prevalence studies are restricted to samples that do not even represent the area in which they were taken.^{8,9} There are three basic types of lip shape: horizontal, raised, and depressed. Lips thin as we become older, resulting in a less defined appearance. Plastic surgery has created techniques to replicate and generate fuller, broader lips as a result of this belief that youthful lips are rounded and full in appearance.¹⁰

Distinctive variations in grooves and pattern details can be seen in different lip prints due to variances in furrow number and location and their relationship to other furrows as well as general differences in thickness, length and difficulty of branching.¹¹ Unlike fingerprints, Tsuchihashi found that once a person's lip prints are generated, they are unlikely to alter over the course of their lifetime.^{12,13}

Consider the current gap in the utility of lip print patterns, and the urgent need to encourage evidence-based science., this study was designed this study to determine the predominant lip print pattern found among female students and employees of Peshawar medical college. The results of the present study will give an insight into the magnitude of problem and will provide local baseline statistical data for further research in this regard.

MATERIAL AND METHODS

This cross sectional study was conducted at Forensic Medicine Laboratory of Peshawar Medical College from November 2021 to April 2022. Sampling was done from students and employees of Peshawar medical college by convenient method. Our hospital's Ethics Committee has authorised this project. After obtaining their written agreement, participants were invited to participate in the study. A total of 107 (74 females, and 33 employees) voluntary participants both students and employees were included in the study. Participants were healthy young people with normal lip mucosa who had no history of lip illness. Anyone with a congenital lip abnormality (such as cleft lip), as well as those who were allergic to the lip stick or had a medical condition of any kind, were not allowed to participate in our study. The study's methodology and goals were clearly described to all participants, and they were made to feel at ease. Before applying the lip-stick, the lips were cleansed and a thin layer of dark red lip-stick was applied. Paper folded in half was placed between their lips and they were instructed to exert even pressure with their mouths. Once "unfolded," the lip was separated into four sections using a dental formula that is commonly employed. All four quadrants of the lip prints were examined by a magnifying lens and a second check was performed before the data was entered. The Suzuki and Tsuchihashi classification system was used to sort the lip prints (Fig. 1). SPSS version 20.0 was used for data entry and statistical analyses. A chi-square test was employed to determine the pattern of females' lip prints. The 5% level of significance is used to determine significance.

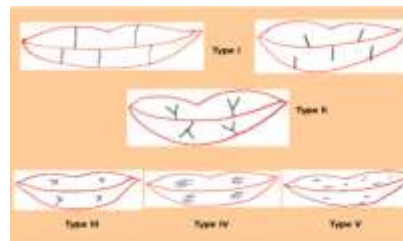


Fig. 1: Lip print classification by Suzuki and Tsuchihashi (1970) displaying patterns

RESULTS

The commonest lip print pattern in the study group was Type V (28.97%) and the least was Type I' (11.21%). The lip print showed different patterns in each subject. The lip prints did not contain simply one type of pattern rather was a combination of varying types, which made it complex and unique. No two people possessed the same lip prints.

Table 1: Demographic data of Participants of the study

Designation	No. Students	Percentage
1st year student	15	14.01%
2nd year student	12	11.21%
3rd year student	15	14.01%
4th year student	18	16.82%
Final year student	14	13.08%
Employee	33	30.84%
Total	107	100%

Table 2: Frequency and percentage of lip print among females

S&T Classification	Frequency	Percentage
Type I	16	14.95%
Type I'	12	11.21%
Type II	15	14.01%
Type III	20	18.69%
Type IV	13	12.14%
Type V	31	28.97%
Total	107(100)	100%

Table 3: Comparison of lip prints according to Ethnicity among females

Lip-print	Ethnicity	
	Pukhtoon	Other
Type I	12	4
Type I'	9	3
Type II	10	5
Type III	18	2
Type IV	10	3
Type V	25	6

DISCUSSION

A new approach to civilizational patterning is the use of human identification. It aids in categorising people into distinct categories based on their age, gender, and race. Since the Roman era, scientists have been trying to identify people based on the unique traits of their teeth and jaws.¹⁴ The use of cheiloscopy in criminal case identification is a useful auxiliary technique. In terms of morphology, lip patterns are unmatched. They are compared to fingerprints in that they are the most crucial type of evidence.¹⁵

Type V lip pattern was the most common in our population. Type III lip pattern prevalence has been observed by Narang et al. from Punjab, India.¹⁶ Although Type V lip pattern was the most common, we also found types III and IV to be present, as well as types II and I. Among the Libyan populace, Syed Wali Peeran et al. study found that Type I was the most prevalent personality type.¹⁷ In a study of Iranians, Mohfeghi et al. found that type V was the most common, followed by type I, type II, type IV, and type I' type.¹⁸ According to Vats et al., type I' was the most prevalent in Indian Brahmins, followed by types II, III, and I.¹⁹ In the Moradabad (India) population, Singh J et al. discovered that type I lip patterns were the most prevalent, followed by types III, IV, type II, and type V.²⁰

According to these findings, it appears that each population has a distinct lip shape. Different genetic upbringing could explain the discrepancy.

Among females, type II was found to be the most prevalent lip pattern, followed by type III, type I', Type V, type IV, and type I. According to Gaba et al, type II lip pattern was the most common in Mangalore females, followed by type III and type I'.²¹ Guguthu et al. also observed that type II females in Andhra Pradesh were the most numerous.²² Our findings in females are equivalent to this. However, our findings differ from those of Iranian researchers Moshfeghi et al., who found that type V lip pattern was most

common in females, followed by types I and II.¹⁸ According to another Libyan demographic survey, type I lip patterns predominate in Libyan females, followed by type II.¹⁷

CONCLUSION

It might be said that lip prints are distinctive, and that using them to identify people. The results showed that print of any two lips were not matched exactly. The patterns did not reveal any significant variability with regards to gender or ethnicity. Thus, trivializing the concept that lip prints can be used as a good indicator for gender determination.

REFERENCES

- Bansal AK, Doshi S, Bansal P, Patel R, Barai PH. Cheiloscopy: A Lip Print Study. *Indian Journal of Forensic Medicine & Toxicology*. 2019 Apr 1;13(2).
- Ahmed SA, Salem HE, Fawzy MM. Forensic dissection of lip print as an investigative tool in a mixed Egyptian population. *Alexandria Journal of Medicine*. 2018 Oct 23;54(3):235-9.
- Adamu LH, Taura MG. Lip prints: An emerging tool for personal identification. *J Biomed. Sci*. 2016;1:78-87.
- Alzapur A, Nagothu RS, Nalluri HB. Lip prints-A study of its uniqueness among students of MediCiti Medical College. *Indian journal of clinical anatomy and physiology*. 2017 Jan;4(1):68.
- Ramakrishnan P, Bahirwani S, Valambath S. Assessment of cheiloscopy in sex determination using lysochrome-A preliminary study. *Journal of forensic dental sciences*. 2015 Sep;7(3):195.
- Augustine J, Barpande SR, Tupkari JV. Cheiloscopy as an adjunct to forensic identification: A study of 600 individuals. *J Forensic Odontostomatol*. 2008 Dec 1;26(2):44-52.
- Abidullah M, Kumar MN, Bhorgonde KD, Reddy DS. Cheiloscopy and dactyloscopy: Do they dictate personality patterns?. *Journal of forensic dental sciences*. 2015 May;7(2):114.
- Basheer S, Gopinath D, Shameena PM, Sudha S, Lakshmi JD. Correlation of lip patterns, gender, and blood group in North Kerala population: A study of over 800 individuals. *Journal of Forensic Dental Sciences*. 2017 May;9(2):73.
- Bai JS, Prakash AR, Reddy AV, Rajinikanth M, Sreenath S, Reddy KV. Correlative study on lip prints, fingerprints, and mandibular intercanine distance for gender determination. *Journal of forensic dental sciences*. 2018 Sep;10(3):143.
- Wong WW, Davis DG, Camp MC, Gupta SC. Contribution of lip proportions to facial aesthetics in different ethnicities: a three-dimensional analysis. *Journal of plastic, reconstructive & aesthetic surgery*. 2010 Dec 1;63(12):2032-9.
- Navarro E, Castelló A, López-Alfaro JA, Verdú F. More about the developing of invisible lipstick-contaminated lipmarks on human skin: the usefulness of fluorescent dyes. *Journal of Forensic and Legal Medicine*. 2007 Aug 1;14(6):340-2.
- Ludwig A, Page H. An investigation into the dynamics of lip-prints as a means of identification. *Australian Journal of Forensic Sciences*. 2012 Jun 1;44(2):169-81.
- Negi A, Negi A. The connecting link! Lip prints and fingerprints. *Journal of forensic dental sciences*. 2016 Sep;8(3):177.
- Dwivedi N, Agarwal A, Kashyap B, Raj V, Chandra S. Latent lip print development and its role in suspect identification. *Journal of Forensic Dental Sciences*. 2013;5(1):22.
- Navarro E, Castelló A, López JL, Verdú F. Criminalistic: Effectiveness of lysochromes on the developing of invisible lipstick-contaminated lipmarks on human skin: A preliminary study. *Forensic Science International*. 2006;158(1):9-13.
- Narang RS, Arora PC, Randhawa K. Cheiloscopy as an aid to forensic methodology. *Indian Journal of Comprehensive Dental Care (IJCDC)*. 2011;1(1).
- Peeran SW, Kumar PN, Abdalla KA, Azaruk FAA, Manipady S, Alsaid FM. A study of lip print patterns among adults of Sebha city, Libya. *Journal of Forensic Dental Sciences*. 2015;7(1):67.
- Moshfegh M. Morphological patterns of lip prints in an Iranian population. *Oral Medicine and Pathology*. 2016;8(5):550-5.
- Vats Y, Dhali JK, Kapoor A. Gender variation in morphological patterns of lip prints among some north Indian populations. *Journal of Forensic Dental Sciences*. 2012;4(1):19.
- Singh J, Gupta KD, Sardana V, Balappanavar AY, Malhotra G. Sex determination using cheiloscopy and mandibular canine index as a tool in forensic dentistry. *Journal of Forensic Dental Sciences*. 2012;4(2):70.
- Gaba R, Ahmed J, Ongole R, Denny C, Shenoy N, Binnal A. Scope of cheiloscopy in gender identification. *International Journal of Biomedical Research*. 2014;5(06):423-6.
- Guguthu RN, Alaparthy RK, Maloth KN, Kesidi S, Kundoor V, Palutla MM. Personal identification and sex determination using cheiloscopy. *Journal of Indian Academy of Oral Medicine and Radiology*. 2015;27(3):399.