

## CASE REPORT

# A novel two-codon deletion at codon 508 and 509 of the *rpoB* gene in pulmonary tuberculosis and HIV co-infection: A case report

LEE LIH HUEY<sup>1</sup>, CHUA WEI CHUAN<sup>1,3</sup>, ZETI NORFIDIYATI SALMUNA AYUB<sup>1,3</sup>, NORAZMI MOHD NOR<sup>2</sup>, ALWI MUHD BESARI<sup>3,4</sup> AND CHAN, YEAN YEAN<sup>1</sup>

<sup>1</sup>Department of Medical Microbiology and Parasitology, School of Medical Sciences, Universiti Sains Malaysia Health Campus, 16150 Kubang Kerian, Kelantan, Malaysia.

<sup>2</sup>School of Health Sciences, Universiti Sains Malaysia Health Campus, 16150 Kubang Kerian, Kelantan, Malaysia.

<sup>3</sup>Hospital USM, Health Campus, USM, 16150, Kubang Kerian, Kelantan, Malaysia

<sup>4</sup>Department of Medicine, School of Medical Sciences, Universiti Sains Malaysia, Health Campus, Kubang Kerian 16150, Kelantan, Malaysia.

Correspondence to Prof. Dr. Chan Yean Yean, E-mail: [yychan@usm.my](mailto:yychan@usm.my)

## SUMMARY

We report a case of pulmonary *Mycobacterium tuberculosis* infection with a resistance to rifampicin (RIF) in a 39-year-old man who was co-infected with Human Immunodeficiency Virus (HIV) and hepatitis C. Phenotypic and genotypic test were performed to diagnose the patient. Sequencing analysis revealed novel two-codon deletion at codon 508 and 509 of the *rpoB* gene in *M. tuberculosis*.

**Keywords:** Co-infection, *Mycobacterium tuberculosis*, *rpoB* gene, rifampicin-resistant.

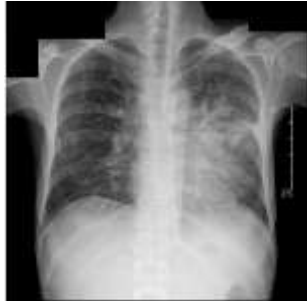## INTRODUCTION

Pulmonary tuberculosis (PTB) in patients with HIV has a higher risk of relapse and treatment failure due to anti-TB resistance compared to general population. Furthermore, it has been shown that a relapsing tuberculosis in HIV patients is highly related to drug resistance as compared to a new acquisition of *Mycobacterium tuberculosis* (MTB) from the public.<sup>1</sup> Resistance to one of the first line drugs, RIF, occurs most commonly by substitution mutation in the RIF-resistance determining region (RRDR), core region of *rpoB* gene, though few study reported deletion and insertion within this region<sup>2,3</sup>. Here, we report a case of pulmonary MTB infection with a resistance to RIF in a 39-year-old man who was co-infected with HIV and hepatitis C.

## CASE REPORT

A 39-year-old man, with a history of intravenous drug use, has been diagnosed with HIV and hepatitis C virus co-infection 2 years before presenting with smear positive PTB. Sputum MTB Culture revealed *Mycobacterium tuberculosis* fully susceptible to all anti-TB drugs. The PTB has been treated but the anti-retroviral therapy (ART) and direct-acting antiviral (DAA) for Hepatitis C has not been started due to commitment issues. He achieved smear conversion after two months on standard anti-tuberculosis regime consisting of Ethambutol (EMB), Isoniazid (INH), Rifampicin (RIF) and Pyrazinamide (PZA) with directly-observed short course treatment. Upon completion of the 6-months regime, repeated sputum smear was negative.

Fig. 1: Chest X- ray AP supine view, which shows bilateral hilar lymphadenopathy and consolidation of the left lower lobe.



He presented again 3 years later with symptoms of chronic productive cough for 3 months. Ziehl–Neelsen smear was found to

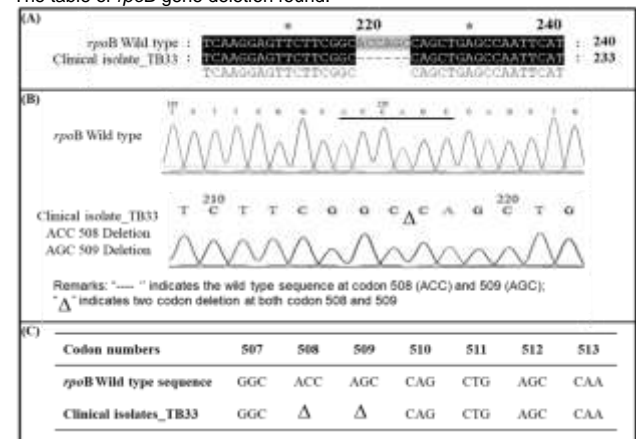
Received on 01-02-2022

Accepted on 29-07-2022

be persistently positive with 2 consecutive samples. Chest X-ray revealed collapse-consolidation of the left middle and lower lobe with bilateral hilar lymphadenopathy (Fig. 1). He was empirically restarted with abovementioned first-line regime for relapsed pulmonary tuberculosis for 2 months and continued with RIF and INH for 4-months maintenance therapy. Culture and antimicrobial susceptibility testing were requested.

While on maintenance anti-TB therapy for 2 months, he developed spontaneous bacterial peritonitis due to chronic hepatitis C infection with portal hypertension and was admitted for parenteral ceftriaxone and paracentesis. He was also noted to be pancytopenic due to hypersplenism. RIF was withheld in view of severe thrombocytopenia. *Mycobacteria* susceptibility testing result revealed RIF- resistance. The genomic DNA from the isolate was extracted using NucleoSpin® Tissue (Macherey-Nagel, Germany) and subjected for polymerase chain reaction. The amplicon size of 688 base pairs was sent for Sanger sequencing (Integrated DNA Technologies (IDT® DNA, USA). Subsequently, the sequencing result revealed a two-codon deletion at codon 508 and 509 (Figure 2), which fall within the RRDR. The nucleotide sequence of this isolate was deposited at GenBank with accession number: MK450522 (<https://www.ncbi.nlm.nih.gov/nuccore/MK450522>).

Fig. 2 (A): The graphical presentation of the sequencing analysis showed two-codon deletion in *rpoB* gene. (B) The chromatograms from sequencing analysis presented a novel two- codon deletion at codon 508 and 509. (C) The table of *rpoB* gene deletion found.



The anti-TB regime was then switched to INH, EMB and Ofloxacin (OFX), which was less myelosuppressive. He was then discharged and planned for a follow-up assessment one week later

to review his blood counts and liver function test. However, four days later his profound immunosuppression led to a fatal *Pseudomonas septicaemia* with periorbital cellulitis. Both blood culture and pus discharge from right eye grew *Pseudomonas aeruginosa*. He eventually succumbed to disseminated *Pseudomonas* sepsis.

## DISCUSSION

HIV-infected patients are at a higher risk of being infected with drug-resistant MTB, including RIF and INH monoresistance and multi-drug resistance<sup>4</sup>. The first line anti-TB drugs are more commonly fails to treat TB in HIV patient may due to several reasons for instances relapse case, re-infection, emergence of multidrug-resistant tuberculosis or environmental factors. One study reported that there was greater chance of MTB to persist in successfully treated HIV-patient in comparison to non-HIV patient due to the state of immune deficiency in patients with HIV<sup>5</sup>. Therefore, administration and choice of drug is a major concern in minimizing possible infection and hepatotoxicity of the patient.

The worldwide burden of HIV-infected patient in TB cases differs markedly over various geographical region from 14% in Europe to 46% in Southeast Asia. Approximately 29% of population death of TB is interlinked with infection of HIV. In Malaysia, there were about 1800 cases of HIV patients with tuberculosis (Tuberculosis country profiles, <http://www.who.int/tb/country/data/profiles/en/>; 2017)<sup>6</sup>. The mechanisms of resistance to first-line drug were well studied however the second-line drugs were less well understood.<sup>7</sup>

RIF-resistance is closely related to mutations in the RRDR of the *rpoB* gene starting from codon 507 to codon 533. Predominantly, the occurrence of substitution mutation in RRDR was 16.0%, while deletion and insertion were 3.2% and silent mutations were 1.3%.<sup>8</sup> Double deletion in amino acids is expected to cause more drastic changes to the protein structure leading to lower affinity to RIF.

This isolate revealed a two-codon deletion at codon 508 and 509, located within the RRDR region, presumably causing a moderate (20 to 100µg/ml) to high (≥100µg/ml) level of resistance. The gold standard which is the culture method is used to confirm the genotypic result as proposed by World Health Organization.

Many studies have similarly reported a two-codon deletion in *rpoB* gene of MTB. In year 1997, one of the Korea isolates showed the similar result<sup>2</sup>. Makinen and his colleague reported Russia isolate own to Beijing strains contain this deletion mutation.<sup>9</sup> Another study conducted in China discovered this deletion in one of the RIF-resistant isolates.<sup>3</sup> In contrast, one of the studies revealed that the same codons deletion was found in one of the RIF-susceptible isolates.<sup>10</sup> In Malaysia, prior to this case-study, these two-codon deletion at codon 508 and 509 have not been reported. More cases are required to be characterized for better understanding on the molecular mechanism and implication to clinical manifestations. It is possible that the MTB infection represent a relapsed case with the same isolate which acquired the said deletions while on treatment, or infected with another resistant strain after an apparent cure.

## CONCLUSION

In conclusion, the deletion mutation in this MTB isolate might be one of the factors that contribute to the relapse of pulmonary tuberculosis and anti-TB treatment failure in this patient, other than the compromised state of immune system from the co-infection of HIV.

**Acknowledgments:** We express our gratitude to the Director of the Hospital Universiti Sains Malaysia (USM), Kubang Kerian, Kelantan for granting the permission for investigators to use patients' medical record, space and assets belong to the hospital during the process of conducting the research. Special thanks go to Mohd Ali Abdullah, Nor Suhana Mohd Satar, staff from department of microbiology and parasitology and hospital who have relentlessly assisted in this research.

**Availability of data:** Detailed patient information could be available after a reasonable request to the corresponding author.

**Conflict of interest:** The authors declare that there is no conflict of interest.

**Ethical approval:** Our institution does not require ethical approval for reporting individual cases or case series.

**Authors Contribution:** LLH, CWC, ZNSA, and CYY conceived, designed the study and did writing & editing of manuscript LLH, NMN, and AMB did data collection and manuscript writing CYY did review and final approval of manuscript

### Grant Support & Financial Disclosures

This work was financially supported by LRGS Grant (203/PPSK/67212001) from Ministry of Education Malaysia.

## REFERENCES

- Zong, Z.; Huo, F.; Shi, J.; Jing, W.; Ma, Y.; Liang, Q.; Jiang, G.; Dai, G.; Huang, H.; Pang, Y. *Frontiers in microbiology* **2018**, *9*, 1858.
- Kim, B.-J.; Kim, S.-Y.; Park, B.-H.; Lyu, M.-A.; Park, I.-K.; Bai, G.-H.; Kim, S.-J.; Cha, C.-Y.; Kook, Y.-H. *Journal of clinical microbiology* **1997**, *35*, (2), 492-494.
- Wang, S.; Zhao, B.; Song, Y.; Zhou, Y.; Pang, Y.; Ou, X.; Li, Q.; Xia, H.; Zhao, Y. **2013**.
- Bruchfeld, J.; Correia-Neves, M.; Källénus, G. *Cold Spring Harbor perspectives in medicine* **2015**, *5*, (7), a017871.
- Moreno, S.; Jarrin, I.; Iribarren, J.; Perez-Elias, M.; Viciano, P.; Parra, J.; Gomez-Sirvent, J.; Lopez-Aldeguer, J.; Gutierrez, F.; Blanco, J. *The International journal of tuberculosis and lung disease* **2008**, *12*, (12), 1393-1400.
- Campbell, P. J.; Morlock, G. P.; Sikes, R. D.; Dalton, T. L.; Metchock, B.; Starks, A. M.; Hooks, D. P.; Cowan, L. S.; Plikaytis, B. B.; Posey, J. E. *Antimicrobial agents and chemotherapy* **2011**, *55*, (5), 2032-2041.
- Miotto, P.; Cabibbe, A. M.; Borroni, E.; Degano, M.; Cirillo, D. M. *Journal of clinical microbiology* **2018**, *56*, (5), e01599-17.
- Mäkinen, J.; Marjamäki, M.; Haanperä-Heikkinen, M.; Marttila, H.; Endourova, L. B.; Presnova, S. E.; Mathys, V.; Bifani, P.; Ruohonen, R.; Viljanen, M. K. *European journal of clinical microbiology & infectious diseases* **2011**, *30*, (9), 1119-1126.
- Berrada, Z. L.; Lin, S.-Y. G.; Rodwell, T. C.; Nguyen, D.; Schecter, G. F.; Pham, L.; Janda, J. M.; Elmaraachli, W.; Catanzaro, A.; Desmond, E. *Diagnostic microbiology and infectious disease* **2016**, *85*, (2), 177-181.