

First Occurrence of Eudiplozoon Kamegaii Nishira & Urabe, 2020 (Monogenea: Diplozoidae) in Iraq from Gills of Common Carp *Cyprinus Carpio*

MOHAMMED SALIH ABOUD¹, KEFAH NASER ABDUL-AMEER²

^{1,2}Department of Biology, College of Education for Pure Science, University of Baghdad, Baghdad, Iraq.

Correspondence to: Kefah Naser Abdul-Ameer, Email: kefahnaser59@yahoo.com

ABSTRACT

In this study, the monogenean Eudiplozoon kamegaii Nishihira & Urabe, 2020 which is the second species of the genus Eudiplozoon Khotenovsky, 1985 described in the world, was recorded for the first time in Iraq from the gills of the common carp *Cyprinus carpio* Linnaeus, 1758 which were collected from the Tigris river in the Al-Rashidiya region north of Baghdad province from August 2021 until May 2022. The description and measurements of this parasite, as well as its illustrations, were given.

Keywords: Eudiplozoon kamegaii, *Cyprinus carpio*, Monogenea, Tigris river, Iraq.

INTRODUCTION

Diplozoidae which are blood-feeding ectoparasites of freshwater cyprinid and characid fishes, are characterized by extraordinary body architecture and a unique sexual behavior^{1,2}. Like all monogeneans, species in this family have a direct life cycle, their free-swimming larva hatches from eggs are called oncomiracidium, invades a fish host and settles on the gills, and metamorphoses into a post-oncomiracidial larval stage, which is called dipopra³. When two dipoprae permanently fuse to form one individual in the so-called permanent copula stage, which then develops into an adult individual⁴. They occur on the primary lamellae gills of their fish hosts, where they feed on blood and tissue and cause mechanical damage to the gill filaments, which often results in secondary infections (bacterial, mycotic) and anemia^{5,6}. According to the shape of the posterior portion of the body, five genera are recognized in the family Diplozoidae namely: Diplozoon, Eudiplozoon, Inustiatius, Paradiplazoon, and Sindiplazoon⁷. Species of Eudiplozoon are distinguished from the other genus by the presence of dilation with large folds in the hind body of the parasite⁸.

In Iraq, diplozoid fauna includes 22 species: 20 species of Paradiplazoon and one species for both Diplozoon and Eudiplozoon⁸.

The present study presents the first record of Eudiplozoon kamegaii Nishihira and Urabe, 2020 from gills of *Cyprinus carpio* from Al-Rashidia location on in the Tigris river in Baghdad city.

MATERIAL AND METHODS

During the period from August 2021 until May 2022, surveys on the parasite fauna of fishes were performed in the Tigris river in the Al-Rashidiya region north of Baghdad province. Thirty-one specimens of common carp *Cyprinus carpio* Linnaeus, 1758, were caught weekly and inspected for parasites. The fishes were transported alive to the laboratory and were identified according to an account of freshwater fishes in Iraq⁹. At first, external organs (gills, fins and skin) of fishes were freshly examined under a dissecting microscope for ectoparasites. Skin and gill smears were microscopically examined. Care was taken to isolate and remove Eudiplozoon specimens and then was stained with aqueous neutral red. Permanent smears were prepared with glycerin. For fixation and preservation, some parasite specimens were put in 70% ethanol. Drawings of the body and the attachment clamps and the central hook of the haptor were done by using a Camera Lucida. Parasite identification was performed according to Nishihira & Urabe¹⁰. All measurements used in the parasite's description were made with a slide micrometer (in mm) as minimum-maximum (mean). All recordings of diplozoid fauna in fishes of Iraq were reviewed with the index catalogue of parasites and disease agents of the fishes of Iraq¹¹.

RESULTS AND DISCUSSION

Eudiplozoon kamegaii Nishihira and Urabe, 2020: Five out of

thirty-one specimens of common carp *Cyprinus carpio* Linnaeus, 1758 were infected with this parasite, which was found on the gills of the infected fishes with a prevalence of 16.1% and a mean intensity of 2. The following is the description and measurements (in mm, based on five specimens) of this parasite.

The body of paired worms forming "X"-shaped organisms comprises a forebody filled with vitelline follicles and a hindbody with a haptor, including four pairs of clamps and one pair of central hooks for host attachment (Fig. 1A, 2B).

Body length 6.96-7.32 (7.14). Length of the forebody 3.61-4.2 (3.90), length of posterior part a hindbody 2.24-2.86 (2.55). On the forebody of the body, the mouth leads to the buccal cavity, two elliptical oral suckers with length 0.164-0.178 (0.171), width of 0.124-0.137 (0.130), anterior to suckers, subterminal circular musculo-glandular organs are characteristic of the genus, with lengths of 0.058-0.063 (0.060) and widths of 0.053-0.057 (0.055) (Fig. 1A, 2B).

A hindbody comprises of four sections with 24-25 folds. The first sections of quarters contain one ovary, 0.542-0.584 (0.563) long and 0.316-0.318 (0.317) wide, and one testis posted to the ovary with 0.432-0.446 (0.439) long and 0.159 wide. The egg with a filament attached surface is 0.151-0.162 (0.156) long (Fig. 2B). The third section of quarters dilating with 4-5 thick folds (Fig. 2C). The haptors occupying the posterior quarters of the hindbody are provided with four pairs of clamps and one pair of central hooks for host attachment (Fig. 2C). Intestine in hind body with weak lateral diverticula, ending blindly anterior to clamps (Fig. 1A)

Clamps with a small projection at the anterior end of median sclerite, followed by a V-shaped sclerite, connecting with anterior clamp jaws (Fig. 1B, 2E). Thin projection, a ligament-like structure rather than a sclerite, at the posterior end of median sclerite connecting with posterior clamp jaws (Fig. 1B, 2D). Clamp I (posterior), 0.066-0.077 (0.071) X 0.122- 0.144 (0.133), clamp II, 0.085-0.091 (0.088) X 0.155-0.167 (0.161), clamp III, 0.088-0.094 (0.091) long X 0.148-0.170 (0.159), clamp IV, 0.092-0.099 (0.095) X 0.148-0.156 (0.0152) (Fig. 2C). Central hook submedian, media to clamp II, having a handle with 0.037-0.039 (0.038) long and shaft 0.022 long (Fig. 2F). The filament was attached to the egg surface, egg 0.734-0.846 (0.790) X 0.169-0.281 (0.225) (Fig. 2B).

The descriptions and measurements of the present E. kamegaii are agreed with those reported by Nishihira & Urabe¹⁰ from the gills of *Cyprinus carpio* from Lake Biwa, Kusatsu City, Shiga Prefecture, Japan. According to the index-catalogue of parasites and disease agents of fishes of Iraq fishes of Iraq¹¹, the present record E. kamegaii considers the first time in Iraq, as no previous report was given for this parasite in Iraqi fishes.

According to GBIF¹² and WoRMS¹³, only two species of the genus Eudiplozoon Khotenovsky, 1985 been described throughout the world Eudiplozoon nipponicum (Goto, 1891) Khotenovsky, 1985 and the present E. kamegaii. The difference in the number of folds on the hindbody (E. nipponicum 15-16 folds), and the clamp size as key characters for the distinction between the two Eudiplozoon species¹⁰

In Iraq, *E. nipponicum* was recorded for the first time in Iraq from *C. carpio* by Al-Nasiri¹⁴ as *Diplozoon nipponicum* but then, it was reported as *E. nipponicum* by all subsequent researchers.

The present record of *E. kamegaii* is the second species of the genus *Eudiplozoon* so far recorded from the Iraqi fishes.

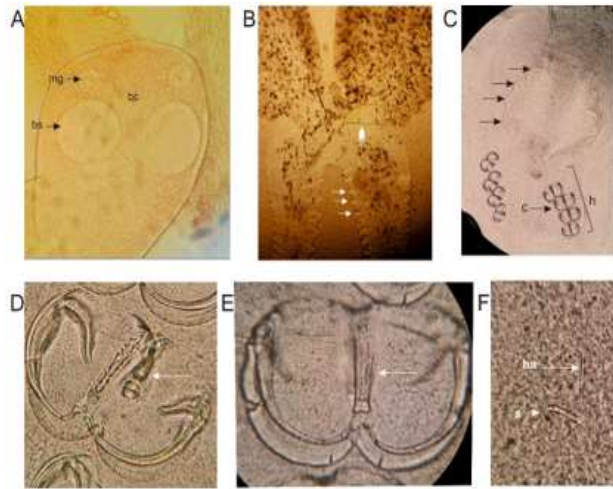


Figure 1: Diagrammatic drawing of *Eudiplozoon kamegaii*, A- The form an X-shaped body (Scale bar = 2.5 mm); B- clamp (Scale bar = 0.041 mm), C- central hooks (Scale bar = 0.019 mm), fb: forebody, ha: handle, hb: hind body, i: intestine; s: shaft of hook, vt: vitelline follicles.

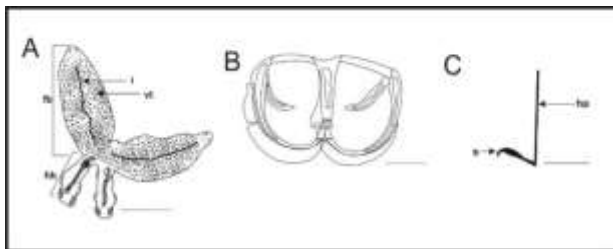


Figure 2: Photomicrograph of *Eudiplozoon kamegaii*. A-The anterior end of forebody (400x) B- The form an X-shaped body, arrows: folds, head arrow: egg (100x); C: Third quarter of hind body, arrows: thick folds (100x), D- clamp, arrows: posterior end of median with a ligament-like a sclerite connecting with posterior clamp jaws (400x), E- clamp, arrows: anterior median sclerite of clamp followed by a V-shaped sclerite connecting with anterior jaws (400x), F- central hooks (400x). bc: buccal sucker bs: buccal sucker, c: clamp, h: haptor, mg: musculo-glandular organs, ha: handle, s: shaft of hook.

Acknowledgement: Thanks to Prof. Dr. Furhan T. Mhaisen for his permission to use his index- catalogue of parasites and disease agents of fishes of Iraq to provide us with the information on the previous account records of parasites in Iraq.

REFERENCES

- Hodová I, Sonnek R, Gelnar M, Valigurová A. Architecture of Paradiplazoon homoion: A diplozoid monogenean exhibiting highly-developed equipment for ectoparasitism. *PLOS ONE*. 2018;13(2):e0192285. doi:10.1371/journal.pone.0192285
- Sicard M, Desmarais E, Lambert C. Is the Octomacridae the sister family of the Diplozoidae? *Parasite*. 2002;9(1):85-87. doi:10.1051/parasite/200209185
- Blazheković-Dimovska D, Stojanovski S. Distribution of *Eudiplozoon nipponicum* (Monogenea, Diplozoidae) in farmed common carp (*Cyprinus carpio*, L. 1758) from aquaculture facilities in Macedonia. *Biotechnology in Animal Husbandry*. 2021;37(2):127-137. doi:10.2298/BAH2102127B
- Vorel J, Cwiklinski K, Roudnický P, et al. *Eudiplozoon nipponicum* (Monogenea, Diplozoidae) and its adaptation to haematophagy as revealed by transcriptome and secretome profiling. *BMC Genomics*. 2021;22(1):274. doi:10.1186/s12864-021-07589-z
- Santos QM, Avenant-Oldewage A. Review on the molecular study of the Diplozoidae: analyses of currently available genetic data, what it tells us, and where to go from here. *Parasites & Vectors*. 2020;13(1):539. doi:10.1186/s13071-020-04417-3
- Zhang D, Zou H, Wu SG, et al. Three new Diplozoidae mitogenomes expose unusual compositional biases within the Monogenea class: implications for phylogenetic studies. *BMC Evolutionary Biology*. 2018;18(1):133. doi:10.1186/s12862-018-1249-3
- Pugachev, O.N., Gerasev, P.I., Gussev, A.V.; Ergens, R. & Khotenowsky, I. (eds.) Guide to Monogeneoidea of freshwater fish of Palaearctic and Amur regions. In: 2010.
- Mhaisen F, Naser Abdul-Ameer K. Checklists of Dactylogyrus species (Monogenea) from fishes of Iraq. *Biol. Appl. Environ. Res.*, 3(1): 1-36. Published online May 11, 2020. Accessed April 6, 2022. <http://www.marinespecies.org>
- Brian W. Coad. *Freshwater Fishes of Iraq*. Pensoft Publishers. Published online 2010.
- Nishihira T, Urabe M. Morphological and molecular studies of *Eudiplozoon nipponicum* (Goto, 1891) and *Eudiplozoon kamegaii* sp. n. (Monogenea; Diplozoidae). *Folia Parasitologica*. 2020;67. doi:10.14411/fp.2020.018
- Furhan Thumad Mhaisen. Index-Catalogue of Parasites and Disease Agents of Fishes of Iraq . (Unpublished: mhaisenft@yahoo.co.uk). 2022.
- GBIF (2022). Global Biodiversity Information Facility, on-line database, <http://www.gbif.org>. (Accessed 6 April 2022).
- WoRMS (2022). World Register of Marine Species at <http://www.marinespecies.org>. (accessed 6 April 2022).
- Al-Nasiri, FS. First occurrence of the monogenetic trematode *Diplozoon nipponicum* Goto, 1891 in Iraq from common carp *Cyprinus carpio* (Pisces). *Iraqi J. Agric. (Spec. Issue)* 2003; 8(6): 95-99