

# Compare the Efficacy and Safety of SAPB with Continuous Tea in Patients Undergoing Open Lung Resection

FAHEEM ASGHAR<sup>1</sup>, UMAR IQBAL<sup>2</sup>, MAMOONA SHAIKH<sup>3</sup>

<sup>1</sup>Assistant Professor Anesthesia and ICU, M. Islam Medical College, Gujranwala

<sup>2</sup>Associate Professor Anesthesia, Rashid Latif Medical College, Lahore

<sup>3</sup>Senior Instructor, Department of Anesthesia, Isra University Hospital, Hyderabad, Sindh

Correspondence to: Faheem Asghar, Email: [doctorfaheem@gmail.com](mailto:doctorfaheem@gmail.com), Cell: +92 3006446633

## ABSTRACT

**Objective:** Serratus anterior plane block (SAPB) combined with continuous thoracic epidural analgesia (TEA) is the primary goal of our research.

**Study Design:** Randomized Controlled Trial

**Place and Duration:** Conducted at M.Islam Medical College Gujranwala/Rashid Latif Medical College Lahore, during from June 2021 to Dec 2021.

**Methods:** There were one hundred and six patients of both genders were presented in this study. Patients were aged between 18-65 years. After obtaining written agreement, the demographics of enrolled patients were recorded, including their age, gender, and BMI. Patients were underwent for elective thoracotomy for lung cancer surgery. Patients were equally divided into two groups. A thoracic epidural catheter (10 ml levobupivacaine 0.25 percent followed by 5 ml/hour of 0.125 percent) was given to group II, and a SAPB (30 ml levobupivacaine 0.25 percent followed by 5 ml/hour of 0.125 percent) was given to group I. In order to assess pain, the researchers utilized a visual analogue scale (VAS). The post-operative results of both groups were compared to each other. The full data set was analyzed using the SPSS 24.0 edition.

**Results:** We found majority of the patients 66 (62.3%) were males and 40 (37.7%) cases were females with mean age 50.2±4.42 years. Mean body mass index of the cases were 24.7±6.33kg/m<sup>2</sup>. In both groups majority of the patients 35 (66.03%) and 36 (67.9%) had ASA class III. Mean operative time in group I was greater 132.8±8.75 minutes as compared to group II 124.3±9.55 minutes. Mean pain score in group I was lower 40.6±5.21 as compared to group II 65.3±4.31. Mean VAS time of coughing was greater in group II of 76.7±1.44 than that of group I 66.2±7.37 cm-h. Analgesic usage was significantly reduced in group I, and the incidence of nausea and vomiting was significantly reduced, with no change in the rate of hypotension between the two groups.

**Conclusion:** In this trial, we found that continuous SAPB was more effective than TEA in reducing postoperative pain in patients following open lung resection for cancer, and complications were reduced in the SAPB group.

**Keywords:** Open Lung Resection, Analgesia, SAPB, TEA, VAS

## INTRODUCTION

Patients with lung, mediastinum, or esophageal diseases may need one of three types of thoracic surgical incisions: anterior, posterolateral, or any combination of these. Approximately 30–50% of people who receive thoracotomies experience postthoracotomy discomfort. Due to altered mechanical functions of the lungs and a ventilation-perfusion mismatch that may occur after a thoracotomy, inadequate pain management may increase the risk of consequences such as lung collapse and chest infections. [3]

Thoracotomy discomfort may have several causes. Somatic and visceral afferents contribute to the nociceptive and neuropathic aspects of this phenomenon. Intercostal nerves, the vagus and phrenic nerves in the pleura, the superficial cervical plexus, and the brachial plexus in the ipsilateral shoulder are the most common causes of discomfort for patients. [4] In order to deal with the several sources of pain, a multimodal analgesic strategy is advised. A variety of analgesics, including opioids and nonopioid medicines, are used in conjunction with local anaesthetics to achieve this goal. Intercostal nerve block, thoracic epidural anaesthesia (TEA), and thoracic paravertebral blocks are all examples of these procedures (TPVB). [5] The gold standard for thoracotomy pain management is TEA. A recent analysis found that TPVB is just as effective as TEA, although the risk of mild problems is lower than with TEA. [6] Another option for thoracotomy pain management is the serratus anterior plane block (SAPB). Ultrasound guidance is used to provide analgesia between the thoracic 2 and 9 vertebrae. There is a considerable likelihood of developing chronic post-surgical pain (CPSP) or postoperative pulmonary problems after thoracoscopic surgery because of the commonality and severity of the acute pain experienced immediately after surgery. [7,8]

In the clinic, patient-controlled intravenous analgesia (PCIA) is often used to provide postoperative analgesia, which mostly depends on intravenous opioid administration. Pain alleviation and

adverse effects (such as respiratory depression, nausea/vomiting, and itching) associated with PCIA have been linked to higher analgesia and dissatisfaction, particularly in thoracic surgery according to some study. [9] Analgesics, such as opioids and NSAIDs, may be used to treat acute post-thoracotomy discomfort, as well as local anaesthetic blocking.

The use of continuous peripheral regional analgesic treatments rather than single-injection procedures is highly recommended by the American Pain Society for postoperative pain management since it may provide longer sustained analgesia. Regional anaesthesia for thoracic surgery began with epidural anaesthesia (TEA) and paravertebral blocks. [11]

Postoperative pain management should not be entrusted to TEA due to the risks it entails and the challenges it presents. There is a risk of bleeding in a free region with anticoagulants or antiplatelet drugs, hence PVB is not recommended for patients. For long-term pain relief, it is difficult to insert and secure the catheter in the PVB, as well. Regional analgesia may be achieved by blocking the lateral cutaneous branches of the intercostal nerves using a simple operation known as the serratus anterior plane block (SAPB). [13] The continuous SAPB (cSAPB) is a peripheral nerve blocker that has recently come into the focus. [14,15] While using cSAPB in our practise, we found that previous research results seemed to be at odds with our own.

The purpose of this study was to compare the effects of SAPB and TEA during open lung resection up to the first and second 24-hour period on statistically assessed pain levels during cough and rest in order to assess the efficacy and limits of SAPB.

## MATERIAL AND METHODS

This Parallel Controlled/Randomized study was conducted at Conducted at M.Islam Medical College Gujranwala/Rashid Latif Medical College Lahore, during from June 2021 to Dec 2021 and comprised of 106 patients. After obtaining written agreement, the demographics of enrolled patients were recorded, including their

age, gender, and BMI. Patients had history of lung surgery, had severe medical illness and those did not give any written consent were not included in this study.

The American Society of Anesthesiologists Class I, II, and III certifications were used. Age of the patients was between 18-65 years. Patients were equally divided into two groups. A thoracic epidural catheter (10 ml levobupivacaine 0.25 percent followed by 5 ml/hour of 0.125 percent) was given to group II, and a SAPB (30 ml levobupivacaine 0.25 percent followed by 5 ml/hour of 0.125 percent) was given to group I. In order to assess pain, the researchers utilized a visual analogue scale (VAS). The post-operative results of both groups were compared to each other. The full data set was analyzed using the SPSS 24.0 edition.

## RESULTS

We found majority of the patients 66 (62.3%) were males and 40 (37.7%) cases were females. (fig 1)

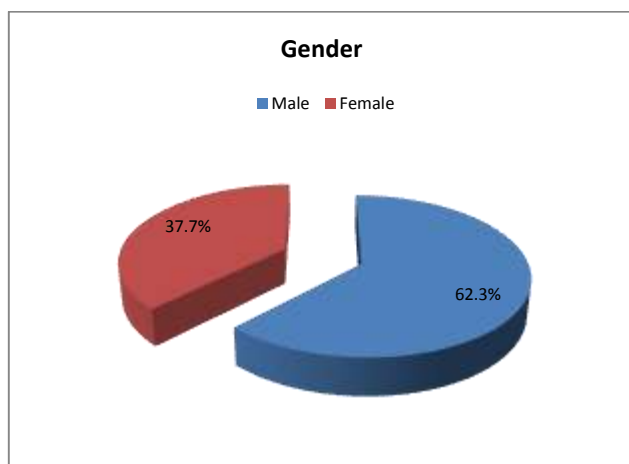


Figure 1: Gender distribution among enrolled cases

The mean age in group I was  $50.1 \pm 3.14$  years with mean body mass index was  $24.7 \pm 6.33$  kg/m<sup>2</sup> and in group II mean age was  $49.1 \pm 3.14$  years with mean body mass index was  $23.7 \pm 6.33$  kg/m<sup>2</sup>. In both groups majority of the patients 35 (66.03%) and 36 (67.9%) had ASA class III. Mean operative time in group I was greater  $132.8 \pm 8.75$  minutes as compared to group II  $124.3 \pm 9.55$  minutes. (table 1)

Table 1: Characteristics of both groups

Variables	Group I	Group II
Mean age (years)	$50.1 \pm 3.14$	$49.1 \pm 3.14$
Mean BMI (kg/m <sup>2</sup> )	$24.7 \pm 6.33$	$23.7 \pm 6.33$
ASA Class		
II	18 (33.97%)	17 (32.1%)
III	35 (66.03%)	36 (67.9%)
Mean Operative time (min)	$132.8 \pm 8.75$	$124.3 \pm 9.55$

Mean pain score in group I was lower  $40.6 \pm 5.21$  as compared to group II  $65.3 \pm 4.31$ . Mean VAS time of coughing was greater in group II of  $76.7 \pm 1.44$  than that of group I  $66.2 \pm 7.37$  cm-h. (table 2)

Table 2: Post-treatment comparison of treatment among enrolled cases

VAS score	Group I	Group II
Pain (cm-h)	$40.6 \pm 5.21$	$65.3 \pm 4.31$
Cough (cm-h)	$66.2 \pm 7.37$	$76.7 \pm 1.44$

Analgesic usage was significantly reduced in group I, and the incidence of nausea and vomiting was significantly reduced, with no change in the rate of hypotension between the two groups. (table 3)

Table 3: Comparison of adverse outcomes among both groups

Adverse Outcomes	Group I	Group II
Nausea		
Yes	4 (7.5%)	7 (13.2%)
No	49 (92.5%)	46 (86.8%)
Vomiting		
Yes	3 (5.7%)	5 (9.4%)
No	50 (94.3%)	48 (90.6%)

## DISCUSSION

Postoperative analgesia in the thoracic area may be provided by many regional anaesthetic methods, including TEA, TPVB, local wound infiltration, and ultrasound-guided fascial plane blocks. Acute post-surgical pain may be managed with these strategies, but they can also help avoid persistent pain. [16] L.A. injection into a fascial plane may be either superficial or deep into the serratus anterior muscle in the basic SAPB procedure. [17] SAPB may be conducted anywhere between the second and seventh ribs that is bordered by the anterior axillary and posterior axillary lines. In both the superficial and deep SAPB, intercostal nerves are largely targeted. The precise location of the injection and the amount of the injectate has a major role in determining which nerves are affected. [18]

In current study 103 patients of both genders with ages 18-65 years undergoing for open lung resection were presented. We found majority of the patients 66 (62.3%) were males and 40 (37.7%) cases were females with mean age  $50.2 \pm 4.42$  years. Mean body mass index of the cases were  $24.7 \pm 6.33$  kg/m<sup>2</sup>. In both groups majority of the patients 35 (66.03%) and 36 (67.9%) had ASA class III. Results of our study were comparable to the previous researches. [19,20] Mean operative time in group I was greater  $132.8 \pm 8.75$  minutes as compared to group II  $124.3 \pm 9.55$  minutes. [21]

Mean pain score in group I was lower  $40.6 \pm 5.21$  as compared to group II  $65.3 \pm 4.31$ . Mean VAS time of coughing was greater in group II of  $76.7 \pm 1.44$  than that of group I  $66.2 \pm 7.37$  cm-h. There was only a 1.0 cm difference between the two groups' mean VAS scores on coughing that was considered clinically significant, hence the differences in mean VAS scores in our trial were not significant. SAPB was more helpful when used as a whole for both rest pain and cough discomfort. [22] One injection of the serratus plane or thoracic paravertebral block (PVB) was shown to reduce postoperative opioid consumption and pain levels in individuals undergoing thoracoscopic surgery. The serratus plane block is exactly as effective as a paravertebral block in the thorax for postoperative pain management. When it comes to the pain felt when resting or coughing, however, the researchers did not categorise it in their studies. [23] Postoperative acute pain, additional analgesia, nausea and vomiting after surgery and pain assessment at rest as well as while coughing are all similar to the effects of SAPB and PVB. [24] For postoperative 24-hour NRS assessments of rest pain, coughing discomfort, and movement pain, continuous SAPB outperformed continuous PVB, according to Hanley et al. [25].

Analgesic usage was significantly reduced in group I, and the incidence of nausea and vomiting was significantly reduced, with no change in the rate of hypotension between the two groups. [26]

## CONCLUSION

In this trial, we found that continuous SAPB was more effective than TEA in reducing postoperative pain in patients following open lung resection for cancer, and complications were reduced in the SAPB group.

## REFERENCES

- 1 Koehler RP, Keenan RJ. Management of postthoracotomy pain: Acute and chronic. *Thorac Surg Clin.* 2006;16:287-97.
- 2 Humble SR, Dalton AJ, Li L. A systematic review of therapeutic interventions to reduce acute and chronic post-surgical pain after

- amputation, thoracotomy or mastectomy. *Eur J Pain*. 2015;19:451–65.
- 3 Doan LV, Augustus J, Androphy R, Schechter D, Gharibo C. Mitigating the impact of acute and chronic post-thoracotomy pain. *J Cardiothorac Vasc Anesth*. 2014;28:1048–56.
  - 4 Okmen K, Okmen BM, Uysal S. Serratus anterior plane (SAP) block used for thoracotomy analgesia: A case report. *Korean J Pain*. 2016;29:189–92.
  - 5 Kiss G, Castillo M. Non-intubated anesthesia in thoracic surgery-technical issues. *Ann Transl Med*. 2015;3:109.
  - 6 Yeung JH, Gates S, Naidu BV, Wilson MJ, Gao Smith F. Paravertebral block versus thoracic epidural for patients undergoing thoracotomy. *Cochrane Database Syst Rev*. 2016;2:CD009121.
  - 7 Blanco R, Parras T, McDonnell JG, Prats-Galino A. Serratus plane block: A novel ultrasound-guided thoracic wall nerve block. *Anaesthesia*. 2013;68:1107–13
  - 8 Gottschalk A, Cohen SP, Yang S, Ochroch EA. Preventing and treating pain after thoracic surgery. *Anesthesiology*. 2006;104(3):594–600.
  - 9 Ding W, Chen Y, Li D, et al. Investigation of single-dose thoracic paravertebral analgesia for postoperative pain control after thoracoscopic lobectomy - a randomized controlled trial. *Int J Surg*. 2018;57:8–14.
  - 10 Jin J, Min S, Chen Q, Zhang D. Patient-controlled intravenous analgesia with tramadol and lornoxicam after thoracotomy: a comparison with patient-controlled epidural analgesia. *Medicine (Baltimore)*. 2019;98(7):e14538.
  - 11 Chou R, Gordon DB, de Leon-casasola OA, et al. Management of postoperative pain: a clinical practice guideline from the American Pain Society, the American Society of Regional Anesthesia and Pain Medicine, and the American Society of Anesthesiologists' Committee on Regional Anesthesia, Executive Committee, and Administrative Council. *J Pain*. 2016;17(2):131–157.
  - 12 Vorobeichik L, Brull R, Bowry R, Laffey JG, Abdallah FW. Should continuous rather than single-injection interscalene block be routinely offered for major shoulder surgery? A meta-analysis of the analgesic and side-effects profiles. *Br J Anaesth*. 2018;120(4):679–692.
  - 13 Mehta Y, Arora D, Sharma KK, Mishra Y, Wasir H, Trehan N. Comparison of continuous thoracic epidural and paravertebral block for postoperative analgesia after robotic-assisted coronary artery bypass surgery. *Ann Card Anaesth*. 2008;11(2):91–96.
  - 14 Narouze S, Benzon HT, Provenzano D, et al. *Interventional spine and pain procedures in patients on antiplatelet and anticoagulant medications (Second Edition): guidelines from the American Society of Regional Anesthesia and Pain Medicine, the European Society of Regional Anaesthesia and Pain Therapy, the American Academy of Pain Medicine, the International Neuromodulation Society, the North American Neuromodulation Society, and the World Institute of Pain*. *Reg Anesth Pain Med*. 2018;43(3):225–262
  - 15 Blanco R, Parras T, McDonnell JG, Prats-Galino A. Serratus plane block: a novel ultrasound-guided thoracic wall nerve block. *Anaesthesia*. 2013;68(11):1107–1113
  - 16 Garg R (2017) Regional anaesthesia in breast cancer: benefits beyond pain. *Indian J Anaesth* 61(5):369–372
  - 17 Mayes J, Davison E, Panahi P, Patten D, Eljelani F, Womack J, Varma M (2016) An anatomical evaluation of the serratus anterior plane block. *Anaesthesia* 71(9): 1064–1069.
  - 18 Durant E, Dixon B, Luftig J et al (2017) Ultrasound-guided serratus plane block for E.D. rib fracture pain control. *Am J Emerg Med* 35(1):197.e3–197.e6
  - 19 Yang X, Gu H, Hu J, Wang S, Wei X, Shu S, Zhou W, Tao C, Wang D, Chai X. Operation, Effectiveness, and Limitations of Continuous Serratus Anterior Plane Blocks for Thoracoscopic Surgery in Adults. *J Pain Res*. 2020;13:2401-2410
  - 20 Savelloni J, Gunter H, Lee KC, et al. Risk of respiratory depression with opioids and concomitant gabapentinoids. *J Pain Res*. 2017;10:2635–2641.
  - 21 Mamdouh Mahmoud Mostafa, Ahmed Hussein Bakeer, Reham Mohamed Gamal. Ultrasound-Guided Serratus Plane Block versus Thoracic Epidural Analgesia for Acute Post Thoracotomy Pain: A Prospective Randomized Controlled Study. 2021; 25(6): 733-740
  - 22 Abdallah FW, Cil T, MacLean D, et al. Too deep or not too deep?: a propensity-matched comparison of the analgesic effects of a superficial versus deep serratus fascial plane block for ambulatory breast cancer surgery. *Reg Anesth Pain Med*. 2018;43(5):480–487.
  - 23 Wang L, Wang Y, Zhang X, et al. Serratus anterior plane block or thoracic paravertebral block for postoperative pain treatment after uniportal video-assisted thoracoscopic surgery: a retrospective propensity-matched study. *J Pain Res*. 2019;12:2231–2238.
  - 24 Qiu Y, Wu J, Huang Q, et al. Acute pain after serratus anterior plane or thoracic paravertebral blocks for video-assisted thoracoscopic surgery: a randomised trial. *Eur J Anaesthesiol*. 2020.
  - 25 Hanley C, Wall T, Bukowska I, et al. Ultrasound-guided continuous deep serratus anterior plane block versus continuous thoracic paravertebral block for perioperative analgesia in videoscopic-assisted thoracic surgery. *Eur J Pain*. 2020;24(4):828–838.
  - 26 Mostafa et al. Serratus anterior plane block for cardiothoracic surgeries: a meta-analysis of randomized trials. *Ain-Shams Journal of Anesthesiology* (2021) 13:77