

A Study of Specific Dermatoses and Skin Disease Affected by Pregnancy

SAMINA NAZ¹, SEEMAB KHAN², MONIKA³, SUGHRA ABBASI⁴, YASMEEN⁵, ROMASA MUZAFFAR ALI JOYO⁶

¹Senior Consultant, Obstetrics and Gynecology, Chiniot Mother and Child Hospital, Nazimabad Karachi

²Classified Skin Specialist, PNS Shifa Karachi/ Assistant Professor Dermatology, Bahria University Medical and Dental College (BUMDC), Karachi

³Woman Medical Officer, Population Welfare Department, Larkana

⁴Associate Professor, Obstetrics and Gynecology, Karachi Institute of Medical Sciences, Karachi

⁵Assistant Professor, Obstetrics and Gynecology, Baqai Medical University, Karachi

⁶Women Medical Officer, Ministry of Health, UAE

Corresponding author: Samina Naz, Email: dr.saminanaz@yahoo.com, Cell: +92 300 2538747

ABSTRACT

Background and Aim: Pregnancy associated skin diseases or changes can be physiological (hormonal), skin pre-existing disease, and development of dermatoses with new pregnancy. The specific skin dermatoses related to pregnancy involve eruption of pruritic skin in poorly defined heterogeneous group. The present study aimed to evaluate the specific dermatoses and skin disease affected by pregnancy.

Methodology: This cross-sectional study was carried out on 226 pregnant women in the Department of Dermatology and Obstetrics and Gynecology of Dow University Hospital, Karachi from June 2021 to November 2021. All the patients were investigated for pregnancy associated cutaneous changes. The presence of any concomitant dermatoses that developed during pregnancy was investigated. Detailed clinical examination was performed on pregnant women with specific dermatoses of pregnancy regarding pattern, distribution, and morphology of lesions. All the pregnant women undergone through routinely blood investigation.

Results: Of the total 226 pregnant women, the incidence of specific dermatosis during pregnancy was 27 (11.95%). Prurigo of pregnancy (5.8%) was the prevalent specific dermatosis of pregnancy. The incidence of intrahepatic cholestasis of pregnancy (ICP), pruritic urticarial papules and plaques of pregnancy (PUPP), and pruritic folliculitis of pregnancy (PFP) was 0.41%, 3.9%, and 0.17% respectively. All these skin diseases were caused by pregnancy in 11.95% of females.

Conclusion: The present study found that Prurigo of pregnancy was the prevalent dermatosis of pregnancy that occurred in the multigravida second trimester. The rare dermatosis with no primary lesion was intrahepatic cholestasis of pregnancy. The course of pregnancy-associated disease changes, in turn, causes exacerbation like psoriasis, vitiligo, and dermatosis.

Keywords: Specific Dermatoses, Skin disease, Pregnancy

INTRODUCTION

Many physiological changes in the skin are related to pregnancy caused by hormonal effects. These physiological changes involve vascular changes, melisma, gravidarum, as well as nail and hair changes. Immunological changes during pregnancy might worsen or improve the pre-existing skin conditions. Skin infections such as candidiasis are more severe and common due to the suppression of cell-mediated immunity during pregnancy. Various skin dermatosis like inflammatory diseases is only seen during pregnancy. Though the majority of these skin dermatoses are benign and resolve in the postpartum period, a few can endanger the fetal life and necessitate antenatal monitoring [1, 2]. Maternal extreme distress during pregnancy is caused by pruritic skin disorders especially distinct and heterogenous dermatosis during pregnancy. Polymorphic eruption of pregnancy (PEP), pemphigoid gestationis (PG), and intrahepatic cholestasis of pregnancy (ICP) are all symptoms of atopic eruption of pregnancy (AEP).

Certain infections such as herpes, candidiasis, and other viral infection, systemic sclerosis-associated metabolism diseases like connective tissue disorder and porphyria cutanea tarda, and immunological diseases such as lichen planus, psoriasis Vulgaris, systemic lupus erythematosus, and pemphigus Vulgaris can vary during pregnancy. Also, during pregnancy certain inflammatory skin dermatosis could be seen. Antenatal monitoring is required and can endanger neonate life in special cases as most of them resolve on their own and are harmless. Physiological changes in the skin could be differentiated during pregnancy in order to avoid any unrequired harmful medical intervention [3-5]. The diagnosis and management of pregnancy-related disorders could be difficult due to the lack of diagnostic tests and variance in clinical presentation. To support maternal care and decrease fetal potential risk, it is essential to detect any disorder as early as possible [6, 7]. The present study aimed to evaluate the specific dermatoses and skin diseases affected by pregnancy.

METHODOLOGY

This cross-sectional study was carried out on 226 pregnant women in the Department of Dermatology and Obstetrics and Gynecology

of Dow University Hospital, Karachi from June 2021 to November 2021 from January 2020 to December 2020. All the patients were investigated for pregnancy associated cutaneous changes. The presence of any concomitant dermatoses that developed during pregnancy was investigated. Detailed clinical examination was performed on pregnant women with specific dermatoses of pregnancy regarding pattern, distribution, and morphology of lesions. All the pregnant women undergone through routinely blood investigation. A detailed history was elicited and recorded, which included skin-related chief complaints, itching, demographic details, jaundice, skin lesions, family history, vaginal discharge, skin associated disorders, and exacerbating factors. In all cases, a thorough skin examination was performed to investigate all skin-associated physiological changes and their appendages. Skin lesions sites, morphology, and distribution were investigated in cases where pregnancy-associated dermatosis was present. A relevant examination was performed. Any evidence of exacerbation or remission of any pre-existing skin disease was recorded. If necessary, appropriate investigations were conducted to confirm the diagnosis. The presence of any concomitant dermatoses that developed during pregnancy was investigated. SPSS version 23 was used for data analysis.

RESULTS

Of the total 226 pregnant women, the incidence of specific dermatosis during pregnancy was 27 (11.95%). Prurigo of pregnancy (5.8%) was the prevalent specific dermatosis of pregnancy. The incidence of intrahepatic cholestasis of pregnancy (ICP), pruritic urticarial papules and plaques of pregnancy (PUPP), and pruritic folliculitis of pregnancy (PFP) was 0.41%, 3.9%, and 0.17% respectively. All these skin diseases were caused by pregnancy in 11.95% of females. Pregnant females with specific dermatoses are distributed according to gravida as shown in Figure-1. Distribution of pregnant females having onset of specific dermatoses of pregnancy with respect to trimester of pregnancy are shown in Figure-2. Pregnant women with various skin diseases affected by pregnancy are distributed as shown in Table-1.

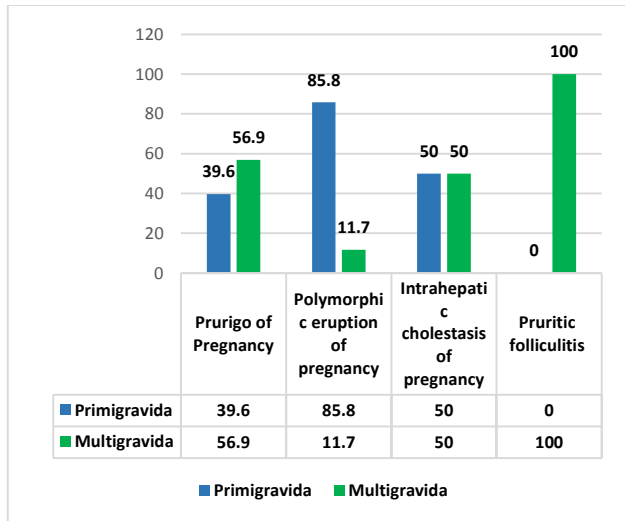


Figure-1: Pregnant females with specific dermatoses are distributed according to gravida

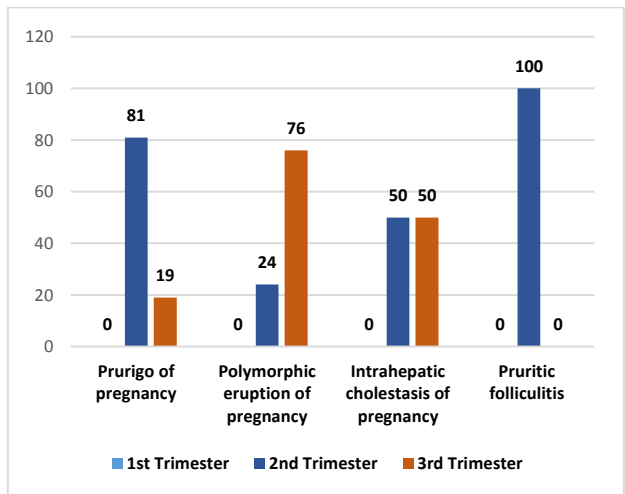


Figure-2: Distribution of pregnant females having onset of specific dermatoses of pregnancy with respect to trimester of pregnancy

Table-1: Pregnant women with various skin diseases affected by pregnancy are distributed.

Diseases	Frequency (Cases)	Exacerbated
Photomorph light eruption	3	2
Eczema	2	1
Acne vulgaris	14	7
Psoriasis	2	1
Vitiligo	1	1
Darier disease	1	1
Atopic dermatitis	2	2
Hypertrophic scar	1	-
Keloid	1	-
Total	27	-

DISCUSSION

The present study found that Prurigo of pregnancy was the prevalent dermatosis of pregnancy that occurred in the multigravida second trimester. The rare dermatosis with no primary lesion was intrahepatic cholestasis of pregnancy. The course of pregnancy-associated disease changes, in turn, causes exacerbation like psoriasis, vitiligo, and dermatosis. Cutaneous changes during pregnancy may vary from skin physiological changes to skin diseases that erupt during the postpartum period. The skin might be affected by vascular,

immunological, endocrinologic, and metabolic changes [8]. Almost all pregnant women will experience physiological cutaneous changes. Pigmentation changes such as areola, melasma, generalized hyperpigmentation, and linea nigra, changes in nail and hair, and vascular changes like varicosities, palmar erythema, spider angiomas, and endocrine function are all skin associated physiological changes during pregnancy [9].

In a previous study by Schaefer et al, pigmentary changes were seen in up to 90% of pregnant women [10]. A study conducted by Chouk et al, [11] found the incidence of secondary areola and linea nigra in 78% and 91% respectively, these results resembled our study findings. Hyperpigmentation is caused by high levels of MSH, oestrogen, or progesterone in the blood. Estrogen stimulates melanocytes to produce more melanin, and the effect of oestrogen is augmented by progesterone, which is produced by melanin deposition in epidermal and dermal macrophages.

The neonate attachment to the mother is allowed by variance in the maternal immune system during pregnancy. Altered Cytokine production results in a preference for Th2 cytokines such as IL-4, IL-5, IL-10, IL-13, which promotes fetal survival. Th2 cytokine profile could be changed by the hormonal changes during pregnancy [12]. Pregnancy dermatosis was classified by Feray et al [13] in the present study. Specific dermatosis could be 4.9, 18, and 5 in Nguyen et al. [14], Detrixhe et al. [15], and Robert et al. [16] respectively.

Exacerbations occurred in 0.83% of cases of eczema, 1.9% of cases of psoriasis, 1.1% of cases of protein-losing enteropathy exacerbation of SLE, 0.16% of cases of ichthyosis vulgaris, and 0.4% of cases of neurofibromatosis, according to Chouk et al [11]. In 0.16% of cases, pemphigus and vitiligo appeared for the first time. Diseases in which humoral immunity plays a major role, such as atopic dermatitis, are exacerbated, whereas diseases in which cell-mediated immunity plays a role, such as psoriasis vulgaris, may show regression. Specific dermatosis of skin during pregnancy could be the eruption of pruritic skin in heterogeneous group. Pregnancy dermatosis was initially classified in four categories; 1) pemphigoid gestationis (PG), 2) polymorphic eruption of pregnancy (PEP), 3) prurigo of pregnancy (PP); and 4) pruritic folliculitis of pregnancy (PFP) (PF).

Typically, soles, faces, and palms like the peri-umbilical regions are freed. However, polycyclic lesions, targetoids, Vesicles, eczematous, and purpura are sporadically seen. The prime cause is still to be determined. In obese and multiple gestations women, increased prevalence of PUPPP has been associated with skin distension or cutaneous changes due to the fetal cell circulation present in maternal invade skin during pregnancy [17, 18]. Another theory proposed that skin eruption caused by antigenic molecules conversion from non-antigenic molecules could result in the damaged connective tissue of the skin [19, 20]. The disease is self-limiting, and lesions resolve shortly after birth or in the postpartum period. The prognosis for both the foetus and the mother is excellent [21]. The majority of patients find relief by using a topical calamine, moderately potent topical corticosteroid, and systemic antihistamines.

CONCLUSION

The present study found that Prurigo of pregnancy was the prevalent dermatosis of pregnancy that occurred in the multigravida second trimester. The rare dermatosis with no primary lesion was intrahepatic cholestasis of pregnancy. The course of pregnancy-associated disease changes, in turn, causes exacerbation like psoriasis, vitiligo, and dermatosis.

REFERENCES

1. Alajeel AI. Comprehensive Study For Skin Diseases In Primigravida And Multigravid Pregnant Women. Systematic Reviews in Pharmacy. 2021;12(1):1384-7.
2. Nasca MR, Giuffrida G, Micali G. The influence of pregnancy on the clinical evolution and prognosis of pre-existing inflammatory and

- autoimmune skin disorders and their management. *Dermatology*. 2021;237(5):771-85.
3. Abdelhafez MM, Ahmed KA, Mohd Daud MN, Jeffree MS, Kadir F, Baharuddin DM, Than WW, Hayatti F, Tay KX, Eldiastey AM. Impetigo herpeticiformis: A rare pregnancy-specific dermatosis. *Obstetric Medicine*. 2022 Jan 28;1753495X221074610.
 4. Hills F. Connective tissue and dermatological conditions in pregnancy. *Obstetrics, Gynaecology & Reproductive Medicine*. 2021 Jun 1;31(6):162-9.
 5. Porter ML, Lockwood SJ, Kimball AB. Update on biologic safety for patients with psoriasis during pregnancy. *Int J Womens Dermatol*. 2017 Feb;3(1):21-5
 6. Yang CS, Teeple M, Muglia J, Robinson-Bostom L. Inflammatory and glandular skin disease in pregnancy. *Clin Dermatol*. 2016 May-Jun;34(3):335-43.
 7. Namazi N, Dadkhahfar S. Impetigo herpeticiformis: review of pathogenesis, complication, and treatment. *Dermatol Res Pract*. 2018 Apr;2018:5801280.
 8. Roth MM, Cristodor P, Kroumpouzou G. Prurigo, pruritic folliculitis, and atopic eruption of pregnancy: facts and controversies. *Clin Dermatol*. 2016 May-Jun;34(3):392-400.
 9. Hamann CR, Egeberg A, Wollenberg A, Gislason G, Skov L, Thyssen JP. Pregnancy complications, treatment characteristics and birth outcomes in women with atopic dermatitis in Denmark. *J Eur Acad Dermatol Venereol*. 2019 Mar;33(3):577-87.
 10. Schaefer P. Acute and chronic urticaria: evaluation and treatment. *Am Fam Physician*. 2017 Jun;95(11):717-24.
 11. Chouk C, Litaïem N. Pruritic urticarial papules and plaques of pregnancy (PUPPP). StatPearls. Treasure Island (FL): StatPearls Publishing; 2020.
 12. Kukkamalla RM, Bayless P. Pemphigoid gestationis. *Clin Pract Cases Emerg Med*. 2019 Jan;3(1):79-80.
 13. Feray S, Fain O, Kayem G, Sabourdin N, Constant I, Rigouzzo A. Repeated attacks of type III hereditary angioedema with factor XII mutation during pregnancy. *Int J Obstet Anesth*. 2018 Nov;36:114-8.
 14. Nguyen T, Razzaque Ahmed A. Autoimmune progesterone dermatitis: update and insights. *Autoimmun Rev*. 2016 Feb;15(2):191-7.
 15. Detrixhe A, Nikkels AF, Dezfoulian B. Autoimmune progesterone dermatitis. *Arch Gynecol Obstet*. 2017 Nov;296(5):1013-4.
 16. Robert R Müllegger , Nina S Häring , Martin Glatz Skin infections in pregnancy *Clin Dermatol* May-Jun 2016;34(3):368-77.
 17. Florian M.E. Wagenlehner, Prof. Dr. med., Norbert H. Brockmeyer, Prof. Dr. med., Thomas Discher, Dr. med., Klaus Friese, Prof. Dr. med., 4 and Thomas A. Wichelhaus Prof. Dr. med. The Presentation, Diagnosis, and Treatment of Sexually Transmitted Infections *Dtsch Arztebl Int*. 2016 Jan; 113(1-2): 11-22).
 18. Manju M, Hanslata G. A clinical study of skin disorders in pregnancy, *Int J Reprod Contracept Obstet Gynecol*. 2018 Feb;7(2):715-718
 19. Drago F, Ciccarese G, Herzum A, Rebora A, Parodi A. Pityriasis rosea during pregnancy: major and minor alarming signs. *Dermatology*. 2018;234(1-2):31-6.
 20. Chien AL, Qi J, Rainer B, Sachs DL, Helfrich YR. Treatment of acne in pregnancy. *J Am Board Fam Med*. 2016 Mar-Apr;29(2):254-62.
 21. Trivedi MK, Kroumpouzou G, Murase JE. A review of the safety of cosmetic procedures during pregnancy and lactation. *Int J Womens Dermatol*. 2017 Feb;3(1):6-10